

Diffuse sebaceous-gland hyperplasia

Julia Gittler, MD, Lauren Penn, MD, Vitaly Terushkin, MD, Nooshin Brinster, MD

Ronald O. Perelman Department of Dermatology, NYU School of Medicine, NYU Langone Medical Center

Abstract

Diffuse sebaceous-gland hyperplasia is a rare variant of sebaceous-gland hyperplasia that is distinct from the well-known circumscribed type. The term presenile sebaceous hyperplasia has been utilized to describe this entity that is distinguished by specific features, which include confluence of lesions that results in the formation of large plaques on the face, the sparing of periorificial regions, and highly functional glandular hyperplasia that results in excessive sebaceous secretion. We present a 43-year-old woman with monomorphous, skin-colored and yellow, smooth 1- to 3-mm papules, some with central umbilication, that spare the periorificial zones. Histopathologic examination was suggestive of diffuse sebaceous-gland hyperplasia. Differential diagnosis of this condition is broad and includes syndromes that are associated with multiple facial papules and malignant conditions, such as Muire-Torre syndrome and Cowden syndrome. It is important to be aware of this condition in order to consider appropriate treatment options, such as isotretinoin and to avoid unnecessary diagnostic tests.

Case Presentation

PATIENT: 43-year-old woman

DURATION: Twelve years

DISTRIBUTION: Face

HISTORY: A 43-year-old woman presented to Bellevue Dermatology Clinic for the evaluation of an asymptomatic eruption on her face. Six years prior

to this presentation, she had been treated for an acneiform eruption on her cheeks and forehead. At that time, she had presented with comedones and erythematous papules on the central area of the face and terminal hairs on the chin. She was initially treated with doxycycline 100 milligrams twice per day, benzoyl peroxide 5% gel, and tretinoin 0.05% cream for three months without improvement. She later developed erythematous papules that coalesced into plaques on her cheeks, and a diagnosis of pyoderma faciale was made. She was started on an oral contraceptive and subsequently treated with a four-month course of isotretinoin, with a cumulative dose of 7400 milligrams, (patient's weight was 65 kilograms) with appreciable improvement of her eruption.

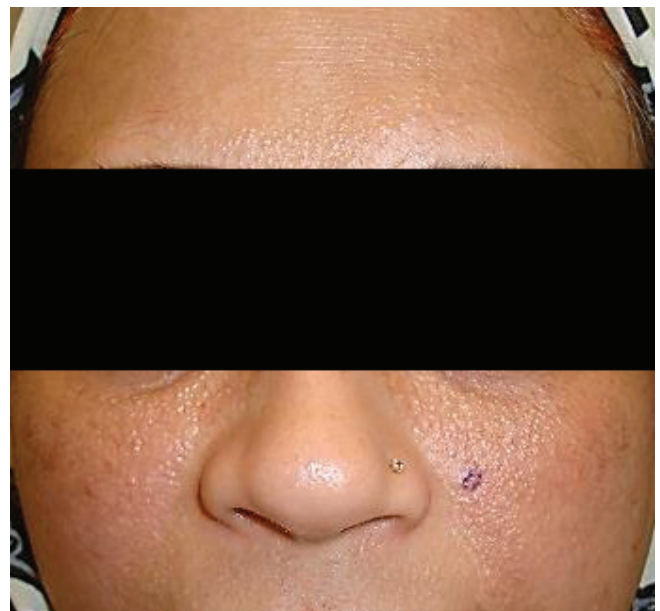

Figure 1. Many skin-colored and yellow, smooth 1-3 mm papules on the face, sparing the periorificial skin zones.

At the time of completion of her course, as documented by findings on physical examination, the patient had hyperpigmentation and hypopigmentation of the face, with no papules. Upon her recent presentation, a punch biopsy was obtained from a peripheral papule on her left temple, which demonstrated a perivascular, lymphohistiocytic infiltrate with melanophages. A second biopsy was recommended and was obtained from a papule on the central area of the cheek.

PHYSICAL EXAMINATION: On the glabella and extending over the eyebrows, temples, nasal root and bridge, and medial aspects of the cheeks were many, skin-colored and yellow, smooth 1-3 mm papules, some with central umbilication. The papules spared the periorificial skin zones. Dermoscopy demonstrated a yellow homogenous color.

LABORATORY DATA: None

HISTOPATHOLOGY: There is an increased number of enlarged sebaceous gland lobules which emanate from follicular infundibula (**Figure 2**).

DIAGNOSIS: Diffuse sebaceous-gland hyperplasia

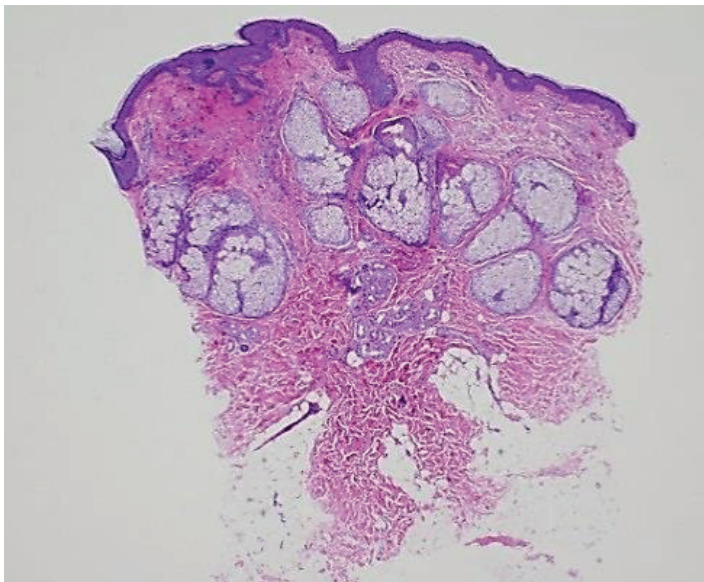


Figure 2. Biopsy showing an increased number of enlarged sebaceous gland lobules emanating from follicular infundibula.

Discussion

Circumscribed sebaceous-gland hyperplasia, which is a common benign facial condition, most frequently occurs in adults of middle age or older. It typically presents on the forehead and central area of the face as single or multiple, soft, yellow papules with central umbilication and telangiectases and increases with ultraviolet B exposure and aging [1]. The pathogenesis of sebaceous-gland hyperplasia involves the changing hormonal environment that is associated with increasing age [2]. Declining androgen levels causes a decrease in sebocyte turnover, which subsequently leads to an increase of sebocytes within the gland and thus hyperplasia. Additional hormonal factors, such as insulin, thyroid stimulating hormone, and hydrocortisone, have been found to increase sebocyte proliferation [3,4].

Diffuse sebaceous-gland hyperplasia is a rare variant of sebaceous-gland hyperplasia that is distinct from the well-known, circumscribed type [1]. In several reports of this diffuse form, the term presenile sebaceous-gland hyperplasia has been utilized in order to characterize the presentation of diffuse sebaceous-gland hyperplasia that has occurred in young adults and may be familial but often is sporadic [1, 5-10]. One of the first reports that characterized this condition described two brothers in early adulthood, who developed diffuse sebaceous-gland hyperplasia on their faces, necks, and upper trunks, which was accompanied by marked seborrhea [8]. The entity was distinguished by specific features, which included confluence of lesions that resulted in the formation of large plaques on the face, sparing of the periorificial regions, highly functional glandular hyperplasia that resulted in excessive sebaceous secretion, and absence of acne [8]. Another family with premature sebaceous-gland hyperplasia had five affected generations, with numerous 1-2 mm, yellow, umbilicated papules on the nose, cheeks, forehead, chin, and upper chest, with sparing of the periorbital and perioral areas. Some lesions were described as confluent and forming plaques [10]. A later report described a 43-year-old woman, who developed sebaceous-gland hyperplasia in a diffuse pattern of aggregated, numerous, yellow-to-white papules that involved her entire face, neck, and upper chest. Her eruption did not improve with

the use of topical tretinoin but did improve with the use of oral isotretinoin [1]. Diffuse sebaceous-hyperplasia also has also been reported to occur in context of immunosuppression, as in a 39-year-old patient, who developed this condition while being treated with prednisone and azathioprine [6], and in multiple cases that have been reported in the context of cyclosporine treatment and even in cases that occurred many years after initiation of the immunosuppressant [11].

Histopathological examination of different types of sebaceous-gland hyperplasia, which includes both circumscribed and diffuse forms, shows enlarged sebaceous lobules with normal sebocyte maturation and some foci that demonstrate an increased number of immature sebocytes [1]. Differential diagnosis of diffuse sebaceous gland hyperplasia is broad and includes comedones, rosacea, sebaceous adenomas, trichoepitheliomas, and angiofibromas [9]. One must consider syndromes that are associated with multiple facial papules and malignant conditions, such as Muir-Torre syndrome and Cowden syndrome.

Sebaceous-gland hyperplasia is a common cosmetic concern, but is difficult to treat as the entire sebaceous gland needs to be destroyed to prevent recurrence. Traditional methods of treatment include cryosurgery, electrodesiccation, curettage, shave excision, and topical trichloroacetic acid [4,9]. However, these treatments are associated with a risk of skin dyspigmentation and scars, and depending on the extent of lesions, it may be necessary to initiate systemic treatment, such as isotretinoin. Isotretinoin has been demonstrated to reduce the size of the sebaceous gland, diminish proliferation of basal sebocytes, suppress the production of sebum, and inhibit the differentiation of sebocytes in vivo [9]. However, isotretinoin for treatment of sebaceous-gland hyperplasia has been associated with a high relapse rate [9]. Recent reports have examined photodynamic therapy and laser treatment of sebaceous-gland hyperplasia and show good outcomes, in particular with the use of a 1720-nanometer diode laser that selectively targets sebaceous-gland hyperplasia with minimal side effects [4]. Larger prospective studies with longer follow-up are required.

References

1. Schirren CG, et al. Diffuse sebaceous gland hyperplasia: a case report and an immunohistochemical study with cytokeratins. *Am J Dermatopathol* 1996; 18:296
2. Rosenfield RL, et al. Peroxisome proliferator-activated receptors and skin development. *Horm Res* 2000; 54: 269
3. Zouboulis CC, et al. The human sebocyte culture model provides new insights into development and management of seborrhea and acne. *Dermatology* 1998; 196: 21
4. Simmons BJ, et al. Light and laser therapies for the treatment of sebaceous gland hyperplasia a review of the literature. *J Eur Acad Dermatol Venereol* 2015; 29: 2080
5. Bhawan J, et al. Premature sebaceous gland hyperplasia [Letter]. *J Am Acad Dermatol* 1983; 8: 136
6. Burton CS, et al. Premature sebaceous gland hyperplasia: successful treatment with isotretinoin. *J Am Acad Dermatol* 1985; 12: 182
7. De Villez RL, et al. Premature sebaceous gland hyperplasia. *J Am Acad Dermatol* 1982; 6: 933
8. Dupre A, et al. Functional familial sebaceous hyperplasia of the face: reverse of the Cunliffe acne-free naevus? Its inclusion among naevoid sebaceous receptor disease. *Clin Exp Dermatol* 1980; 5: 203
9. Grimalt, et al. Premature familial sebaceous hyperplasia: successful response to oral isotretinoin in three patients. *J Am Acad Dermatol* 1997; 37: 996
10. Boonchai W, et al. Familial presenile sebaceous gland hyperplasia. *J Am Acad Dermatol* 1997; 36: 120
11. Engel F, et al. Diffuse sebaceous hyperplasia of the face induced by cyclosporine. *Ann Dermatol Venereol* 2005; 132: 342