

Anti-laminin 332 antibodies in graft-versus-host disease-associated bullous pemphigoid after allogeneic peripheral blood stem cell transplantation

Yasutoshi Hida¹ MD PhD, Riho Kageji¹ MD, Hirofumi Bekku² MD, Norito Ishii³ MD PhD

Affiliations: ¹Division of Dermatology, Tokushima Red Cross Hospital, Komatsushima, Tokushima, Japan, ²Division of Hematology, Tokushima Red Cross Hospital, Komatsushima, Tokushima, Japan, ³Department of Dermatology, Kurume University of School of Medicine, Kurume, Fukuoka, Japan

Corresponding Author: Yasutoshi Hida, Division of Dermatology, Tokushima Red Cross Hospital, 773-8502, Tokushima Komatsushima Komatsushima-Cho Irinoguchi 103, Japan, Tel: 885-32-2555, Fax: 885-32-0719, Email: yasutoshi@ae.auone-net.jp

Abstract

We report a 48-year-old woman with bullous pemphigoid (BP) with antibodies against the β 3 subunit of laminin 332 after the development of graft-versus-host disease (GVHD). She was diagnosed with recurrent acute lymphoblastic leukemia at 40 years of age and underwent two rounds of allogeneic peripheral blood stem cell transplantations (PBST). Two and a half years after the second PBST, multiple tense blisters appeared on her face, hands, and lower legs. The diagnosis of BP was based on hematoxylin eosin and immunofluorescence staining and immunoblotting analyses. A combination regimen of topical corticosteroids (clobetasol propionate) and tetracycline/niacinamide was administered. Complete clinical resolution was achieved after four weeks of therapy without the use of immunosuppressive drugs. To maintain the graft-versus-tumor effect, topical corticosteroids and immunomodulatory drugs are preferred for BP after hematopoietic stem cell transplantation considering the risk of recurrence of hematologic malignancies. To date, there have been no reports of successful treatment of GVHD-associated BP without immunosuppressive drugs. Chronic GVHD is characterized by the production of autoantibodies. Furthermore, this autoimmune subepidermal blistering disease, BP, may be a manifestation of chronic GVHD. However, the precise mechanism of autoantibody production in chronic GVHD is not yet fully elucidated.

Keywords: blood, bullous pemphigoid, graft-versus-host, laminin 332, niacinamide, peripheral, stem cell, tetracycline, transplantation, tumor

Introduction

Hematopoietic stem cell transplantation (HSCT) is a critical and accepted therapy for a variety of hematopoietic malignant diseases, such as leukemia, myelodysplastic syndrome, and malignant lymphoma. However, several issues remain unresolved. One of them is chronic graft-versus-host disease (GVHD), which is characterized by fibrosis of multiple organs and production of various autoantibodies. Bullous pemphigoid (BP) is an autoimmune subepidermal blistering disease in which autoantibodies against antigens of the basement membrane zone (BMZ) are formed. Herein, we describe a patient with BP with antibodies against the β 3 subunit of laminin 332, associated with allogeneic peripheral blood stem cell transplantation (PBST)-induced GVHD. Laminin 332 is synthesized and secreted by keratinocytes and fibroblasts and is integrated into the BMZ as anchoring filaments [1]. Laminin 332 plays an important role in connecting the lamina lucida and lamina densa [1]. We believe that BP is a manifestation of chronic GVHD. We tried a combination regimen of high-potency topical corticosteroids and tetracycline/niacinamide. A complete clinical response was achieved within four

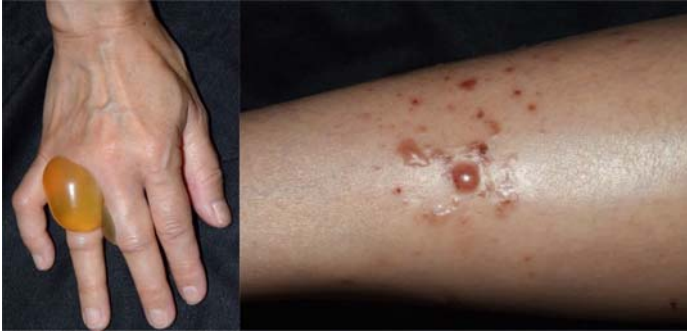

Figure 1. Tense bullae on the hands and lower legs.

weeks of treatment initiation without the use of immunosuppressive drugs.

Case Synopsis

A 48-year-old woman presented with blisters on her hands and lower legs. The patient had undergone chemotherapy and two rounds of PBST for recurrent acute lymphoblastic leukemia (Philadelphia chromosome +). Tacrolimus was administered as prophylaxis for GVHD. Sixty-two days after the second round of PBST, the patient developed grade II GVHD of the skin, which was treated with topical corticosteroids and phototherapy (narrow-band ultraviolet B). Two weeks later, the patient developed severe diarrhea. Gastrointestinal GVHD was diagnosed based on endoscopic and histological findings. We increased the tacrolimus dose, following which the skin and gastrointestinal symptoms improved. Six months after the second round of PBST, tacrolimus was discontinued and the graft-versus-leukemia effect was expected. Two and

a half years after the second round of PBST, multiple tense blisters appeared on her face, hands, and lower legs (**Figure 1**). No blisters were observed in the oral cavity. An endoscopic examination revealed no other blisters in the esophageal mucosa. A blistering lesion on the leg was biopsied and histopathological examination revealed a subepidermal blister and eosinophilic infiltration (**Figure 2A**). Although IgA and IgM deposits were not detected in the BMZ, direct immunofluorescence (IF) showed linear deposition of IgG and C3 in the BMZ (**Figure 2B**). Indirect IF for IgG was also positive at the BMZ (titer, 1:10). Indirect IF using 1M sodium chloride split skin showed linear IgG deposition on the dermal side (titer, 1:40). Immunoblotting of purified human laminin 332 revealed that IgG antibodies reacted with the 140-kDa, $\beta 3$ subunit of laminin 332 (**Figure 2C**), leading to the diagnosis of BP with antibodies against laminin 332. On chimerism analysis, complete chimeric peripheral lymphocytes were identified, suggesting that donor-derived B lymphocytes produced the anti-laminin 332 antibodies. To avoid compromising the graft-versus-tumor effect, the patient was started on a combination regimen of topical corticosteroids (clobetasol propionate) and tetracycline (1000mg/day) plus niacinamide (600mg/day). A complete clinical resolution was achieved after four weeks of therapy without the addition of immunosuppressive drugs. Tetracycline and niacinamide were continued with no recurrence.

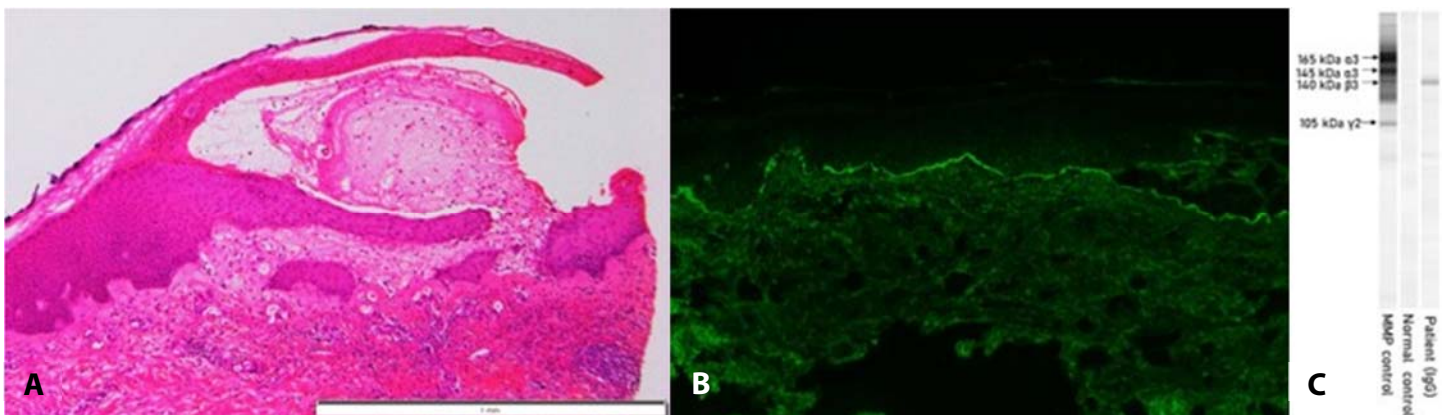


Figure 2. Histopathological examination of biopsy specimen from the lower leg showing the formation of a subepidermal blister. **A)** H&E, 40 \times . **B)** Direct immunofluorescence showing deposition of IgG in the basement membrane zone, 100 \times . **C)** Immunoblot of purified human laminin-332. IgG antibodies in the patient serum (20-fold dilution) reacted against the 140 kDa $\beta 3$ subunit of laminin 332.

Case Discussion

Chronic GVHD often presents with clinical features that resemble those observed in autoimmune diseases such as Sjogren syndrome, scleroderma, and bullous autoimmune dermatoses [2]. Autoantibody formation is a common feature in these patients [2]. Hofmann et al. demonstrated that circulating autoantibodies against BMZ proteins such as collagen VII, BP230, BP180, and laminin 332 are more frequently detected in patients with chronic GVHD (10/42, 24%) than in patients post-HSCT without chronic GVHD (0/18, 0%), [3]. Although the mechanism of autoantibody production in chronic GVHD is not yet fully elucidated, the reduced activity of regulatory T cells (Tregs) appears to play an important role [4]. Muramatsu et al. determined that Tregs dysfunction generates autoantibodies in BP [5]. One possible mechanism for production of autoantibodies against BMZ proteins is the leakage of BMZ antigens into the circulation resulting from acute or chronic cutaneous GVHD. The subsequent abnormal reactivation of B lymphocytes may induce the production of autoantibodies against BMZ proteins due to Treg dysfunction. These findings suggest that chronic GVHD induces BP. Moreover, this patient had completely chimeric peripheral lymphocytes, indicating that the donor B lymphocytes produced the anti-laminin 332 antibodies.

To the best of our knowledge, there have been 20 reports of subepidermal autoimmune blistering diseases (SABD) after HSCT ([Table 1](#)), [6-25], with a male predominance. In most cases, the patients had GVHD, which preceded the onset of SABD. The underlying disease, transplanted stem cells, and interval between HSCT and SABD onset (3-87 months) were not related to the type of SABD. Almost all cases were of a pemphigoid variety, either sBP or mucous membrane pemphigoid. Anti-laminin-332 antibodies, which are extremely rare in pemphigoid disease, were found in six out of the 20 cases. All patients received immunosuppressive therapy, except for one patient who died of rapidly progressing acute myeloblastic leukemia [16]. Most patients had a good prognosis; two patients died due to disease progression and one died due to sepsis.

Chronic GVHD-induced autoimmune diseases require treatments tailored to each disease. Treatment options other than immunosuppressive agents should be considered first. Systemic corticosteroids and other classes of immunosuppressants may diminish the graft-versus-tumor effect in the donor lymphocytes. Kato et al. reported a patient with acute lymphoblastic leukemia, who developed BP after HSCT [21]. The patient had rapid growth of extramedullary masses after systemic corticosteroid administration and developed a leukemic state. Moreover, immunosuppressive drugs may increase the risk of opportunistic infections. Other treatment options for BP are immunomodulatory agents, such as nicotinamide, tetracycline, minocycline, dapsone, plasma exchange, and intravenous immunoglobulins [26]. These agents are believed to have no influence on the graft-versus-tumor effect, and therefore, are preferred for treatment post-HSCT BP, considering the risk of recurrence of hematologic malignancies. We tried a combination regimen of topical corticosteroids (clobetasol propionate) and tetracycline/niacinamide with good results. To date, there have been no reports on the use of combination regimens of topical corticosteroids and immunomodulatory agents for the treatment of post-HSCT GVHD-associated BP.

Bullous lesion mimicking BP have been reported on the sclerotic skin of patients with chronic GVHD with a negative direct IF [27]. Because only the early phase of BP can be managed with immunomodulatory agents, dermatologists should keep in mind that BP can develop in patients with HSCT-induced GVHD. In such patients, immunological examinations, such as direct IF, enzyme-linked immunosorbent assay, and immunoblotting, should be performed.

Conclusion

Bullous pemphigoid may develop in association with HSCT-induced chronic GVHD. Bullous lesions mimicking pemphigoid may appear on the skin of patients with chronic GVHD. Immunological examinations should be performed to distinguish between these two conditions. For the treatment of chronic GVHD-associated BP, topical corticosteroids

and immunomodulatory agents should be considered first to maintain the graft-versus-tumor effect and avoid opportunistic infections.

Potential conflicts of interest

The authors declare no conflicts of interest.

References

1. Shi L, Li X, Qian H. Anti-laminin 332-type mucous membrane pemphigoid. *Biomolecules*. 2022;12:1461. [PMID: 36291670].
2. Sherer Y, Shoenfeld Y. Autoimmune diseases and autoimmune post-bone marrow transplantation. *Bone Marrow Transplant*. 1998;22:873-881. [PMID: 9827815].
3. Hofmann SC, Kopp G, Gall C, et al. Basement membrane antibodies in sera of haematopoietic cell recipients are associated with graft-versus-host disease. *J Eur Acad Dermatol Venereol*. 2010;24:587-594. [PMID: 19906045].
4. Chen X, Vodanovic-Jankovic S, Johnson B, et al. Absence of regulatory T-cell control of Th1 and Th17 cells is responsible for the autoimmune-mediated pathology in chronic graft-versus-host disease. *Blood*. 2007;110:3804-3813. [PMID: 17693581].
5. Muramatsu K, Ujiie H, Kobayashi I, et al. Regulatory T-cell dysfunction induces autoantibodies to bullous pemphigoid antigens in mice and human subjects. *J Allergy Clin Immunol* 2018;142:1818-1830. [PMID: 29704593].
6. Ueda M, Mori T, Shiobara S, et al. Development of bullous pemphigoid after allogeneic bone marrow transformation. *Transplantation* 1986;42:320-322. [PMID: 3529534].
7. Lacour JP, Adrien A, Gratacos N, et al. Bullous pemphigoid following graft-versus-host reaction after bone marrow allograft. *Press Med* 1988;17:1367-1368. [PMID: 2970089].
8. Burger J, Gmür J, Bruckner-Tuderman L. Epidermolysis bullosa acquisita, a rare late complication of allogeneic bone marrow transplantation? *Bone Marrow Transplant* 1992;9:139-141. [PMID: 1571712].
9. Delbaldo C, Rieckhoff-Cantoni L, Helg C, Saurat JH. Bullous pemphigoid associated with acute graft-versus-host disease after allogeneic bone marrow transplantation. *Bone Marrow Transplant* 1992;10:377-379. [PMID: 1422495].
10. Kikuchi A, Kawahara Y, Okamoto S, Ikeda Y, Nishikawa T. Tense blisters after bone marrow transplantation. *Arch Dermatol* 1999;135:81-86. [PMID: 9935388].
11. Szabolcs P, Reese M, Yancey KB, Hall RP, Kurtzberg J. Combination treatment of bullous pemphigoid with anti-CD20 and anti-CD25 antibodies in a patient with chronic graft-versus-host disease. *Bone Marrow Transplant* 2002;30:327-329. [PMID: 12209356].
12. Nagai H, Shirakata Y, Midorikawa K, Murakami S, Hashimoto K. A case of bullous pemphigoid associated with graft versus host disease. *Nishinihifu* 2004;66:269-273. [DOI 10.2336/nishinihonhifu.66.269].
13. Kawasuji A, Matsushita Y, Oishi N, Kaji T, Takata M. Bullous pemphigoid after allogeneic bone marrow transplantation. *Rinsho Derma* 2004. 46: 1823-1826. https://www.kanehara-shuppan.co.jp/magazines/search_list.html?kubun=07637.
14. Aisa Y, Mori T, Nakazato T, et al. Cicatricial pemphigoid of the oropharynx after allogeneic stem cell transplantation for relapsed follicular lymphoma. *Int J Hematol* 2005;82:266-269. [PMID: 16207603].
15. Izumi R, Fujimoto M, Yazawa N, et al. Bullous pemphigoid positive for anti-BP180 and anti-laminin 5 antibodies in a patient with graft-versus-host disease. *J Am Acad Dermatol* 2007;56:S94-97. [PMID: 17434049].
16. Takahara M, Tsuji G, Ishii N, et al. Mucous membrane pemphigoid with antibodies to the β -3 subunit of laminin 332 in a patient with acute myeloblastic leukemia and graft-versus-host disease. *Dermatology* 2009;219:361-364. [PMID: 19797892].
17. Mahmood S, Lim ZY, Benton E, et al. Mucous membrane pemphigoid following reduced intensity conditioning allogeneic hematopoietic SCT for biphenotypic leukemia. *Bone Marrow Transplant* 2010;45:195-196. [PMID: 19430504].
18. Masunaga K, Toyoda M, Kokuba H, et al. Mucous membrane pemphigoid with antibodies to the β -3 subunit of laminin 332. *J Dermatol* 2011;38:1082-1084. [PMID: 21453313].
19. Nishimura R, Fujimoto N, Kito K, et al. Refractory mucous membrane pemphigoid which developed after allogeneic stem cell transplantation and was successfully treated with rituximab. *Eur J Dermatol* 2013;23:562-564. [PMID: 24001878].
20. Yoneda K, Demitsu T, Kakurai M, et al. Detection of apoptotic keratinocytes in a case of bullous pemphigoid developed after graft-versus-host disease. *Acta Derm Venereol* 2014;94:231-232. [PMID: 23975350].
21. Kato K, Koike K, Kobayashi C, et al. Bullous pemphigoid after allogeneic hematopoietic stem cell transplantation. *Pediatr Int* 2015;57:480-483. [PMID: 26113316].
22. Baba N, Ibuski A, Higashi Y, et al. Anti-laminin-332-type mucous membrane pemphigoid in a patient with T-cell leukemia/lymphoma and graft-versus-host disease. *J Dermatol* 2017;44:e300-e301. [PMID: 28771781].
23. Haber R, Bourrat E, Derache AF, et al. Image Gallery: Juvenile cutaneous chronic graft-versus-host disease presenting as bullous pemphigoid. *B J Dermatol* 2017;177:e69. [PMID: 28940263].
24. Huff SB, Vasu S, Kaffenberger BH. Epitope spread in chronic mucosal GVHD: mucous membrane pemphigoid with rituximab. *Int J Dermatol* 2019;58:240-241. [PMID: 29707776].
25. Kawashima H, Kageji R, Yasutoshi H, et al. Case of pemphigoid with antibodies to BP180 C-terminal domain and α 3 subunit of laminin-332 associated with chronic graft-versus-host disease. *J Dermatol* 2021;48:e447-e448. [PMID: 34114672].
26. Montagnon CM, Lehman JS, Murrell DF, Camilleri MJ, Tolkachjov SN. Subepithelial autoimmune bullous dermatoses disease activity assessment and therapy. *J Am Acad Dermatol* 2021;85:18-27. [PMID: 33684494].
27. Moreno JC, Valverde F, Martinez F, et al. Bullous scleroderma-like changes in chronic graft-versus-host disease. *J Eur Acad Dermatol Venereol* 2003;17:200-203. [PMID: 12705752].

Table 1. Subepidermal autoimmune blistering diseases after allogeneic stem cell transplantation.

Case	Author, year	Disease/ Sources of SC	Age/Sex	GVHD	Duration* (months)	Diagnoses (antigens)	Treatment	Outcome	Ref
1	Ueda et al., 1986	AML/BM	46/M	+	3	BP (ND)	PSL/AZA	CR	[6]
2	Lacour et al., 1988	AML/BM	29/M	+	10	BP (BP230)	PSL	CR	[7]
3	Burger et al., 1992	AML/BM	28/M	+	23	EBA (collagen VII)	CSA	CR	[8]
4	Delbaldo et al., 1992	CML/BM	47/M	+	3	BP (BP180)	PSL/CSA	CR	[9]
5	Kikuchi et al., 1999	AML/BM	50/M	+	7.5	BP (BP180/230)	PSL	CR	[10]
6	Szabolcs et al., 2002	ALL/UCB	18/M	+	7	BP (BP180/230)	PSL/RTX/CD25 MoAb	CR	[11]
7	Nagai et al., 2002	MDS/PBSC	40/M	+	16	BP (BP180/230)	PSL/CSA	Death (Sepsis)	[12]
8	Kawasuji et al., 2004	NHL/ PBSC	44/F	+	16	BP (BP180)	PSL	Refractory	[13]
9	Aisa et al., 2005	ALL/BM	17/M	+	18	MMP (BP230)	PSL	CR	[14]
10	Izumi et al., 2007	ALL/BM	55/F	+	30	BP (BP180/ laminin332)	PSL	CR	[15]
11	Takahara et al., 2009	AML/BM	35/F	+	6	MMP (laminin332)	MINO	Death (Disease progression)	[16]
12	Mahmood et al., 2010	BL/ PBSC	51/M	-	3	MMP(ND)	mPSL/IVIG	CR	[17]
13	Masunaga et al., 2011	AML/BM	25/M	+	87	MMP (laminin332)	PSL/BMS/ MINO/dapson	CR	[18]
14	Nishimura et al., 2013	NHL/PBSC	50/F	-	7	MMP (BP180/ laminin332)	PSL/ CSA/ dapson/ RTX	Refractory	[19]
15	Yoneda et al., 2014	AML/BM	57/F	+	4	BP	PSL	CR	[20]
16	Kato et al., 2015	ALL/BM	16/M	+	5	BP (BP180)	PSL	Death (Disease progression)	[21]
17	Baba et al., 2017	ATLL/ PBSC	63/M	+	11	MMP (laminin332)	PSL	CR	[22]
18	Haber et al., 2017	CMML/ UCB	5/M	Not described	8.5	BP (ND)	SS	CR	[23]
19	Huff SB et al., 2018	ALL/ PBSC	52/M	+	8	MMP (BP180)	BMS/MTX/ RTX/TCL/MM/ IVIg	CR	[24]
20	Kawashima et al., 2021	NHL/PBSC	65/M	+	16.5	BP (BP180/ laminin332)	PSL/CSA	CR	[25]
21	Hida et al., 2023	ALL/ PBSC	48/F	+	30	BP (laminin332)	TC/NA	CR	Current report

*Duration, between SCT and onset of autoimmune blistering diseases.

ALL, acute lymphocytic leukemia; AML, acute myeloid leukemia; ATLL, adult T-cell leukemia/lymphoma; BL, biphenotypic leukemia; BM, bone marrow; BMS, betamethasone; BP, bullous pemphigoid; CD25, CD25 monoclonal antibody; CML, chronic myelogenous leukemia; CMML, chronic myelomonocytic leukemia; CR, completely resolved; CSA, cyclosporine A; EBA, epidermolysis bullosa acquisita; IVIg, intravenous immunoglobulin; MINO, minocycline; MM, mycophenolate mofetil; MMP, mucous membrane pemphigoid; MTX, methotrexate; NA, niacinamide; ND, not described; NHL, non-Hodgkin's lymphoma; PBSC, peripheral blood stem cell; PSL, prednisolone; RTX, rituximab; SS, systemic steroids; TC, tetracycline; TCS, tacrolimus; UCB, umbilical cord blood