

Case Presentation

A bruise-like patch in a 4-year-old girl

Y.N Lau¹, A.G Affleck¹, S.L Edwards², F Hogg³, S Laube⁴

Dermatology Online Journal 19 (9): 4

¹Department of Dermatology, ²Department of Histopathology, ³Department of Plastic Surgery, Ninewells Hospital and Medical School, Dundee, United Kingdom. ⁴Department of Dermatology, Borders General Hospital, Melrose

Correspondence

Y. N. Lau
Department of Dermatology
Ninewells Hospital and Medical School
Dundee, United Kingdom
Tel: (44)1382 632821 Fax:
Email: yit.lau@nhs.net

Abstract

Dermatofibrosarcoma protuberans (DFSP), a rare medium grade sarcoma, occasionally occurs in childhood and is even more rarely present at birth. In children, the clinical appearance may be mistaken for a vascular malformation and so delayed diagnosis is not uncommon. Dermatofibrosarcoma protuberans is locally invasive and notorious for its high recurrence rate even after attempted wide local excision owing to extensive subclinical and asymmetrical extensions. In adult DFSP, Mohs Micrographic Surgery (MMS) is the treatment of choice because it offers a higher clearance rate compared to wide local excision. However, MMS may result in extended operating times owing to tissue processing and multiple stages. In children, this means a prolonged period under general anesthetic, which may be undesirable. We describe an interesting case of a 4-year-old girl diagnosed with DFSP. She underwent a modified MMS procedure in which she had two short general anesthetics. The advantage of MMS technique in which the full peripheral and deep margin of the specimen was examined.

Keywords: Dermatofibrosarcoma protuberans, DFSP, child, Mohs Micrographic Surgery

Case Report

A 4-year-old girl presented with a persistent and slowly enlarging bruise-like lesion on her left infraclavicular skin. The macule was noticed a year prior to presentation, but may well have been present in infancy. Examination revealed a bland bluish-red patch with no textural change (Figure 1). The lesion was observed for 12 months during which time it enlarged slightly. Owing to persistence of the patch and parental pressure, a punch biopsy was performed, which showed a monotonous proliferation of elongated spindle cells in the dermis, with diffuse expression of CD34 consistent with DFSP (Figures 2,3,4). A Magnetic Resonance Imaging (MRI) scan showed tumor extending into the deep dermis but not involving fascia. After discussion with the parents, MMS was selected as the preferred treatment option. To minimize the length of time under general anesthetic, a modified approach to MMS was undertaken. While under a short general anesthetic, the lesion was excised down to fascia with a 1cm peripheral clinical margin using the MMS technique. The defect was reconstructed by a plastic surgeon immediately after stage 1 by direct layered linear closure. The frozen section specimen was examined and shown to have persistent tumor at the deep margin (Figures 5, 6). A second stage of MMS was performed a week later using a short general anesthetic, excising fascia and a thin cuff of muscle (Figure 7). Layered closure of the defect was achieved. Interpretation of histology from the second stage of MMS was challenging owing to the inflammatory response to the recent surgery (Figure 8). Immunohistochemistry on formalin fixed, paraffin embedded sections was helpful. The cells stained with CD68 (Figure 9) confirming that they were macrophages and there was no evidence of residual DFSP. Clearance of tumor was achieved after this second stage. Review at 3 months post-operatively showed a satisfactory scar (Figure 10).

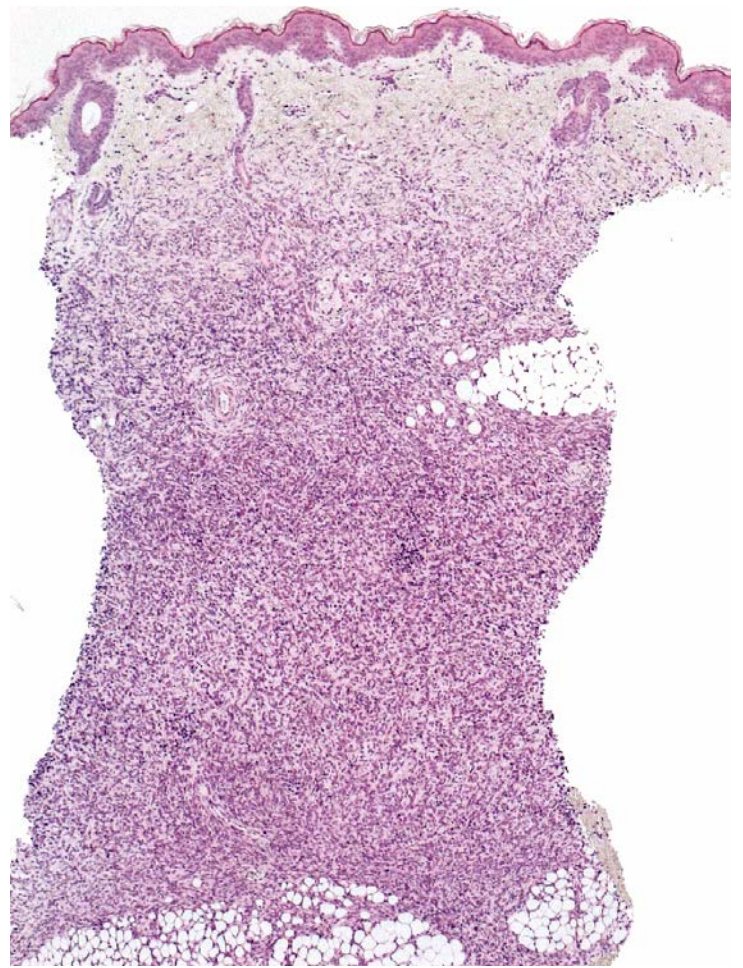
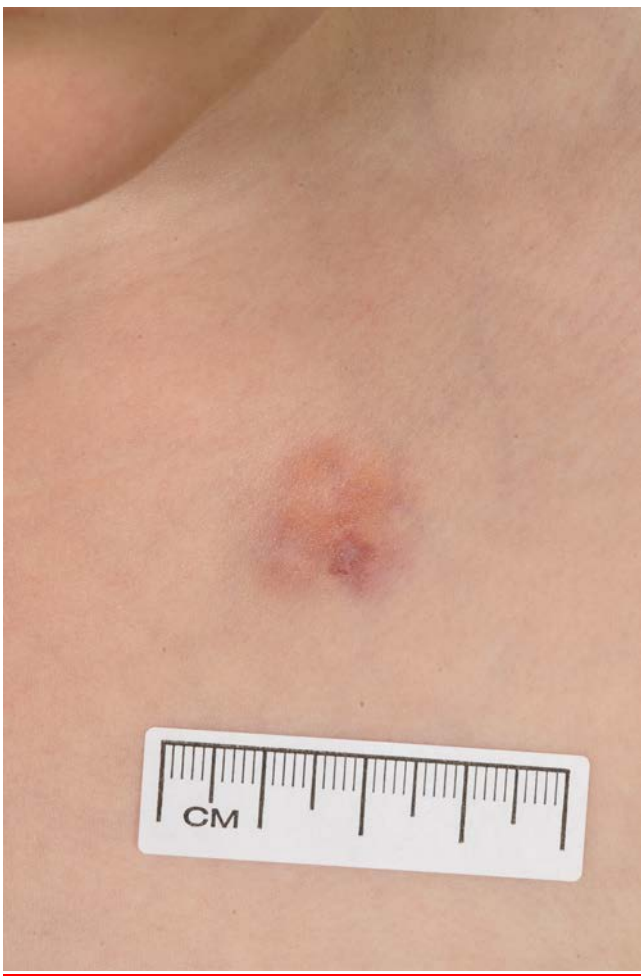

Figure 1. Bruise-like patch on left infraclavicular aged 4.

Figure 2. Low power view of punch biopsy showing a cellular infiltrate in dermis

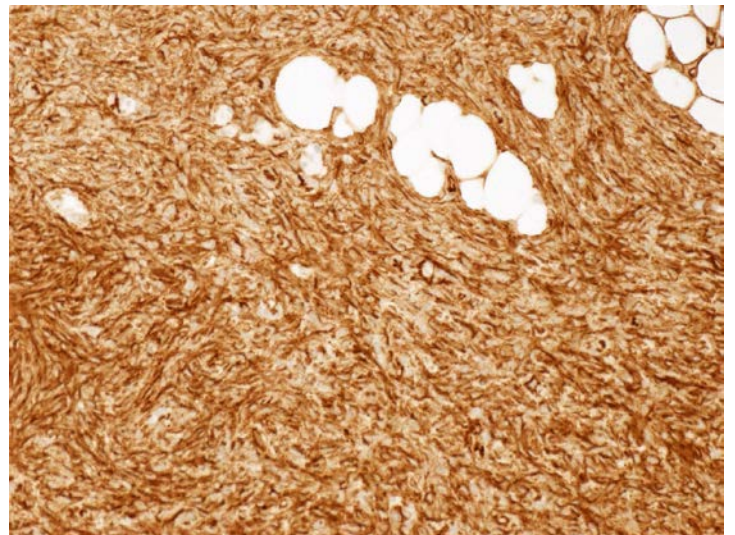
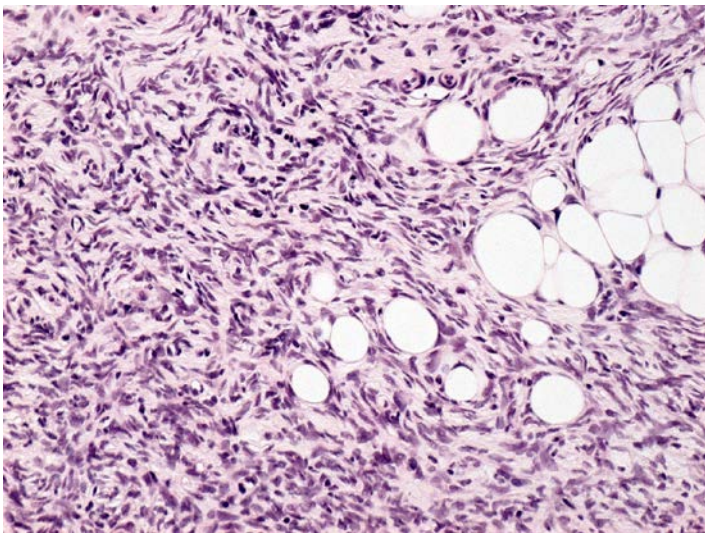


Figure 3. Higher power slide (x20) showing monomorphous proliferation of elongated spindle cells

Figure 4. Spindle cell tumor stains positively for CD34

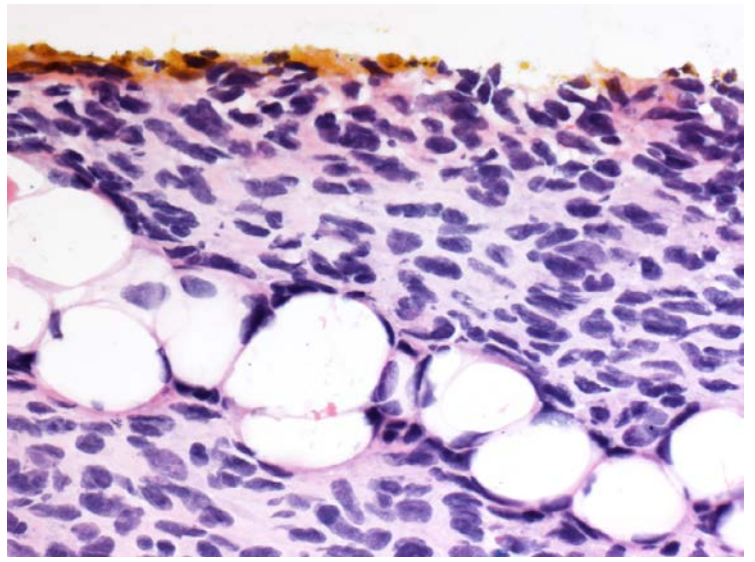
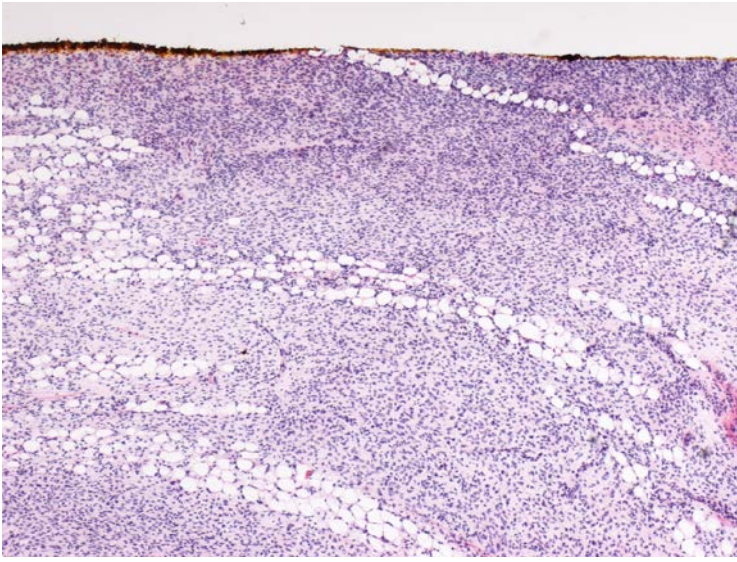


Figure 5. Cryostat section (x40) of DFSP at inked deep resection margin after first stage of Mohs' Micrographic Surgery

Figure 6. High power (x400) of Figure 5

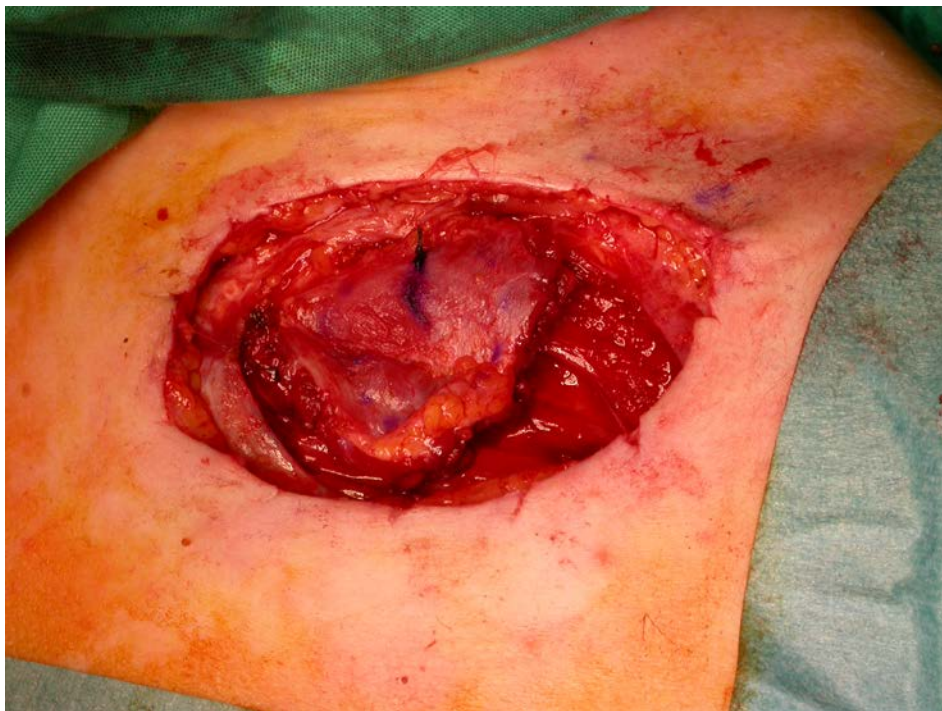

Figure 7. Defect during second stage MMS

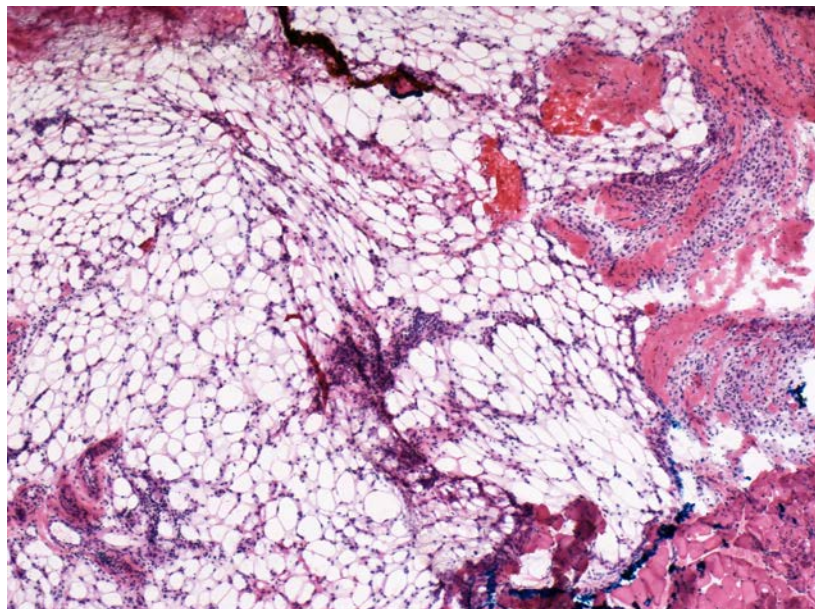


Figure 8. Cryostat section (x40) of second stage MMS showing infiltrate in connective tissue and subcutis

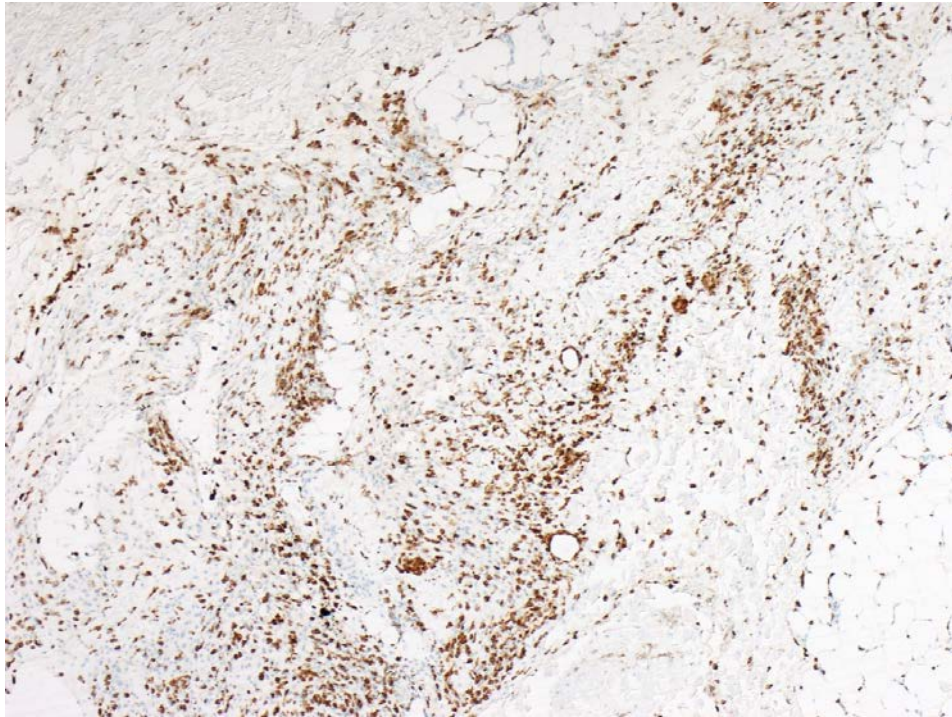


Figure 9. Formalin fixed paraffin embedded section (x40) of second stage MMS stained with CD68

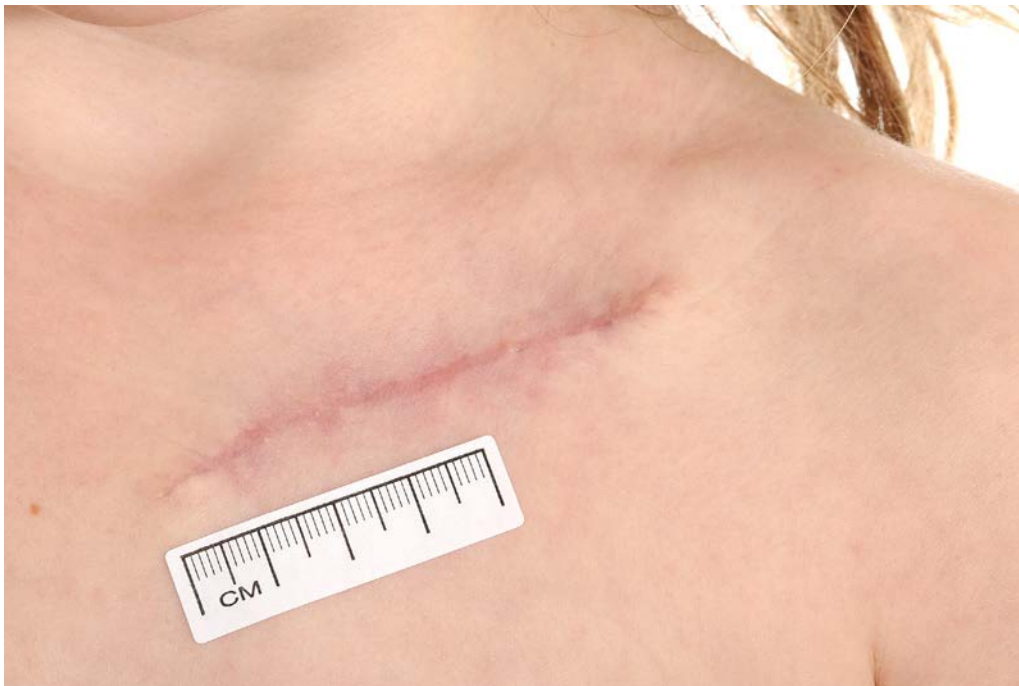

Figure 10. Satisfactory scar at 3 months review.

Discussion

Dermatofibrosarcoma protuberans, a rare medium grade sarcoma, occasionally occurs in childhood and is even more rarely present at birth [1]. In children, the clinical appearance may be mistaken for a vascular malformation resulting in delayed diagnosis. DFSP is locally invasive and notorious for its high recurrence rate even after attempted wide local excision owing to extensive subclinical and asymmetrical extensions [2].

In adult DFSP, MMS is a desirable treatment, especially for head and neck tumors, because it offers a higher clearance rate compared to WLE and the added bonus of potential tissue-sparing for preserving vital structures and improving aesthetic outcomes. Mohs Micrographic Surgery allows full peripheral and deep margin sampling as opposed to conventional WLE in which specimens are processed in vertical sections similar to a bread loaf, which allows only limited sampling of the specimen. Love *et al* found that congenital DFSP treated with MMS had a clearance rate of

100% compared to WLE in which the clearance rate was 89% [3]. In adult-onset DFSP, a recent pooled literature review suggested an overall relative risk of recurrence for WLE vs. MMS patients of 15.9 (95% CI 7.2–35.5)[4]. Standard WLE with 2-4cm margin may be a satisfactory alternative in “lower risk” anatomical sites in which tissue-sparing is not so important and the consequences of future recurrence less likely to be as severe.

MMS is typically performed using local anesthetic, which is not practical in young children. Use of a prolonged general anesthetic is also not desirable, but may be needed because of the extended time of tissue processing and multiple stages. Our patient underwent a modified procedure of MMS in which she had two short general anesthetics, allowing the use of the MMS technique to examine all the margins and so maximize the chance of clearance.

Conclusions

- DFSP may present as a banal looking erythematous patch in a child making clinical diagnosis difficult.
- There should be a low threshold for biopsy in any persistent lesion in childhood of diagnostic uncertainty.
- A modified staged MMS approach in a child reduces the time of general anesthetic required and is a pragmatic way to try and achieve the best outcomes.
- A multidisciplinary approach is desirable in the management of DFSP in a child

References

1. Iqbal CW, Peter SS, Ishitani MB. Pediatric Dermatofibrosarcoma Protuberans: Multi-Institutional Outcomes. *J Surg Res.* 2011; 170: 69-72. [PMID: 21429521]
2. Feramisco J, Larsen F, Weitzul S, Cockerell C, Ghali F. Congenital Atrophic Dermatofibrosarcoma Protuberans in a 7-Month-Old Boy. *Pediatric Dermatology* 2008; 25(4): 455-459. [PMID: 18789087]
3. Elliot Love W, Keiler SA, Tamburro JE, Honda K, Gosain AK, Bordeaux JS. Surgical Management of Congenital Dermatofibroma protuberans. *J Am Acad Dermatol* 2009; 61(6): 1014-1023. [PMID: 19925926]
4. Paradisi A, Abeni D, Rusciani A, Cigna E, Wolter M, Scuderi N, Rusciani L, Kaufmann R, Podda M. Dermatofibrosarcoma protuberans: wide local excision vs Mohs micrographic surgery. *Cancer Treat Rev* 2008; 34(8): 728-736. [PMID: 18684568]