

**Photo vignette**

**Giant molluscum contagiosum presenting as lid neoplasm in an immunocompetent child**

**Md. S Alam MS<sup>1</sup> and Neha Shirao DNB<sup>1</sup>**

**Dermatology Online Journal 22 (1): 14**

**Orbit, Oculoplasty, Reconstructive and Aesthetic Services, Medical Research Foundation, Sankara Nethralaya, Chennai, India**

**Correspondence:**

S Alam  
18. College road  
Sankara Nethralaya, Chennai, 600006

---

**Abstract**

A three-year-old boy presented to our oculoplastic clinic with complaints of painless gradually increasing right upper lid mass for the last 6 months. On examination a firm mass measuring roughly 1x1 cm was present on the upper lid. The mass was non tender with fine superficial vessels running over it. A differential diagnosis of epidermoid cyst, vascular malformation, pilomatrixoma, and juvenile xanthogranuloma was considered. The patient underwent excisional biopsy of the mass. On gross examination the mass had a brain like appearance. Histopathological examination confirmed the diagnosis of molluscum contagiosum. It is rare for molluscum contagiosum to present as a solitary lid tumor. A brain like appearance of the excised mass can provide a clue towards the diagnosis

**Introduction**

Molluscum contagiosum (MC) is a skin infection caused by a double stranded DNA Poxvirus. It has a varied ocular presentation, the most common being benign papular or nodular eruptions of the eyelids with central umbilication [1]. The disease is generally transmitted by direct contact with an infected host or contaminated fomite. The condition is most commonly seen in immunocompetent children, but in the last 30 years has become more common in immunocompromised adults [1, 2]. MC presenting as a solitary lid nodule is uncommon [3]. We report a 3-year-old healthy child with molluscum contagiosum presenting as a solitary lid mass with fine superficial vessels, clinically mimicking an eyelid tumor.

**Case synopsis**

A 3-year-old boy presented to our oculoplasty clinic with a gradually increasing painless mass on the right upper lid for the last six months. There was no history of trauma, bleeding from the mass, or increase in size on crying or coughing. There was no history of similar swelling anywhere else in the body or any other systemic complaints. On examination visual acuity was normal for age and the anterior and posterior segment examination was unremarkable.

On local examination a firm non-tender mass measuring roughly 1×1 cm was present on the right upper eyelid. It was not fixed to underlying structures or overlying skin. The skin overlying the mass was erythematous with multiple superficial vessels running over it (Figure. 1a). Based on history and examination a differential diagnosis of epidermoid cyst, pilomatrixoma, vascular malformation, and juvenile xanthogranuloma was considered.

The child underwent excisional biopsy through a lid crease approach. The mass was easily separated from the surrounding structures and completely removed in one piece. On gross examination it was whitish in color with corrugations over its surface (Figure. 1 b).

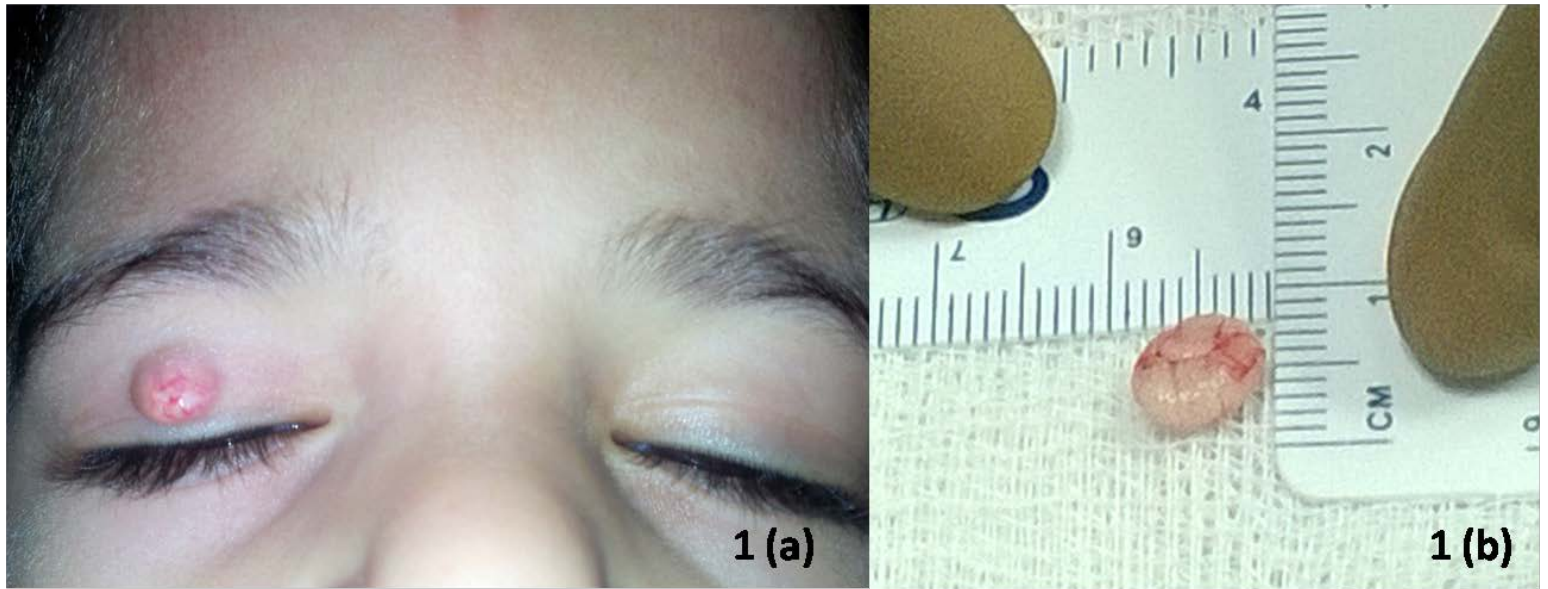


Figure 1. Insert caption here

Histopathological examination revealed multiple large eosinophilic intracytoplasmic bodies separated by fine dermal septae, classic for Henderson- Patterson bodies (Figure. 2). Based on histopathological findings a diagnosis of molluscum contagiosum was made.

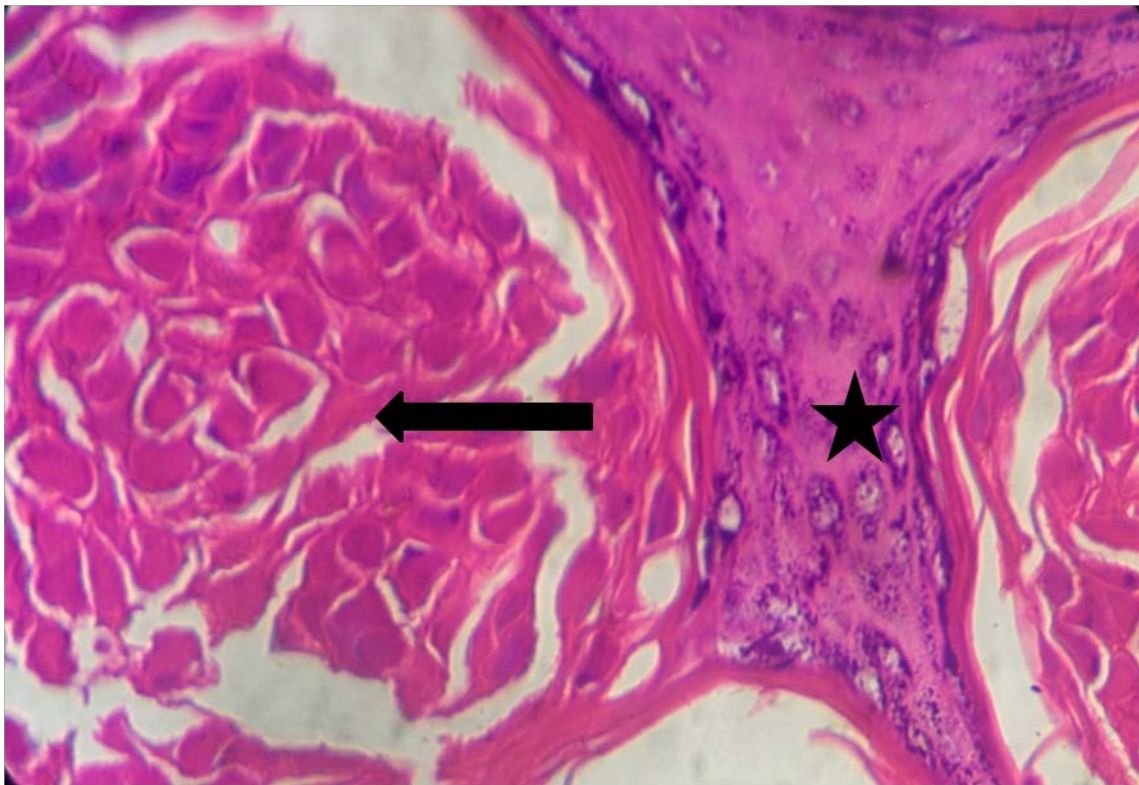


Figure 2. Insert caption here

The child underwent a thorough systemic evaluation to rule out any immunocompromised state. All investigations were found out to be negative. There has not been any recurrence on 1 year of follow up.

## Discussion

The characteristic presentation of adnexal MC in children has been described as exhibiting multiple raised, shiny, smooth dome shaped lesions with umbilicated centers, which may or may not exude cheesy material [3]. MC presenting as a single large nodule is known as giant MC, which can grow up to 3 cm and mostly occurs in immunocompromised individuals [4].

Multiple unusual presentations of MC in immunocompetent children have been reported in the literature including chalazia, fungating mass, ulcerated nodule, lid margin nodule, and granuloma [5]. To the best of our knowledge, MC in the form of a solitary lid mass mimicking an eye lid tumor in an immunocompetent child is rarely reported. In one case, the child had multiple other characteristic lesions, which pointed toward the diagnosis of MC [6, 7]. In another case reported by Vardhan et al the child had a characteristic central umbilication, again providing a clue to the clinical diagnosis [8]. The presence of fine surface vasculature, erythema, mobility of overlying skin, and the absence of characteristic umbilication makes the presentation in our case diverse from the previously reported ones and the clinical diagnosis challenging.

Vardhan et al [8] in their case report have mentioned that the excised mass had a characteristic brain-like appearance morphologically. The mass had multiple lobes and gyri-like corrugation over its surface. They noted that this appearance had not been described in literature previously and such a gross appearance could point toward the diagnosis of MC. Interestingly, we also found a similar appearance in the excised mass.

Various treatment modalities including cryotherapy, application of chemical agents like phenol and trichloroacetic acid, and topical agents like cidofovir, imiquimod cream, and intralesional interferon alpha have been described for the treatment of MC [8]. But these agents can only be used in cases where clinical presentation is typical for MC. In ambiguous cases histopathological diagnosis by excision biopsy is required.

It is extremely rare for MC to present as a solitary lid tumor without its other characteristic clinical features, such as umbilication. In the absence of these clinical features, the final diagnosis can only be made after biopsy, though the brain like appearance of the excised mass can point towards a diagnosis of MC before the histopathological results are obtained.

## References

1. Schornack MM, Siemsen DW, Bradley EA, Salomao DR, Lee HB. Ocular manifestations of molluscum contagiosum. *Clinical and experimental optometry*. 2006;89:390-3. [PMID: 17026608]
2. Robinson MR, Udell IJ, Garber PF, Perry HD, Streeten BW. Molluscum contagiosum of the eyelids in patients with acquired immune deficiency syndrome. *Ophthalmology*. 1999;99:1745-7. [PMID: 1454352]
3. Khaskhely NM, Maruno M, Hoshiyama Y, Uezato H, Nonaka S. Molluscum contagiosum appearing as a solitary lesion on the eyelid. *J Dermatol*. 2000;27:68-70. [PMID: 10692832]
4. Chattopadhyay DN, Basak SK, Ghose S. HIV- positive patient presented with giant molluscum contagiosum of the eyelid. *J Indian Med Assoc*. 1997;95:202. [PMID: 9420414]
5. Rao VA, Baskaran RK, Krishnan MM. Unusual cases of molluscum contagiosum of the eye. *Indian J Ophthalmol*. 1985;33:263-5. [PMID: 3842837]
6. Pandhi D, Singhal A. Giant molluscum contagiosum. *Indian Pediatr*. 2005;42:488-9. [PMID: 15923699]
7. Karadag AS, Karadag R, Bilgili SG, Calka O, Demircans YT. Giant molluscum contagiosum in an immunocompetent child. *J Pak Med Assoc*. 2013 Jun;63(6):778-9. [PMID: 23901686]
8. Vardhan P, Goel S, Goyal G, Kumar N. Solitary giant molluscum contagiosum presenting as lid tumor in an immunocompetent child. *Indian J Ophthalmol*. 2010;58:236-8. [PMID: 20413930]