

**Volume 22 Number 10  
October 2016**

**Case Presentations**

**Coalescing nodules on the trunk of an infant: juvenile xanthogranuloma ‘en plaque’**

**Jennifer T. Hau, MD and Kathy Langevin, MD**

**Dermatology Online Journal 22 (10): 15**

**Department of Medicine, Division of Dermatology, University of California Los Angeles (UCLA), Los Angeles, California**

**Correspondence:**

Jennifer T. Hau, MD  
University of California, Los Angeles, Division of Dermatology  
200 Medical Plaza, Suite 450  
Los Angeles, CA 90095-6957  
Tel. 310-825-6911 Fax. 310-794-7005  
Email: [jhau@mednet.ucla.edu](mailto:jhau@mednet.ucla.edu)

---

**Abstract**

Juvenile xanthogranuloma (JXG) is a benign, non-Langerhans cell histiocytosis, which commonly manifests as a solitary papule or nodule in infants and young children. However, other less common clinical presentations have been reported including clustered, agminated or plaque-like. It is important to recognize these variants, as diagnosis is often clinical. We highlight a case of juvenile xanthogranuloma presenting as nodules on the trunk of an infant that gradually coalesced to form a larger plaque.

**Keywords: clustered, agminated, juvenile xanthogranuloma, histiocytosis**

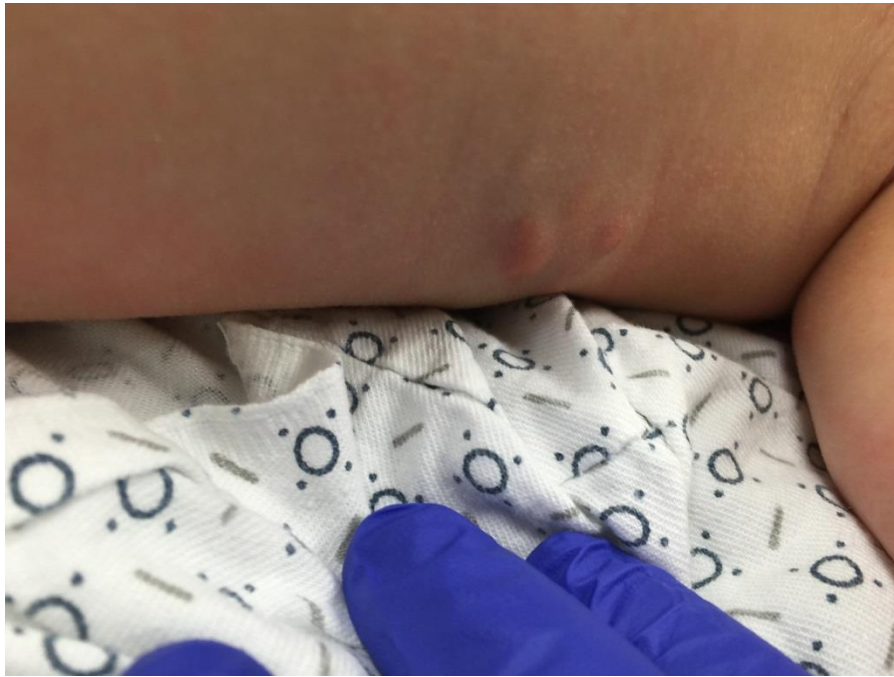**Introduction**

Juvenile xanthogranuloma (JXG) is a benign, non-Langerhans cell histiocytosis, which typically presents as a solitary discrete papule or nodule involving the head or trunk of infants and young children. The diagnosis of JXG is often made clinically. Juvenile xanthogranuloma morphologies including clustered, agminated, or plaque-like lesions are uncommon and may therefore present diagnostic challenges.

**Case synopsis**

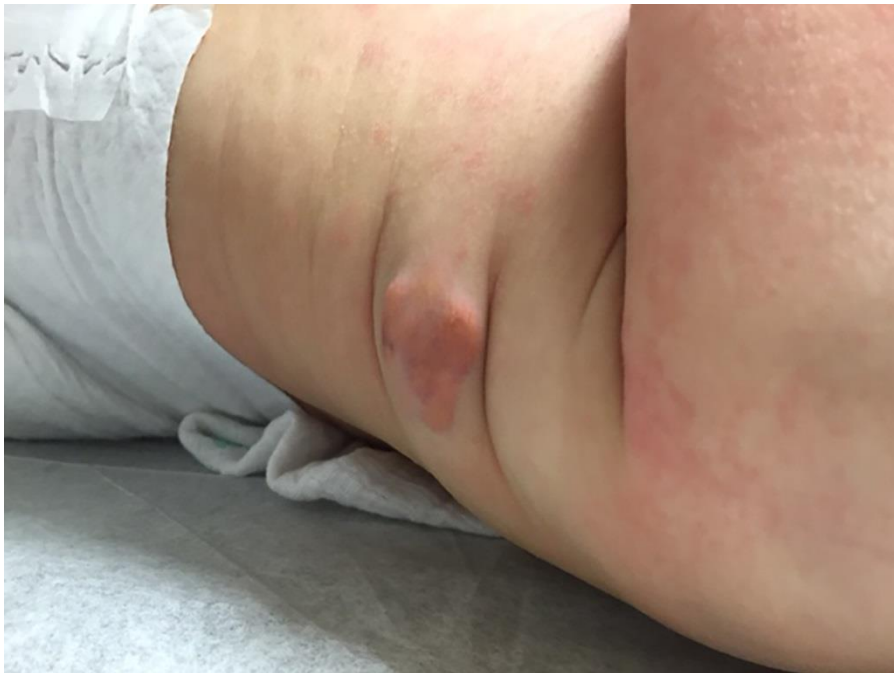A 3-month-old girl with history of eczema presented for evaluation of a progressively enlarging plaque comprised of coalescing nodules on her left upper trunk. The lesion was initially noticed six weeks prior and did not appear itchy or bothersome to the patient. Her parents denied any preceding trauma to the area. The patient was otherwise healthy and developing normally.

On physical examination, there was a 3.2 cm x 2 cm plaque of clustered 3-10 mm firm pink-brown to yellow nodules on the left upper trunk (Figure 1).



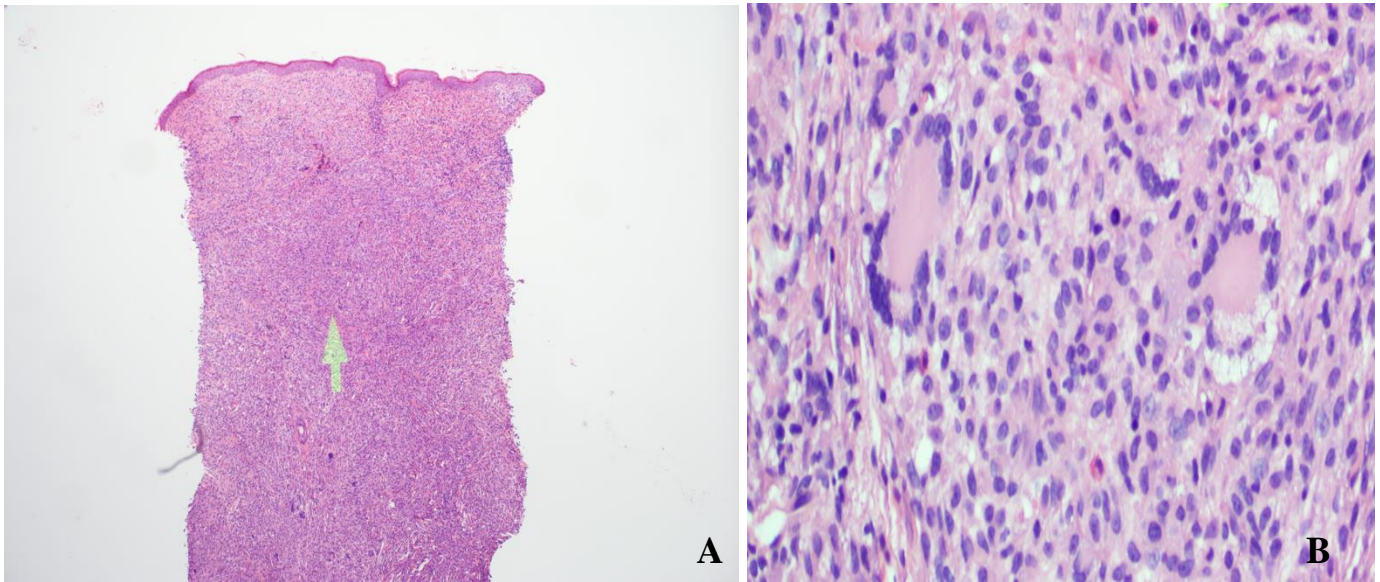
**Figure 1.** Clustered firm yellow to red-brown nodules on the left upper trunk of a 3-month old infant.

At 2-month follow-up the lesions had gradually continued to grow and coalesce. A 3-mm punch biopsy was taken from the left upper trunk (Figure 2).



**Figure 2.** Gradual enlargement and coalescence into larger plaque at 2-month follow-up.

Histopathologic examination demonstrated a dense cellular histiocytic proliferation extending through the dermis with multiple Touton giant cells (Figures 3). Immunohistochemical stains demonstrated CD68 and Factor XIIIa positivity highlighting lesional cells. S-100 and CD1a were negative.



**Figures 3.** A) Dense cellular histiocytic proliferation throughout the dermis (hematoxylin and eosin; original magnification x10) B) Touton type giant cells (hematoxylin and eosin; original magnification x20).

At 4-month and 7-month follow-up, the lesions remained stable in size and asymptomatic. Ophthalmology exam was unremarkable, with no ocular involvement.

## Discussion

Disseminated, multiple lesions or extracutaneous JXG lesions are rare [1]. Less common, atypical JXG morphological variants include agminated, clustered, granuloma-annulare-like, coupled, linear-agminated, segmental, lichenoid, hyperkeratotic, pedunculated, and subcutaneous [1, 2, 3]. Clustered or agminated lesions, as seen in our patient, present as multiple pink, yellow, or red-brown coalescing papules and nodules. When forming a solitary plaque, as in our patient, this lesion has been referred to as JXG ‘en plaque’. Clinical differential diagnosis includes Langerhans cell histiocytosis, mastocytoma, and xanthoma disseminatum. Biopsy enables diagnosis, as histopathologic and immunohistochemical findings are consistent with juvenile xanthogranuloma. Juvenile xanthogranuloma is characterized by a diffuse dermal infiltrate of foamy histiocytes and Touton giant cells. Immunohistochemistry studies demonstrate CD68 and factor XIIIa positive lesional cells, and staining for S-100 and CD1a is negative [2, 4].

Juvenile xanthogranuloma may be associated with disorders including neurofibromatosis type I, Neimann-Pick disease, myeloproliferative diseases, and urticaria pigmentosa [1]. Associated disorders and extracutaneous involvement should be excluded. The eye is the most common location for extracutaneous lesions and ocular involvement can result in glaucoma, hyphema, or vision loss [5]. When limited to the skin, the prognosis is excellent and lesions typically regress spontaneously without treatment [3, 4]. In our case, as in previous reported cases of clustered JXG, there has been no visceral involvement or other complications. Thus, as with classic skin-limited JXG, a conservative approach of regular follow-up and monitoring is recommended [2].

The uncommon variations in clinical presentations of JXG present diagnostic challenge and an understanding of the different clinical forms aids in correct diagnosis without unnecessary invasive procedures. There have been multiple other reports of juvenile xanthogranuloma presenting as grouped or coalescing lesions. As such, clustered JXG, agminated JXG, or JXG ‘en plaque’ [5] should be included in the differential diagnosis of an infant presenting with coalescing papules or nodules [2, 4, 6, 7].

## References

1. Kiorpelidou D, Stergiopoulou C, Zioga A, Bassukas ID. Linear-agminated juvenile xanthogranulomas. *Int J Dermatol.* 2008;47(4):387-389. [PMID:18377606]
2. Messeguer F, Agusti-Mejias A, Colmenero I, Hernandez-Martin A, Torrelo A. Clustered juvenile xanthogranuloma. *Pediatr Dermatol.* 2013;30(6):e295-e296.[PMID:22957538]
3. Ng SY. Segmental juvenile xanthogranuloma. *Pediatr Dermatol.* 2014;31(5):615-617. [PMID:23889163]

4. Kaur MR, Brundler MA, Stevenson O, Moss C. Disseminated clustered juvenile xanthogranuloma: an unusual morphological variant of a common condition. *Clin Exp Dermatol.* 2008;33(5):575-7. [PMID:18477008]
5. Mowbray M, Schofield OM. Juvenile xanthogranuloma en plaque. *Ped Dermatol.* 2007;24(6):670-671. [PMID:18036001]
6. Caputo R, Cambiagli S, Brusasco A, Gelmetti C. Uncommon clinical presentations of juvenile xanthogranuloma. *Dermatology.* 1998;197(1):45-47. [PMID:9693185]
7. Gass J, Burrows N. Papular juvenile xanthogranuloma en plaque in an infant. *Pediatr Dermatol.* 2008;25(3):415. [PMID:18577071]