

Congenital atrichia with papular lesions

Sumit Ashok Hajare, Sujit Gavali, Jayesh Mukhi, Rajesh Pratap Singh

Affiliations: Department of Dermatology, Venereology and Leprosy, Government Medical College, Nagpur, Maharashtra, India

Corresponding Author: Dr. Sumit Ashok Hajare, Assistant Professor, Department of Dermatology, Venereology and Leprosy, Government Medical College, Nagpur, Maharashtra, India, Tel: 7721939663, Email: sumithajareofficial@gmail.com

Abstract

Congenital atrichia with papular lesions is a rare, autosomal recessive and irreversible form of total alopecia of the body hair characterized by hair loss soon after birth and the development of keratin-filled cysts or horny papules over extensive areas of the body. The condition is associated with a mutation of the human hairless gene on chromosome region 8p12. We report a 1-year-old boy presenting with the absence of scalp and body hair since birth. On examination, he had complete absence of hair on the scalp, eyebrows, and eyelashes. Multiple, discrete, pearly-to-skin-colored papules of 1-3mm in size were present over the scalp. The skin biopsy from a scalp papule revealed normal overlying epidermis with multiple keratin cysts and hypoplastic hair follicles in the upper dermis.

Keywords: congenital atrichia, papular lesions over scalp, cluster of white dots, keratin filled cysts, congenital alopecia

Introduction

Congenital alopecia includes congenital atrichia with papular lesions (APL), alopecia universalis, vitamin D-dependent rickets type IIA, and syndromes such as Moynahan syndrome, hidrotic ectodermal dysplasia, and progeria. Congenital atrichia with papular lesions is a rare, autosomal recessive and irreversible form of total alopecia of the body hair characterized by hair loss soon after birth associated with the development of keratin-filled cysts or horny papules over extensive

areas of the body. A mutation of the human hairless gene on chromosome region 8p12 is responsible [1].

Case Synopsis

A one-year-old boy, born of a third-degree consanguineous marriage, was brought to the outpatient department of dermatology because of the absence of scalp and body hair since birth. At the age of 10 months, the parents also noticed multiple skin colored raised papules over the scalp, which progressively increased in number. He was previously treated for alopecia universalis and vitamin D-dependent rickets type IIA but his alopecia was unresponsive to therapy. Developmental milestones were within normal limits. Sweating and body temperature was normal. There was no history of decreased hearing or seizures. A 15-year-old relative of the patient reportedly has similar lesions (**Figure 1**).

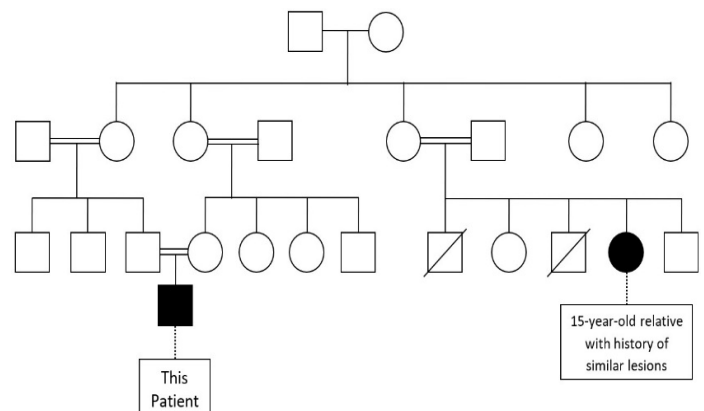


Figure 1. Pedigree chart of congenital atrichia patient.

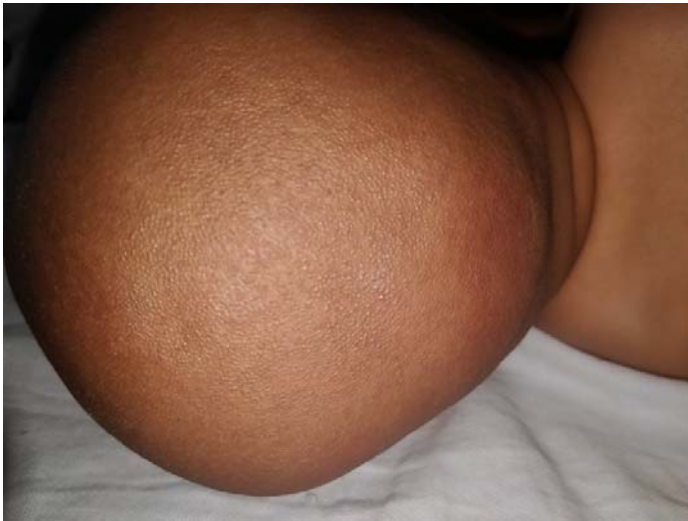

Figure 2. Multiple, discrete, pearly to skin colored papules of size 1-3mm were present over the scalp with complete absence of hair on the scalp.

On examination, the patient had a complete absence of hair on the scalp, eyebrows, and eyelashes (**Figure 2, 3**). Multiple, discrete, pearly to skin colored papules of 1-3mm in size were present over the scalp. He had no abnormalities of nails, teeth, mucosae, palms, and soles. His physical growth was normal according to age. No bony abnormalities, dysmorphic features, or systemic involvement was present. Blood counts and liver and renal profiles were normal. The Vitamin D3 levels (1,25-dihydroxycholecalciferol) were 20.44ng/ml (normal: 30-100ng/ml). Radiographs of the wrist joints were

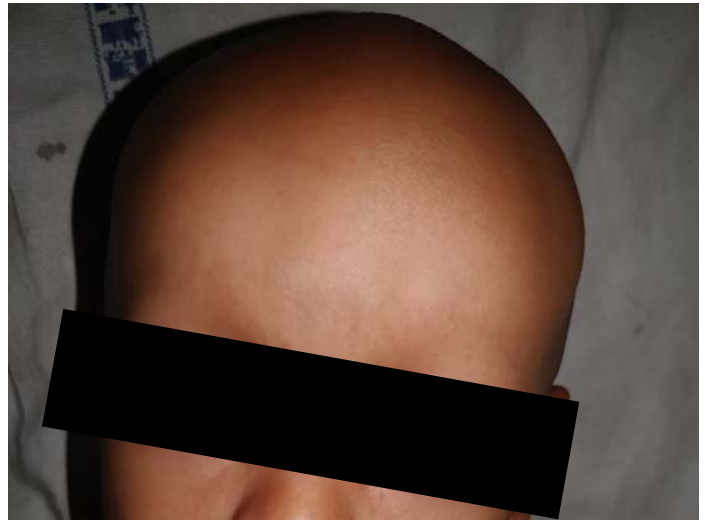

Figure 3. Complete absence of hair on the eyebrows and absence of majority of eyelashes. Few eyelashes present on both upper eyelids.

normal. The diagnoses of congenital atrichia with papular lesions, alopecia universalis, and vitamin D-dependent rickets IIA were considered.

Trichoscopy (Mini 3000 LED Dermatoscope, Heine, Germany) showed pinpoint white dots arranged in clusters with no perifollicular pigmentation, inflammation, or occlusion (**Figure 4**). The skin biopsy from a scalp papule revealed normal overlying epidermis with multiple keratin cysts and hypoplastic hair follicles in the upper dermis (**Figure 5**). There were no terminal hairs or sebaceous glands. On the basis of clinical, trichoscopic, and histopathological findings we confirmed the diagnosis of congenital atrichia with papular lesions (APL).

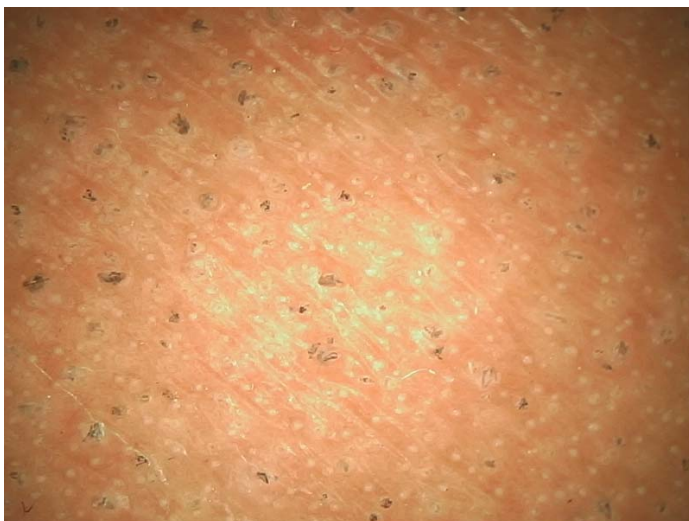

Figure 4. On trichoscopy, pin point white dots (3-4) arranged in clusters with no perifollicular pigmentation, inflammation or occlusion.

Case Discussion

Congenital atrichia with papular lesions is a rare and irreversible form of total alopecia of the scalp, eyebrows, eyelashes, and axillary and pubic areas characterized by hair loss soon after birth and the development of keratin-filled cysts or horny papules over extensive areas of the body involving face, neck, limbs, and trunk [1]. It is inherited as an autosomal recessive disorder. This condition has been noted for decades among a group of people known as Irish Travelers, who have existed as a distinct indigenous

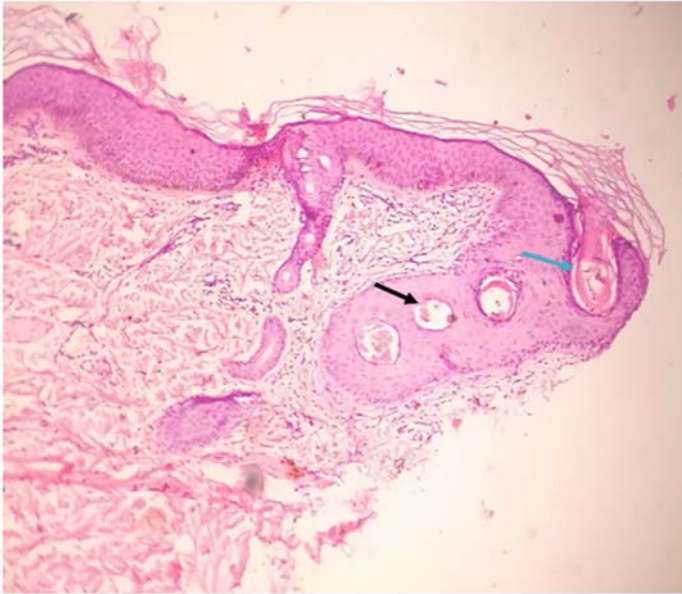


Figure 5. Histopathology of papule over scalp revealed normal overlying epidermis with multiple keratin cysts (Black arrow) and hypoplastic hair follicle in upper dermis (Red arrow). There were no terminal hairs and sebaceous glands. H&E, 40x.

ethnic minority within Ireland. It was first referred to as congenital atrichia by Ahmad et al. [2]. These patients have normal development, hearing, teeth, and nails. There are no abnormalities of sweating.

The exact molecular basis of this disease is not known. The hair matrix cells undergo premature and massive apoptosis and have a decline in *Bcl-2* expression. Therefore, communication between the dermal papillae and stem cells in the bulge are not transmitted and further hair growth does not occur. A mutation in the human *hairless* gene located on chromosome 8p21.2 which encodes for a putative single zinc-finger transcription factor protein believed to regulate catagen remodeling in the hair cycle has been implicated [3].

Congenital atrichia may be confused with congenital alopecia universalis but the distinct features such as a history of consanguinity, loss of hair either on eyebrows or eyelids, and scant body hair and vitamin D deficiency in the form of rickets may suggest congenital atrichia. Zlotogorski et al., proposed diagnostic criteria for APL which was revised later by Yip et al. [4]. These features are listed in **Box 1**. Other syndromes associated with congenital alopecia are

Moynahan syndrome (mental retardation, epilepsy), hidrotic ectodermal dysplasia (palmoplantar keratoderma, thickened nails), and aging syndromes [5]. Solitary cases of congenital atrichia have been reported with *situs inversus* and *nevus flammeus* [6, 7].

Conclusion

Congenital atrichia with papular lesions without ectodermal dysplasia is a very rare disorder and can be easily misdiagnosed as alopecia universalis or vitamin D-dependent rickets type IIA. However, trichoscopy and histopathological examination helped us to reach the final diagnosis of congenital atrichia with papular lesions. Hence, a high index of suspicion should be kept in mind in patients presenting with generalized alopecia to avoid misdiagnosis.

Box 1. Diagnostic criteria for APL.

Major criteria (4 out of 5 required for diagnosis)

1. Permanent and complete absence of scalp hair by the first few months of life
2. Few to widespread smooth, whitish, or milia-like papules on the face, scalp, arms, elbows, thighs or knees from infancy or childhood
3. Replacement of mature hair follicle structures by follicular cysts filled with cornified material in scalp histology
4. Mutation(s) in the human hairless gene through genetic testing
5. Clinical and/or molecular exclusion of vitamin D dependent rickets.

Minor criteria (supplementary criteria)

1. Family history of consanguinity.
2. Absence of secondary axillary, pubic, or body hair growth and/or sparse eyebrows and eyelashes.
3. Normal growth and development, including normal bones, teeth, nails and sweating.
4. Whitish-hypopigmented streaks on the scalp.
5. Lack of response to any treatment modality and mesocardia.

Potential conflicts of interest

The authors declare no conflicts of interests.

References

1. Tillman WG. Alopecia congenita: Report of two families. *Br Med J*. 1952;2:428. [PMID: 14944849].
2. Ahmad W, Panteleyev AA, Christiano AM. The molecular basis of congenital atrichia in humans and mice: Mutations in the hairless gene. *J Invest Dermatol Symp Proc*. 1999;4:240-3. [PMID: 10674375].
3. Miller J, Djabali K, Chen T, et al. Atrichia caused by mutations in the vitamin D receptor gene is a phenocopy of generalized atrichia caused by mutations in the hairless gene. *J Invest Dermatol*. 2001;117:612-7. [PMID: 11564167].
4. Zlotogorski A, Panteleyev AA, Aita VM, Christiano AM. Clinical and molecular diagnostic criteria of congenital atrichia with papular lesions. *J Invest Dermatol*. 2002;118:887-90. [PMID: 11982770].
5. Crowder JA, Frieden IJ, Price VH. Alopecia areata in infants and newborns. *Pediatr Dermatol*. 2002;19:155-8. [PMID: 11994183].
6. Sacchidanand S, Sahana M, Hiremagalore R, Asha G. Congenital atrichia associated with situs inversus and mesocardia. *Int J Trichology*. 2012;4:181-3. [PMID: 23180933].
7. Kirit ER, Parthasaradhi A. Congenital atrichia associated with nevus flammeus: A rare association. *Indian Dermatol Online J*. 2014;5:475-7. [PMID: 25396133].