

Photo vignette

What is the prognostic significance of acrometastases?

Baltazard T¹, Arnault JP¹, Dillies AS¹, Joly JP², Lok C¹

Dermatology Online Journal 21 (9): 13

¹Department of Dermatology, Chu Amiens, France

²Department of Gastroenterology, Chu Amiens, France

Correspondence:

Lok, Catherine
Department of Dermatology
Chu Amiens
Place Victor Pauchet, 80000 – AMIENS - FRANCE
Lok.catherine@chu-amiens.fr

Abstract

In contrast with bone metastasis, acrometastases are uncommon and are associated with advanced cancer. We report the cases of two patients with atypical lesions of the fingers in a context of cancer, in which biopsies confirmed a metastasis. Patients died rapidly before treatment was initiated. We discuss the characteristics of these atypical metastatic sites, associated with a generally poor prognosis.

Keywords: Acrometastasis, lung cancer, pancreatic cancer

Introduction

Metastatic tumors of the hand are rare, representing about 0.1% of all bone metastases. Acrometastases are a late manifestation of a primary cancer and are associated with disseminated tumor, but they can also constitute the first sign of an occult cancer. We report two cases of acrometastases in the hands in patients with advanced cancer.

Case synopsis

Case 1:

A 49-year-old man presented to our department with an ulceroproliferative growth involving the distal phalanx of his right middle finger. A diagnosis of botryomycosis was initially suspected. This lesion was painful with subungual and periungual involvement and warping of the nail plate (Figure 1). This heavy smoker was receiving his third-line of systemic treatment for lung cancer following failure of radiotherapy and chemotherapy. No other active metastases were demonstrated.

A biopsy of the lesion of the right hand showed invasion by a squamous cell carcinoma with large, irregular cells suggesting the histological diagnosis of metastatic lung carcinoma (Figure 2A, Figure 2B).

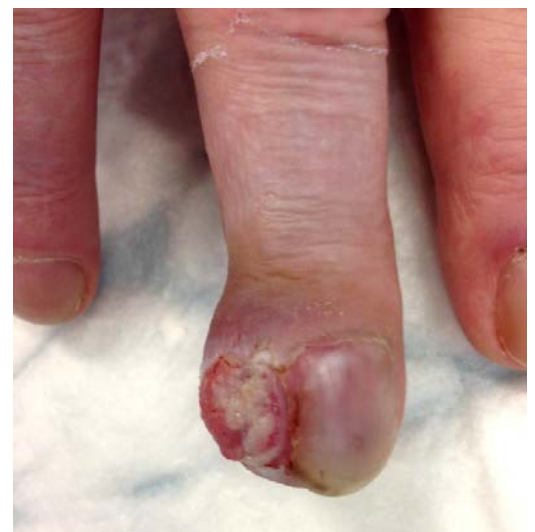

Figure 1. Tumour of the right middle finger.

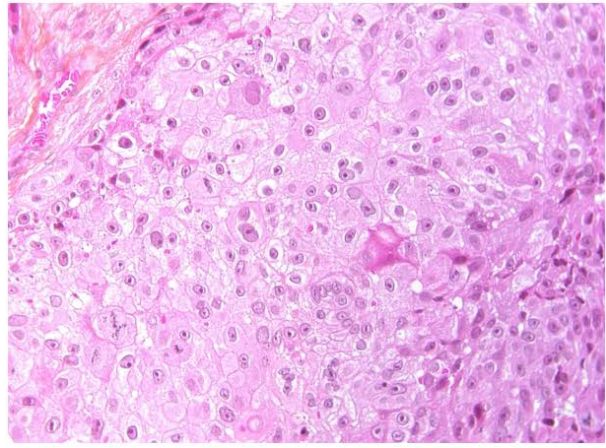
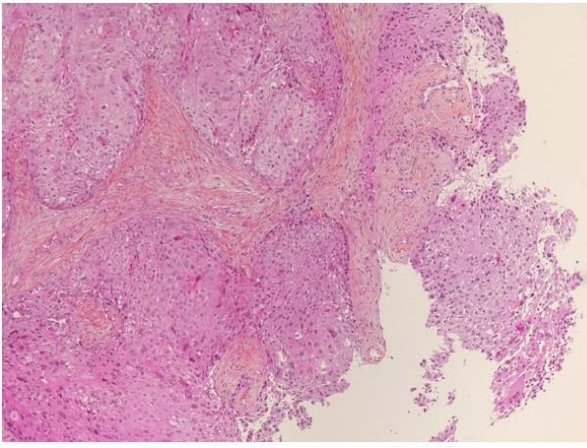


Figure 2A. H&E (10x) image of punch biopsy of ulcer on right middle finger. **Figure 2B.** H&E (40x) image showing large irregular cells with broad cytoplasm arranged in lobules

Case 2:

A 71-year-old patient was followed for prostate cancer treated by surgery and radiotherapy as well as locally advanced pancreatic cancer (adenocarcinoma) in treatment failure. He reported the presence, for several weeks, of a seeping ulcerated mass of the distal phalanx of his right little finger (Figure 3). A biopsy of this painful lesion revealed a mucinous adenocarcinoma compatible with a metastasis from his pancreatic cancer (Figure 4A, Figure 4B)

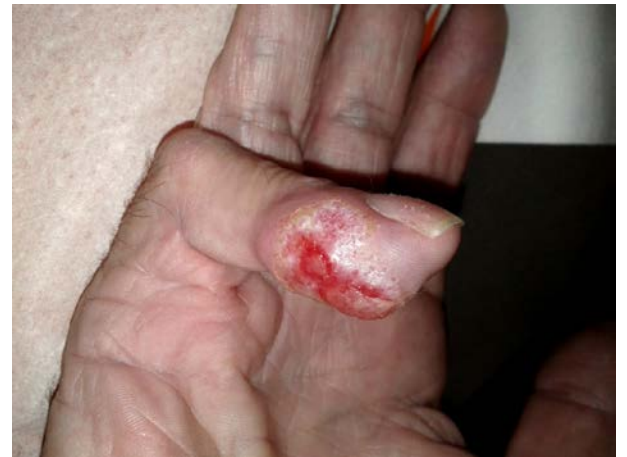

Figure 3. Painful malignant ulceration of the right little finger

A radiograph of the patient's two hands showed an extensive osteolytic lesion of the distal phalanx, with cortical bone erosion and soft tissue extension (Figure 5).

Both patients died one month after diagnosis of the acrometastases.

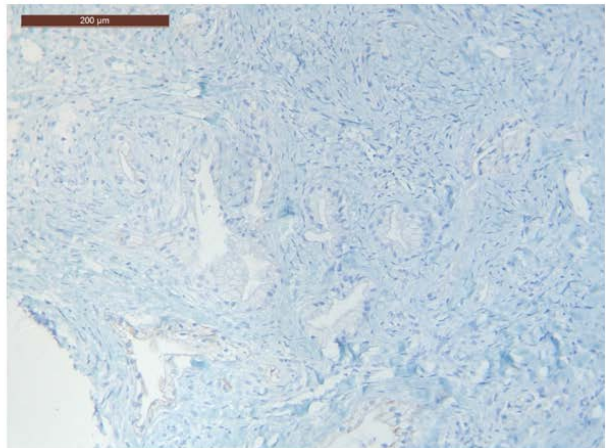
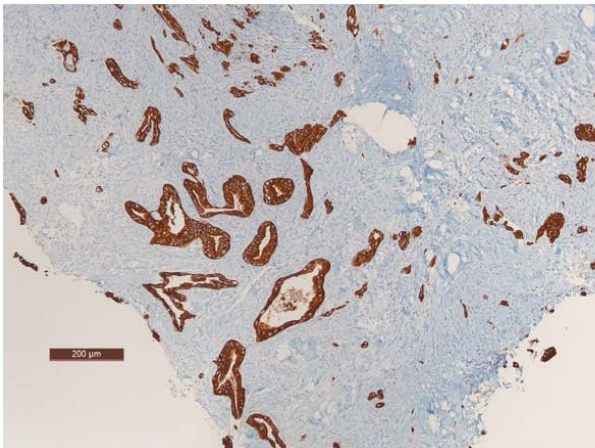
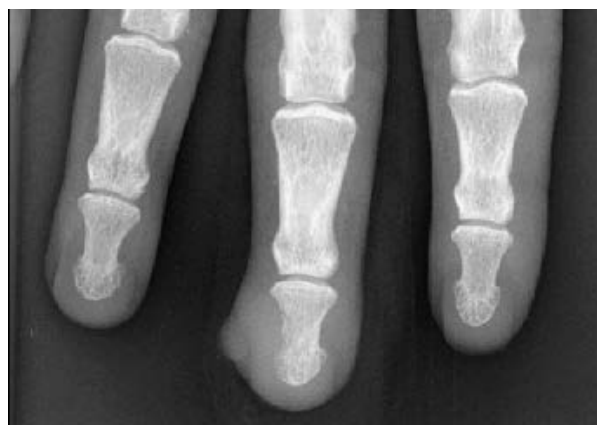

Figure 4A. cytokekeratin 7 expression detected showing mucinous adenocarcinoma. **Figure 2B.** no cytokekeratin 20 expression.



Discussion

In 75% of cases of skin metastases [1], the primary tumor is known (the skin lesion confirms the metastatic nature). Skin metastases, most commonly secondary to adenocarcinoma followed by undifferentiated carcinoma, are associated with a poor prognosis: twenty percent of patients die within one month of discovery of the metastasis; 45.5% die within six months; and 61.5% die within one year. Metastatic involvement of the upper extremities is rare with a reported incidence of 0.1%. Acrometastases are the first sign of an occult cancer in nearly 16% of cases [2].

Acrometastases are uncommon, except in the context of malignant melanoma. Men are almost twice as likely to experience acrometastasis as women. Acrometastases tend to affect the dominant hand. The middle finger and distal phalanx are the sites most commonly affected by bone metastases [3, 4].

Most lesions are isolated. Lung is the most common primary cancer site for acrometastasis reported the literature, followed by kidney cancer and breast cancer[5].Acrometastasis are synchronous with disseminated cancer (bone extension rather than organs) and are associated with a poor prognosis [4]. The patient usually has a life expectancy of six months to one year, as this malignancy often presents in an already debilitated patient [6].

The mechanism of acrometastases is unclear; many factors have been proposed, including trauma (introducing malignant cells into the bone via increased blood flow and the release of local chemotactic factors). Repeated trauma might reduce local tissue resistance explaining why the dominant hand is more frequently affected. Thermal imbalances, hemodynamic factors, lack of red marrow in adult small bones, and chemotactic factors have also been suggested [7, 8, 9]. These factors, including prostaglandins, promote cell migration and adhesion to bone, and may create a conduit for metastatic disease.

Acrometastasis are rare and associated with a poor prognosis. Treatment of the cancer, which is often delayed, is generally palliative (radiotherapy, surgery, pain palliation).

References

1. Schoenlaub, P., et al., [Survival after cutaneous metastasis: a study of 200 cases]. *Ann Dermatol Venereol*, 2001. 128(12): p. 1310-5. [PMID: 11908133]
2. Bigot, P., et al., [Isolated pain of the hand revealing a metastatic tumor of the hand. Report of a case]. *Chir Main*, 2007. 26(6): p. 300-2. [PMID: 18023234]
3. Ahlmann, E.R., et al., Unusual locations for metastatic malignancy of the hand: a report of three cases. *J Surg Orthop Adv*, 2008. 17(4): p. 267-70. [PMID: 19138500]
4. Flynn, C.J., et al., Two cases of acrometastasis to the hands and review of the literature. *Curr Oncol*, 2008. 15(5): p. 51-8. [19008991]
5. Healey, J.H., et al., Acrometastases. A study of twenty-nine patients with osseous involvement of the hands and feet. *J Bone Joint Surg Am*, 1986. 68(5): p. 743-6. [PMID: 3459730]
6. Tolo, E.T., W.P. Cooney, and D.E. Wenger, Renal cell carcinoma with metastases to the triquetrum: case report. *J Hand Surg Am*, 2002. 27(5): p. 876-81. [PMID: 12239679]
7. Robinson, K.P. and E. Hoppe, The development of blood-borne metastases. Effect of local trauma and ischemia. *Arch Surg*, 1962. 85: p. 720-4. [PMID: 13974455]
8. Long, L.S., et al., Lung cancer presenting as acrometastasis to the finger: a case report. *Case Rep Med*, 2010. 2010: p. 234289. [PMID: 20589088]
9. Gilardi, R., et al., Acrometastasis showing an occult lung cancer. *J Plast Surg Hand Surg*, 2013. 47(6): p. 550-2. [PMID: 23829505]