

**Photo Vignette**

**Zosteriform collagen nevus in a young boy**

**Ilteris Oguz Topal<sup>1</sup>, Gulcin Harman Kamali<sup>2</sup>, Sule Gungor<sup>1</sup>, Ozgur Emek Kocaturk Goncu<sup>1</sup>**

**Dermatology Online Journal 20 (8): 14**

**<sup>1</sup>Department of Dermatology, Okmeydani Training and Research Hospital**

**<sup>2</sup>Department of Pathology, Okmeydani Training and Research Hospital**

**Correspondence:**

Ilteris Oguz Topal

Department of Dermatology, Okmeydani Training and Research Hospital,  
Istanbul, Turkey

Telephone number: 0505 2973460

Fax number: 0212 221 7800

Email: drilteris@yahoo.com

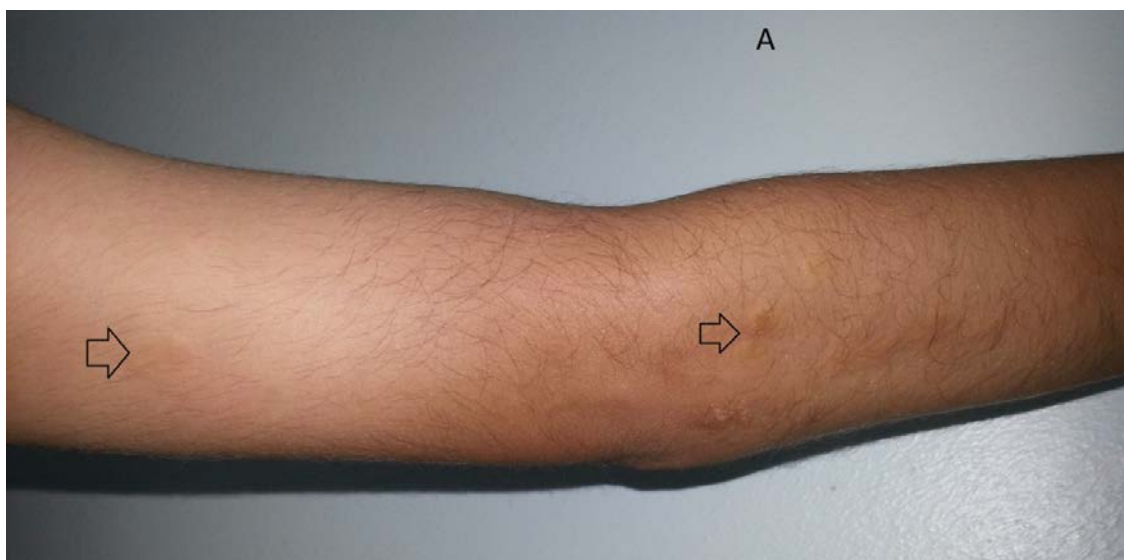
Email: drsulegungor@yahoo.com , kamaligulcin@yahoo.com, emekozgur@yahoo.com

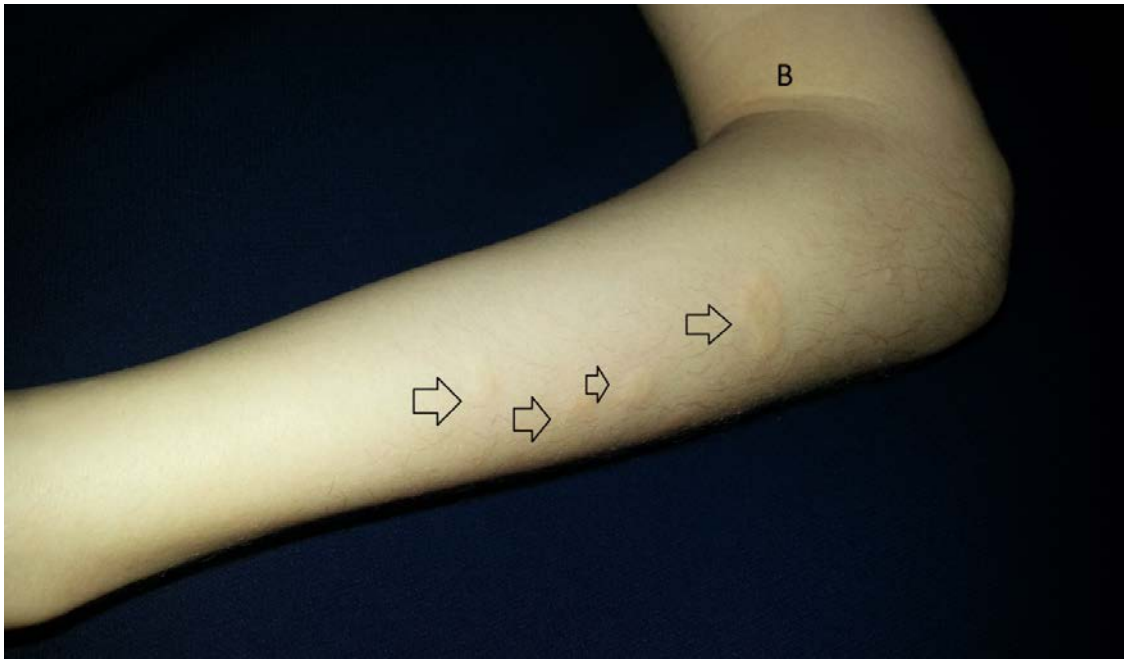
**Abstract**

Zosteriform connective tissue nevus is a rare kind of connective tissue nevi composed of collagen, elastin, or glycosaminoglycan, which was first reported by Steiner 1944. Herein, we report a young boy with a collagen nevus that presented in a zosteriform distribution.

**Case synopsis**

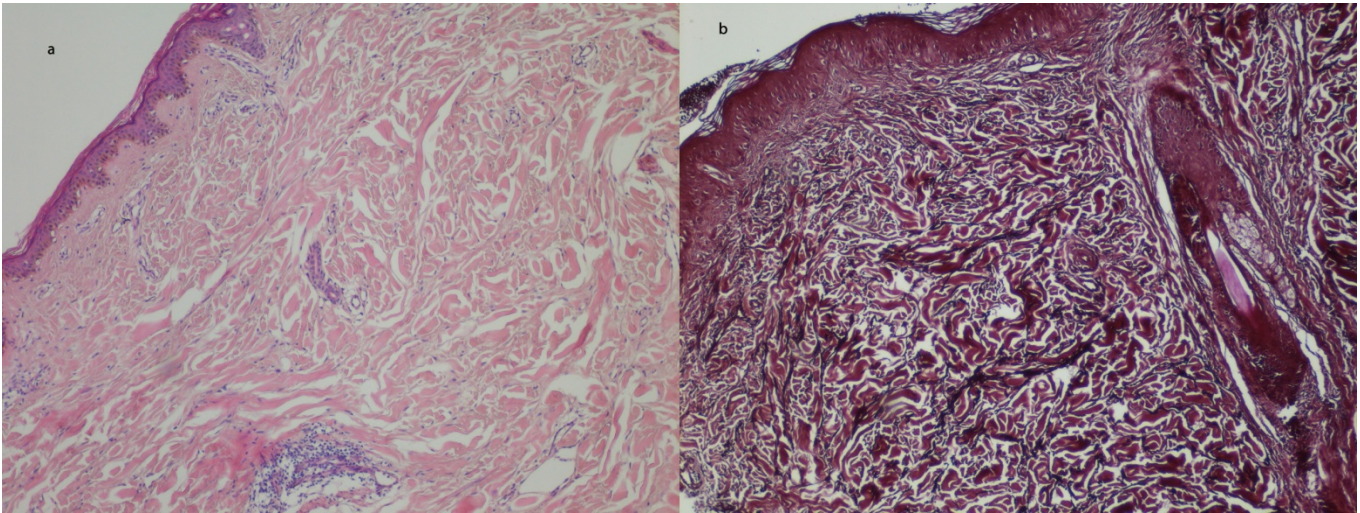
A 10-year-old boy presented with asymptomatic sclerotic papules and plaques over his right arm. The first lesion appeared approximately 1 year ago on the hand and had been gradually increasing in number and size. No other family members were similarly affected. His family had no history of tuberous sclerosis or consanguinity. The patient denied any history of viral infection, inflammation, wound, or trauma. The dermatological examination showed multiple firm, variably sized, skin-colored, cobblestone-like plaques on the right hand and arm within the C7 dermatome (Figure 1). The sizes of the plaques ranged from 2x3 mm to 0.5x1cm. Systemic examination and routine blood tests were normal. There was no evidence of osteopoikilosis or any other bony abnormality on radiographic examination of the hands, arms, legs, and pelvic bones.





**Figure 1.** Multiple sclerotic papules and plaques in a linear arrangement on the arm

Histopathological examination of a skin biopsy specimen showed increased, condensed collagen bundles in the dermis (Figure 2a). Furthermore, the elastic tissue stain demonstrated increased, fragmented elastic fibers in the mid-dermis (Figure 2b). Based on these clinical and histopathologic features, the diagnosis of zosteriform collagen nevus was made.



**Figure 2a.** Dense, coarse collagen bundles in the dermis (H&E,×100).

**Figure 2b.** Fragmented elastic fibers in the dermis (Orcein,×100).

Connective tissue nevi (CTN) are defined as hamartomatous malformations of dermal connective tissue components including collagen, elastin, or glycosaminoglycan. They may show either an increase, decrease, or normal range of elastic fibers, with an increase in collagen fibers [1]. The various clinical forms of the CTN, such as isolated, zosteriform, eruptive, giant cell, or papulolinear are often described and the zosteriform form is an extremely rare variant. To date, a few cases of zosteriform CTN have been reported in the English literature [2]. A zosteriform distribution was first reported in 1944 by Steiner, who described a unilateral distribution in a 5-year-old girl [2,3]. Kozminsky et al. described the second case of zosteriform CTN in a 23-year-old Nigerian woman [4].

Although some researchers consider zosteriform CTN and linear CTN to be the same entity, others think that the distribution of CTN in a linear arrangement is a separate entity, because the lesions are not distributed along dermatomes. Asano et al. reported a case of multiple CTN distributed as multiple linear streaks along Blaschko lines [3]. Dubiel et al. also described another case with ivory-colored papules and plaques in a Blaschko-linear arrangement extending from beneath the right buttock to the calf [2].

The pathogenesis of CTN has not been elucidated so far. However, linear CTN is thought to be caused by a mutation in tumor suppressor genes such as TSC-1 or TSC-2. Thus, the distribution of CTN in a linear arrangement is likely to actually be along Blaschko lines [3].

The present case is an example of this rare non-familial collagen nevus in zosteriform distribution that involved the C7 dermatome. We did not find any associated diseases such as familial cutaneous collagenoma, tuberous sclerosis complex (TSC), Buschke-Ollendorff syndrome, or osteopoikilos in our patient or in his family members. Therefore, we believe that zosteriform CTN should be considered as a separate entity from the other clinical types of CTN.

## References

1. Choi YJ, Lee SJ, Choi CW, Kim WS, Lee GY. Multiple Unilateral Zosteriform Connective Tissue Nevi on the Trunk. *Ann Dermatol.* 2011 Oct;23(Suppl 2):S243-6. [PMID:22148061]
2. Dubiel W, Kiehlmann I, Happle R. Linear Collagen Naevus: An Unusual Connective Tissue Disorder. *Acta Derm Venereol.* 2014 May 6;94(3):361-362. [PMID:24158457]
3. Asano Y, Ihn H, Tamaki K. Linear connective tissue nevus. *Pediatr Dermatol.* 2007 Jul-Aug;24(4):439-41. [PMID:17845185]
4. Kozminsky ME, Bronson DM, Barsky S. Zosteriform connective tissue nevus. *Cutis.* 1985 Jul;36(1):77-8. [PMID:4017659]