

# Mycophenolate mofetil as a successful therapy for idiopathic granulomatous mastitis

Fan Di Xia<sup>1</sup>, AB, Amy Ly<sup>2</sup> MD, Gideon P Smith<sup>3</sup> MD PhD

Affiliations: <sup>1</sup>Harvard Medical School, Boston, Massachusetts, <sup>2</sup>Department of Pathology, Massachusetts General Hospital, Harvard Medical School, Boston, Massachusetts, <sup>3</sup>Department of Dermatology, Massachusetts General Hospital, Boston, Massachusetts

Corresponding Author: Fan Di Xia, AB, Harvard Medical School, 25 Shattuck St., Boston, MA, 02115, Email: fandi\_xia@hms.harvard.edu

## Abstract

Idiopathic granulomatous mastitis (IGM) is a benign chronic inflammatory breast disease of unknown etiology. No consensus exists as to the best therapeutic approach, though treatment choices include antibiotics, drainage, surgical excision, steroids, methotrexate, and observation. Herein we report a case of idiopathic granulomatous mastitis that was refractory to methotrexate and intralesional and systemic steroids but responded well to mycophenolate mofetil 1500mg twice daily. To our knowledge, this is the first report of the effective use of mycophenolate mofetil in idiopathic granulomatous mastitis.

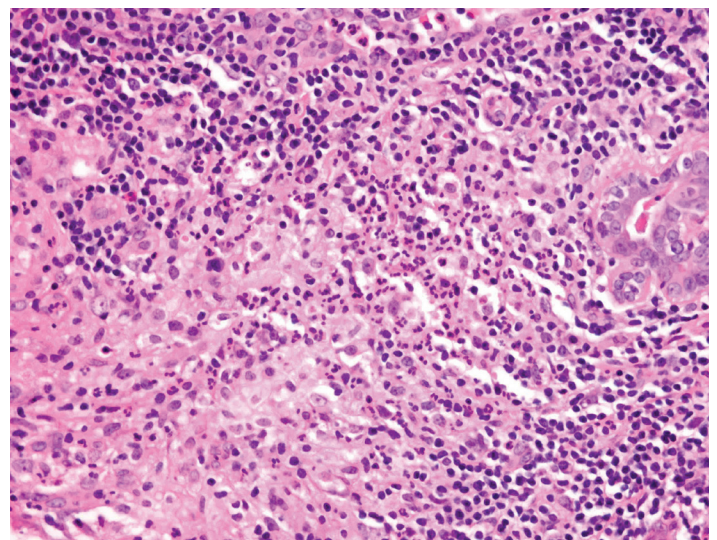
*Keywords: mycophenolate mofetil, idiopathic granulomatous mastitis*

## Introduction

Idiopathic granulomatous mastitis (IGM) is a benign chronic inflammatory breast disease of unknown etiology. Various treatments have been tried for IGM, though there is no consensus as to the best therapeutic approach. Herein we present a case of mycophenolate mofetil as a successful therapy for IGM.

## Case Synopsis

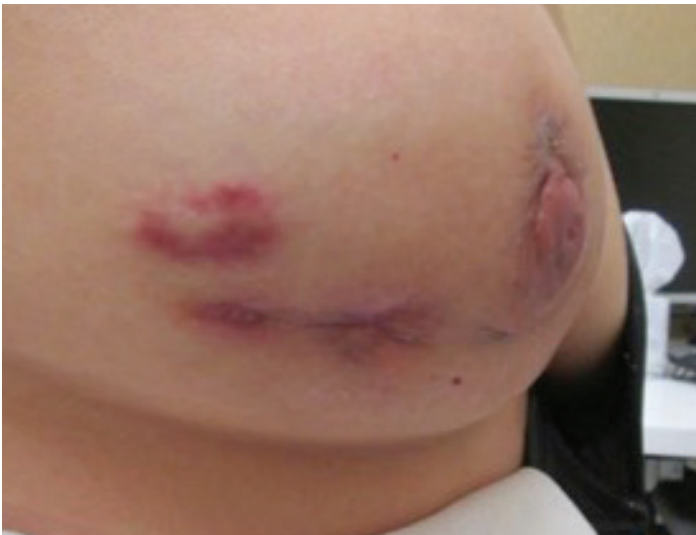The patient is a 40-year-old woman who was referred to the rheumatology-dermatology clinic for evaluation and treatment of idiopathic granulomatous mastitis. The patient initially presented with a breast lump that was followed by the surgical oncology department



**Figure 1.** Granulomatous mastitis, pathology. Granulomatous mastitis. Acute and chronic inflammation with focal collections of neutrophils.

with diagnostic mammogram revealing a 5cm solid lesion with enlarged lymph nodes. Core biopsies were performed and demonstrated chronic mastitis with multiple granulomas, giant cells, and microabscess formation without evidence of malignancy; Fite, acid-fast bacilli, and Grocott's Methenamine Silver stain were negative (**Figure 1**). The patient was treated with cephalexin and clindamycin without response.

At the time of consultation at the rheumatology-dermatology clinic, the patient demonstrated a mildly tender erythematous nodule without fluctuance or drainage, present intermittently for the past two months on the right breast (**Figure 2**). In addition, the patient reported fatigue, arthralgias without swelling in the knees, ankles, and thumb carpometacarpal (CMC) joints bilaterally, morning stiffness lasting



**Figure 2.** *Granulomatous mastitis, clinical. Erythematous nodule on the right breast of the patient, with core biopsy demonstrating chronic mastitis.*

approximately 1 hour; she demonstrated two tender hyperpigmented nodules on the right anterior legs measuring 2x3cm and 1cm in diameter, respectively. Musculoskeletal exam demonstrated tenderness to palpation at the ankles and first CMC joints without evidence of synovitis.

The differential diagnosis clinically and histologically included sarcoidosis, tuberculosis, other infection, rheumatoid arthritis, and idiopathic granulomatous mastitis. As such, workup included a chest X-ray (CXR), angiotensin converting enzyme (ACE) levels, and serum calcium to rule out sarcoidosis, antinuclear antibody (ANA), rheumatoid factor (RF), and anti-cyclic citrullinated peptide (anti-CCP) antibody to rule out rheumatoid arthritis, T-Spot interferon-gamma release assay to rule out tuberculosis, and erythrocyte sedimentation rate (ESR) and C-reactive protein (CRP) to assess for degree of inflammation. An ophthalmology evaluation was performed to rule out subclinical eye inflammation. Tissue culture was not performed, but Fite, GMS, and AFB staining had been negative on pathology. A prolactin level was also pursued as hyperprolactinemia has been reported in idiopathic granulomatous mastitis. All above-mentioned workup returned within normal limits (CXR: clear lungs without abnormal findings, ACE: 40 U/L, serum calcium: 9.5mg/dL, RF: <30 IU/ml, anti-CCP: 9 units, T-SPOT interferon-gamma release assay: negative) with the exception of a positive ANA at 1:40, a mildly elevated CRP at 21.1 mg/L, and an

ESR at 38 mm/hr. On pathology, the granulomas seen did not resemble sarcoid granulomas, which typically were more compact and well-formed with more widely-distributed neutrophilic inflammation if present at all.

As such, a diagnosis of idiopathic granulomatous mastitis was made. A trial of methotrexate 15mg weekly and folic acid 1mg PO daily was started without adequate effect and the methotrexate was increased to 30mg with the addition of a prednisone 30mg taper. The patient still experienced mastitis flares with drainage on this regimen and the decision was made to switch methotrexate to mycophenolate mofetil 1000mg twice daily. The mycophenolate was subsequently increased to 1500mg twice daily with the addition of intralesional injections of triamcinolone acetonide 0.5mg as needed for flares, which became rare at approximately every 4-6 months and subsequently absent completely. The patient had healing of the breast nodule and resolution of tenderness, inflammation, and arthralgia, which would recur, however, if the mycophenolate mofetil was missed for more than a few days. Should the patient be able to maintain the improvement, she will undergo a taper of the mycophenolate mofetil.

## Case Discussion

Idiopathic granulomatous mastitis (IGM), also known as idiopathic granulomatous lobular mastitis, is a rare, benign chronic inflammatory breast disease of unknown etiology, most often seen in parous young females within a few years after pregnancy [1-2]. The condition presents clinically with peripheral inflammatory breast masses, nodules, or ulcerations, with or without repeated abscess formation [3]; this, may also be accompanied by peau d'orange skin changes, nipple retraction, and sinus tract formations [4]. Mammographic findings may mimic those of breast cancer. The diagnosis of IGM requires a core needle biopsy showing noncaseous granulomas, as well as the ruling out of other conditions that may also demonstrate noncaseating granulomas such as tuberculosis, mycoses, sarcoidosis, and vasculitis [3].

Various treatments have been tried for IGM, though there is no current consensus as to the best therapeutic approach. Treatment choices include antibiotics and drainage, surgical excision, steroids,

methotrexate, and observation, with the goal of minimizing recurrence while achieving good aesthetic results [5]. Without treatment, IGM is self-limiting and resolves in approximately 9-12 months [6]. IGM associated with abscess formation may require antibiotics and drainage. Surgical excision of IGM is not suggested owing to slow wound healing, poor aesthetic outcome from repeated re-excisions, and a high recurrence rate ranging from 16-50% [1]. Corticosteroid therapy has been used often for IGM based on the hypothesis that IGM is an autoimmune process, and retrospective studies have demonstrated the efficacy of steroids in controlling lesion sizes [1, 5, 7]. The use of methotrexate 7.5-15mg has been reported in the successful treatment of IGM, though discontinuation has been associated with recurrence of the inflammation [8].

To our knowledge, our case is the first case report demonstrating efficacy of mycophenolate mofetil in treating IGM. Our patient presented with severe IGM that was refractory to treatment with methotrexate 30mg and prednisone 30mg but was controlled with mycophenolate mofetil 1500mg twice daily. Although intralesional injection of triamcinolone acetonide was also given as needed for flares, which were rare and subsequently absent, mycophenolate mofetil was the agent that controlled the disease activity as demonstrated by the recurrence of symptoms if mycophenolate mofetil was missed for more than a few days by the patient. The efficacy of mycophenolate mofetil in treating IGM further supports the possible autoimmune etiology of IGM. Interestingly, the patient also presented with extramammary involvement of arthritis and likely erythema nodosum as evidenced by her anterior leg nodules. These are also suggestive of underlying autoimmunity, which is a known trigger for IGM [3]. Further work is needed to better characterize the link between extramammary manifestation of autoimmunity and IGM.

## Conclusion

We report, to our knowledge, the first report of the successful use of mycophenolate mofetil in the treatment of refractory IGM.

## References

1. Gurleyik, G, Aktekin, A, Aker, F, Karagulle, H, Saglamc, A. Medical

- and surgical treatment of idiopathic granulomatous lobular mastitis: a benign inflammatory disease mimicking invasive carcinoma. *Journal of breast cancer*, 2012 Mar;15(1), 119-123. [PMID: 22493638].
2. Al-Khaffaf, B, Knox, F, Bundred, N.J. Idiopathic granulomatous mastitis: a 25-year experience. *Journal of the American College of Surgeons*, 2008 Feb;206(2), 269-273. [PMID: 18222379].
  3. Altintoprak F, Karakece E, Kivilcim T, Dikicier E, Cakmak G, Celebi F, Ciftci IH. Idiopathic granulomatous mastitis: an autoimmune disease? *The Scientific World Journal*. 2013 Sep;2013. [PMID: 24082849].
  4. Kessler E, Wolloch Y. Granulomatous mastitis: a lesion clinically simulating carcinoma. *American journal of clinical pathology*. 1972 Dec;58(6):642-6. [PMID: 4674439].
  5. Hur SM, Cho DH, Lee SK, Choi MY, Bae SY, Koo MY, Kim S, Choe JH, Kim JH, Kim JS, Nam SJ. Experience of treatment of patients with granulomatous lobular mastitis. *Journal of the Korean Surgical Society*. 2013 Jul;85(1):1-6. [PMID: 23833753].
  6. Bouton ME, Jayaram L, O'Neill PJ, Hsu CH, Komenaka IK. Management of idiopathic granulomatous mastitis with observation. *The American Journal of Surgery*. 2015 Aug;210(2):258-62. [PMID: 25746911].
  7. Sheybani F, Sarvghad M, Naderi H, Gharib M. Treatment for and clinical characteristics of granulomatous mastitis. *Obstetrics & Gynecology*. 2015 Apr;125(4):801-7. [PMID: 25751209].
  8. Akbulut S, Arikanoğlu Z, Senol A, Sogutcu N, Basbug M, Yeniars E, Yagmur Y. Is methotrexate an acceptable treatment in the management of idiopathic granulomatous mastitis?. *Archives of gynecology and obstetrics*. 2011 Nov 1;284(5):1189-95. [PMID: 21207047].