

Case presentation

Pseudo-kaposi sarcoma (acroangiodermatitis): occurring after bullous erysipelas

Zekayi KUTLUBAY¹, Gürkan YARDIMCI¹, Burhan ENGİN¹, Cuyan DEMİRKESEN², Övgü AYDIN², Rashid KHATİB³, Yalçın TUZUN¹

Dermatology Online Journal 21 (5): 5

¹Istanbul University, Cerrahpaşa Medical Faculty, Department of Dermatology, İstanbul, Turkey.

²Istanbul University, Cerrahpaşa Medical Faculty, Department of Pathology, İstanbul, Turkey.

³Private working dermatologist, İstanbul, Turkey

Correspondence:

Zekayi Kutlubay
1 İstanbul University
Cerrahpaşa Medical Faculty
Department of Dermatology
İstanbul, Turkey
zekayikutlubay@hotmail.com

Abstract

Pseudo-Kaposi sarcoma is a benign reactive vascular proliferative disorder, which can be seen at any age. It occurs when the chronic venous pressure changes result in vascular proliferation in the upper and mid dermis. This disease is divided into two subtypes: the most frequent subtype is the Mali type and seen in early ages. The Mali type is seen in chronic venous insufficiency and in those patients with arteriovenous shunts. The rare subtype is the Stewart-Bluefarb type. This disease must be distinguished from Kaposi sarcoma because of their clinical resemblance. Herein, we present a patient with pseudo-Kaposi sarcoma, which developed after bullous erysipelas.

Key Words. Pseudo-Kaposi's sarcoma, Acroangiodermatitis, Bullous erysipelas

Case synopsis

A 56-year-old woman presented with skin lesions located on the left lower extremity, which had occurred two months prior. She had been diagnosed with bullous erysipelas on the left lower extremity 3 months before. Her erythrocyte sedimentation rate was 60 mm/hr, leucocyte count was 12.000/mm³, and anti-streptolysin O (ASO) titre was 500 U. She was treated with systemic antibiotics (intravenous ampicillin 8g/day, for 17 days and then po amoxicillin clavulanic acid 2 g/day for 10 days). Two weeks later, the erysipelas was markedly improved. Her elevated laboratory findings began to decrease. One month after the treatment, development of a new type of skin lesion was noted at the same site.

Upon dermatologic examination, red-brown papules and large, reddish, sharply limited plaques were detected on the left lower extremity (Figure 1). Plaques were present mainly below the knee, on the lower portion of the leg, and the dorsal area of the feet. However papules were located on the medial upper side of the knee (Figure 2). Moderate induration by palpation was recorded.

On the left lower extremity, edema was evident so that the right and left lower extremity had a significant diameter. There was no ulcer or erosion on the surface of the lesions and no temperature difference between the legs. Lymphadenopathy was not detected clinically. Routine blood chemistry was normal. Serological tests for HIV, and hepatitis B and C virus infections were negative. HHV8-DNA was not detected with PCR.. Venous system Doppler ultrasound evaluation of the left lower extremity was normal and no arteriovenous malformations, arteriovenous shunts, or chronic venous insufficiency were found.

We performed a skin biopsy from a reddish plaque on the left leg. Histopathological examination revealed prominent vascular proliferation in the upper dermis, together with fibroblastic activity, hemosiderin-laden macrophages, extravasated red blood cells, a mixed perivascular infiltrate, and edema (Figures 3, 4).

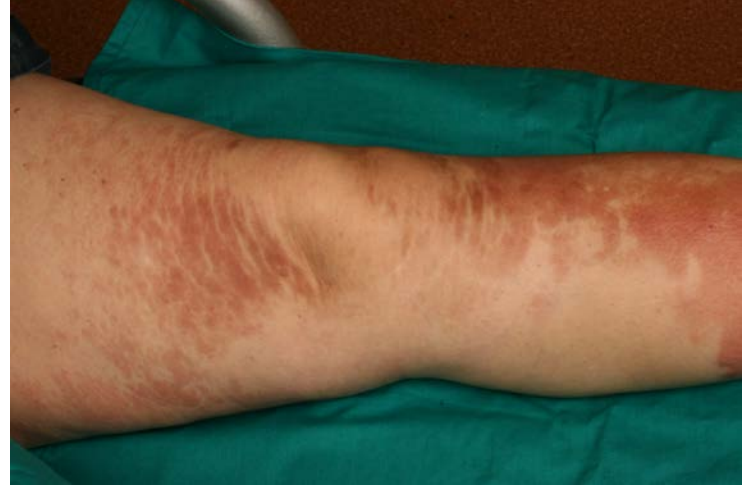
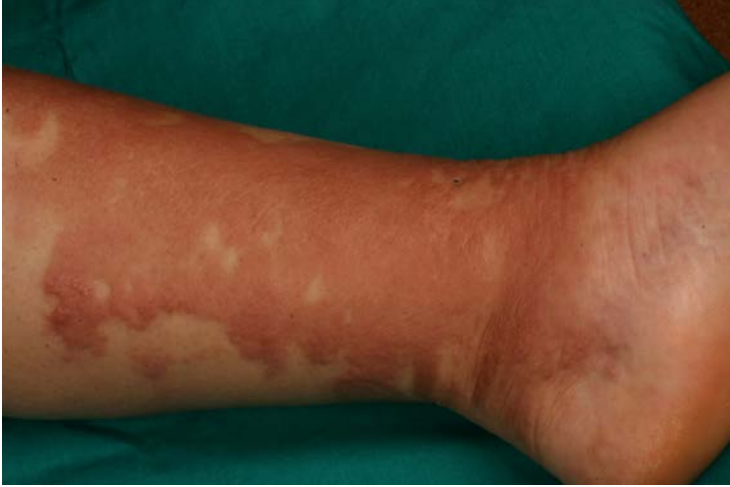
Figure 1. Confluent, red, edematous plaques. **Figure 2.** Note the unilateral plaques suggesting an underlying venous stasis.

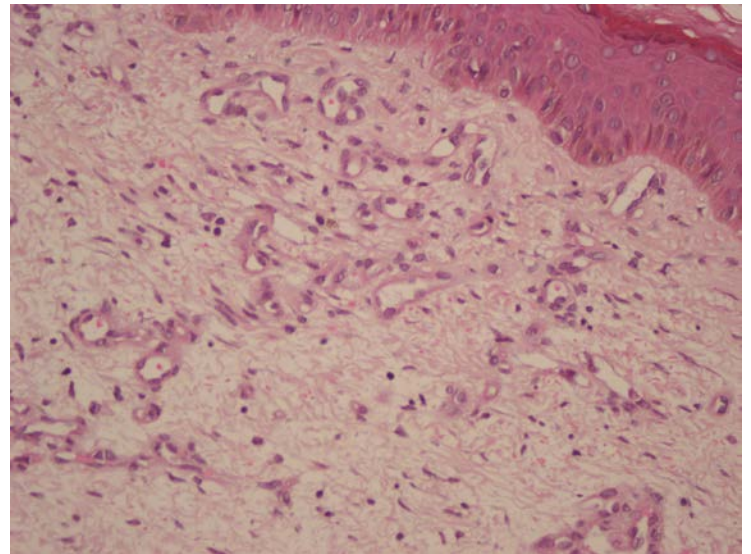
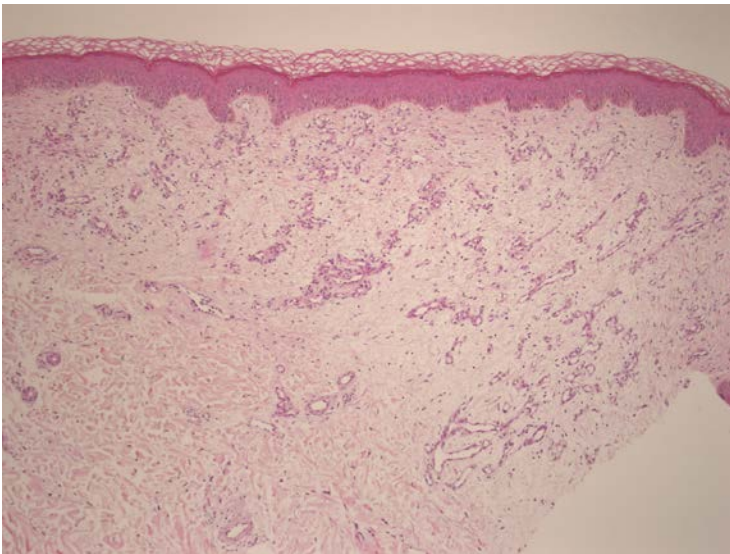


Figure 3. There is marked proliferation of vessels in a lobular pattern in the upper dermis (x 100). **Figure 4.** Endothelial cells lining vascular spaces are round or oval and do not show any atypia. Extravasated erythrocytes, hemosiderin laden macrophages, and a few lymphocytes are also present (x 400).

Discussion

“Pseudo-Kaposi sarcoma” is another name for acroangiodermatitis, which was first described by *Earhart et al.* in 1974 [1, 2]. *Mali et al* first reported Kaposi-like lesions associated with chronic vascular insufficiency in patients in 1965. In 1967, *Bluefarb and Adams* described the same condition in a patient who had congenital vascular malformation [3]. Pseudo-Kaposi sarcoma is a benign reactive vascular proliferative disorder [4] in which the clinical appearance is variable and includes red-violaceous, brown macules, papules, nodules, or plaques on the lower extremities [1, 5]. The lesions may become verrucous or ulcerated. We did not detect a verrucous or ulcerated appearance in our case. It can be seen rarely in children [5, 6]. In most of the cases, vascular abnormalities such as chronic venous insufficiency, congenital arteriovenous malformation, or Klippel-Trenaunay syndrome [7] accompanied the lesions.

Furthermore, other conditions such as limb paralysis, amputation, and suction-socket lower limb prosthesis have been reported as causes [5, 8]. Two types of pseudo-Kaposi sarcoma have been described in textbooks: Mali and Stewart-Bluefarb types [1]. The Mali type is the most frequent subtype of pseudo-Kaposi sarcoma. It is associated with chronic venous insufficiency and is more common in male patients. Most of the cases occur in adults [4]. The lesions are usually bilateral and present with long-term stasis dermatitis [2]. The Stewart-Bluefarb subtype presents earlier unilaterally and is usually associated with congenital arteriovenous malformation [3, 5]. Acroangiokeratosis has been described in some situations [9] such as in amputees [4], in patients with paralyzed legs [10], in patients undergoing hemodialysis (from arteriovenous shunts distally) [7, 11], in association with hepatitis C, in chronic venous insufficiency, in vascular malformations (eg, Klippel-Trenaunay syndrome [12], Stewart-Bluefarb syndrome [3], Prader-Labhart-Willi syndrome), and in protein-C deficiency [13]. In our patient edema and increased venous pressure developed after bullous erysipelas.

The pathogenesis of Pseudo-Kaposi sarcoma is not fully understood. Vascular endothelial growth factor has been suggested to play a role in development. It is thought that endothelial proliferation occurs in the distal hypoxic areas [14]. There could be hypoxia related to edema and venous stasis in our patient. Mast cells may also play an important role in the hypoxic areas [3].

Pseudo-Kaposi sarcoma must be distinguished from conventional Kaposi sarcoma both clinically and histologically. Vascular hyperplasia results from hyperplasia of preexisting vasculature in pseudo-Kaposi sarcoma, as in our case. On the other hand, in Kaposi sarcoma, vascular proliferation is independent from the underlying normal vasculature. In addition, fibroblastic activity accompanies vascular proliferation in pseudo-Kaposi sarcoma and the vessels are rounded instead of jagged in appearance. The growth pattern is lobular in contrast to the irregular pattern of vascular spaces dissecting the dermal collagen seen in Kaposi sarcoma. Unlike Kaposi sarcoma, vessels of pseudo-Kaposi sarcoma do not express HHV-8, as in our case [3, 8]. There is no CD34 expression in perivascular cells in these lesions. Still, factor VIII-associated antigen is present in pseudo-Kaposi sarcoma lesions [3, 4].

Some complications such as bone demineralization or invasion, infection of the site, hemorrhage, extremity hypertrophy, congestive cardiac failure, ulceration, pain, and recently described pincer nail deformity secondary to an artificial arteriovenous hemodialysis fistula can be seen [3, 4, 6, 7].

We treated our patient with limb elevation and compression elastic bandages. Treatment alternatives consist of conservative and surgical procedures, including limb elevation, compression bandages, wound care, selective embolization, surgical ligation, and amputation [3, 4, 6]. Infection of the compromised extremity must be prevented. Erythromycin may be used [4]. A 3-month-course of dapsone (50 mg PO bid) combined with leg elevation and elastic support stockings led to complete regression of the lesions in one patient [9]. Partial amputation may be necessary when serious complications such as hemorrhage, refractory pain, recurrent infection, necrosis formation, physical impairment of the extremity, cardiac decompensation, and unresponsiveness to conservative treatment develops [3, 6]. Surgical treatments can increase the morbidity [3]. Anticoagulant therapy is useful in patients with thrombophilic alterations [4]. Laser ablation like pulsed-dye laser can also treat acroangiokeratosis [1].

References

1. Rongioletti F, Rebora A. Cutaneous reactive angiomatoses: patterns and classification of reactive vascular proliferation. *J Am Acad Dermatol* 2003; 49: 887-896. [PMID: 14576670]
2. Kapdağlı H, Gündüz K, Oztürk G, Kandiloğlu G. Pseudo-Kaposi's sarcoma (Mali type). *Int J Dermatol* 1998; 37: 223-225. [PMID: 9556115]
3. Agrawal S, Rizal A, Agrawal CS, Anshu A. Pseudo-Kaposi's sarcoma (Bluefarb-Stewart type). *Int J Dermatol* 2005; 44: 136-138. [PMID: 15689214]
4. Trindade F, Requena L. Pseudo-Kaposi's sarcoma because of suction-socket lower limb prosthesis. *J Cutan Pathol* 2009; 36: 482-485. [PMID: 19278437]
5. Doğan S, Boztepe G, Karaduman A. Pseudo-Kaposi sarcoma: a challenging vascular phenomenon. *Dermatol Online J* 2007; 13: 22. [PMID: 18328216]
6. Larralde M, Gonzalez V, Marietti R, Nussembaum D, Peirano M, Schroh R. Pseudo-Kaposi sarcoma with arteriovenous malformation. *Pediatr Dermatol* 2001; 18: 325-327. [PMID: 11576408]
7. Hwang SM, Lee SH, Ahn SK. Pincer nail deformity and pseudo-Kaposi's sarcoma: complications of an artificial arteriovenous fistula for haemodialysis. *Br J Dermatol* 1999; 141: 1129-1132. [PMID: 10606867]
8. Körber A, Dissemond J. Pseudo-Kaposi sarcoma. *Intern Med J* 2006; 36: 535. [PMID: 16866662]
9. <http://emedicine.medscape.com/article/1085635-overview>
10. Landthaler M, Langehenke H, Holzmann H, Braun-Falco O. [Mali's acroangiokeratosis (pseudo-Kaposi) in paralyzed legs]. *Hautarzt*. May 1988; 39: 304-7. [PMID: 3403265]

11. Kim TH, Kim KH, Kang JS, Kim JH, Hwang IY. Pseudo-Kaposi's sarcoma associated with acquired arteriovenous fistula. *J Dermatol*. Jan 1997; 24: 28-33. [PMID: 9046737]
12. Lyle WG, Given KS. Acroangiokeratosis (pseudo-Kaposi's sarcoma) associated with Klippel-Trenaunay syndrome. *Ann Plast Surg*. Dec 1996; 37: 654-6. [PMID: 8988782]
13. Wei-Min Tan A, Lee JS, Pramono ZA, Chong WS. Acroangiokeratosis of Mali in protein C deficiency due to a novel PROC gene mutation. *Am J Dermatopathol*. 2012; 34: e19-21. [PMID: 22441373]
14. Ikeda, Kano E, Baba S, Suzuki H. Mast cells in pseudo-Kaposi's sarcoma lesions. *J Eur Acad Dermatol Venereol* 2001; 15: 487-489. [PMID: 11763401]