

**Case presentation**

**Scurvy in the present times: vitamin c allergy leading to strict fast food diet**

**Tarek Shaath MD<sup>1</sup>, Ryan Fischer MD<sup>2</sup>, Megan Goeser MD<sup>3</sup>, Anand Rajpara MD<sup>2</sup>, Daniel Aires MD<sup>2</sup>**

**Dermatology Online Journal 22 (1): 10**

**<sup>1</sup>Massachusetts General Hospital, Boston, MA 02144**

**<sup>2</sup>Division of Dermatology, University of Kansas Medical Center, Kansas City, KS 66103**

**<sup>3</sup>Oregon Health & Science University, Portland, OR 97239**

**Correspondence:**

Daniel Aires  
Division of Dermatology, Director  
University of Kansas Medical Center  
3901 Rainbow Blvd  
MS 2025  
Kansas City, KS 66160  
daires@kumc.edu  
913-588-3840

---

**Abstract**

Scurvy results from a deficiency of vitamin C, a nutrient otherwise known as ascorbic acid. Today, scurvy is rare yet emerges in select patients. The patient reported herein developed scurvy secondary to deliberate avoidance of vitamin C-rich foods. Classic cutaneous manifestations of scurvy include follicular hyperkeratosis and perifollicular hemorrhage encompassing coiled “corkscrew” hairs and hairs bent into “swan-neck” deformities. Ecchymoses, purpura, and petechiae are also characteristically prominent. Classic oral abnormalities include erythematous, swollen gingivae that hemorrhage from subtle microtrauma. Subungual linear splinter hemorrhages may also manifest as a sign of the disease.

To establish the diagnosis requirements include characteristic physical exam findings, evidence of inadequate dietary intake, and rapid reversal of symptoms upon supplementation. Although unnecessary for diagnosis, histological findings demonstrate perifollicular inflammation and hemorrhage, fibrosis, and hyperkeratosis, amongst dilated hair follicles and keratin plugging.

Although citrus fruit allergies have been historically documented, ascorbic acid has not been previously reported as an allergen. Although lacking absolute certainty, this report suggests a presumed case of ascorbic acid allergy based on patient history and favorable response to ascorbic acid desensitization therapy.

**Keywords: Scurvy, Vitamin C, Ascorbic Acid, Deficiency, Allergy, Desensitization, Diet**

**Introduction**

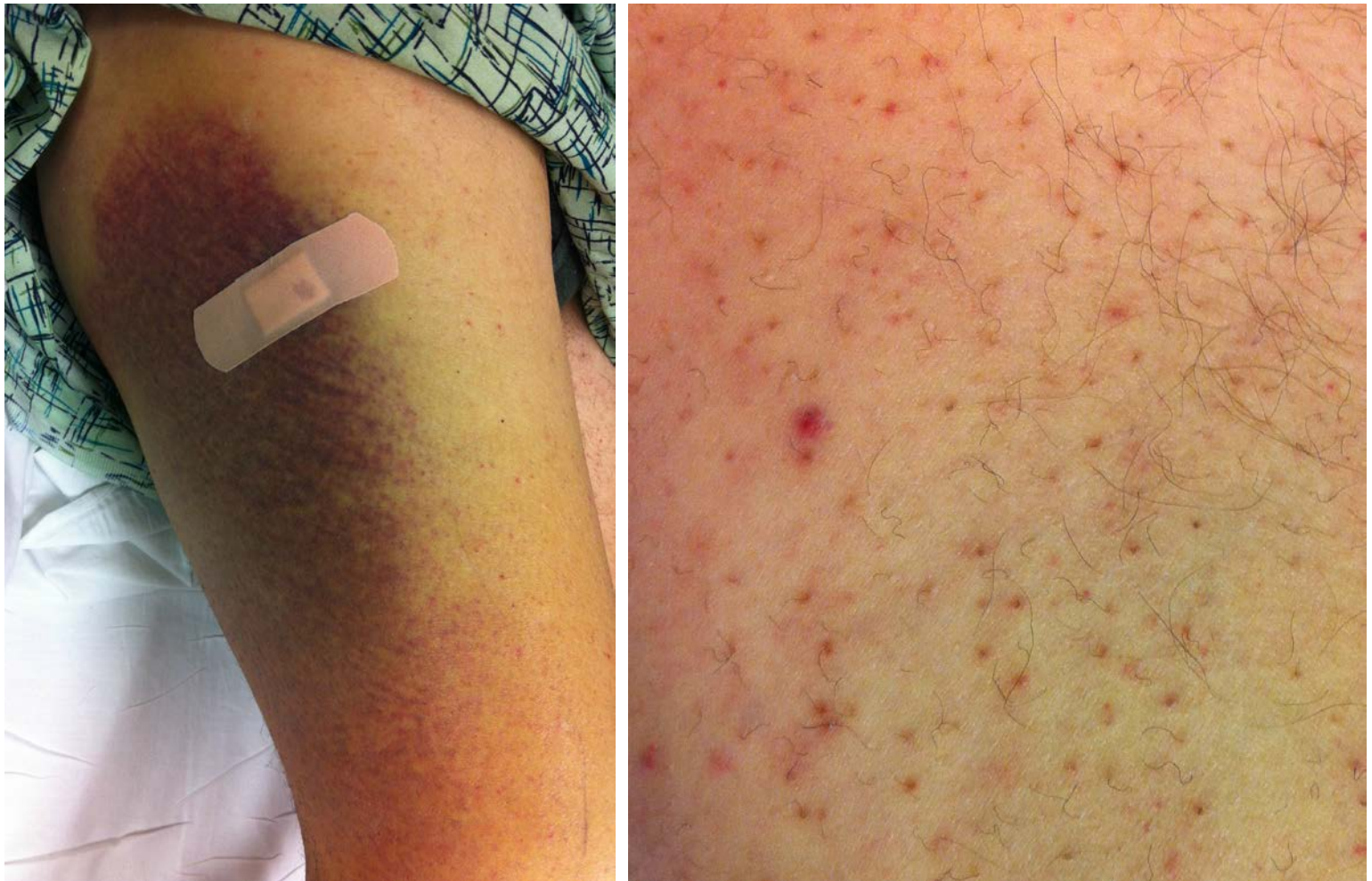Vitamin C deficiency, classically referred to as the clinical syndrome scurvy, is a nutritional deficiency once prevalent in older eras and now uncommonly observed in today's world. The low prevalence of scurvy can be attributed to the vitamin-enriched food systems of western civilization. Yet despite the modernization of food products, scurvy may emerge in individuals restricted to

unvaried diets of nutritionally-poor foods. A protracted course of such diets may induce and exacerbate the signs and symptoms of scurvy. Global symptoms, generalized hemorrhaging, and specific cutaneous findings may lead the clinician to suspect scurvy as a diagnosis. We report an infrequent case of scurvy in the present times, in an individual whose diet consisted primarily of fast food.

## Case synopsis

A 51 year-old man with a history of poor dentition presented to the emergency department with a two-day history of right leg swelling, pain, ecchymoses, and purpura. The patient reported a three-month history of bilateral lower extremity petechiae. Upon further questioning, the patient disclosed a distant history of hives within an hour of ingesting oral ascorbic acid supplements. This allergic phenomenon occurred on multiple occasions during the patient's third and fourth decades of life, upon ingestion of two distinctly separate formulations of ascorbic acid preparations. The hives resolved after self-administration of Benadryl on all occasions. Additionally, he reported the development of hives after consuming oranges during childhood, drinking orange soda as a teenager, and after exposure to orange peel zest. He never developed angioedema, difficulty breathing, or anaphylaxis during any allergic episodes. Skin prick testing by his childhood allergist revealed reactivity to oranges. The patient's diet consisted primarily of fast foods, with a complete lack of fruits and vegetables owing to deliberate elimination of vitamin C-rich foods.

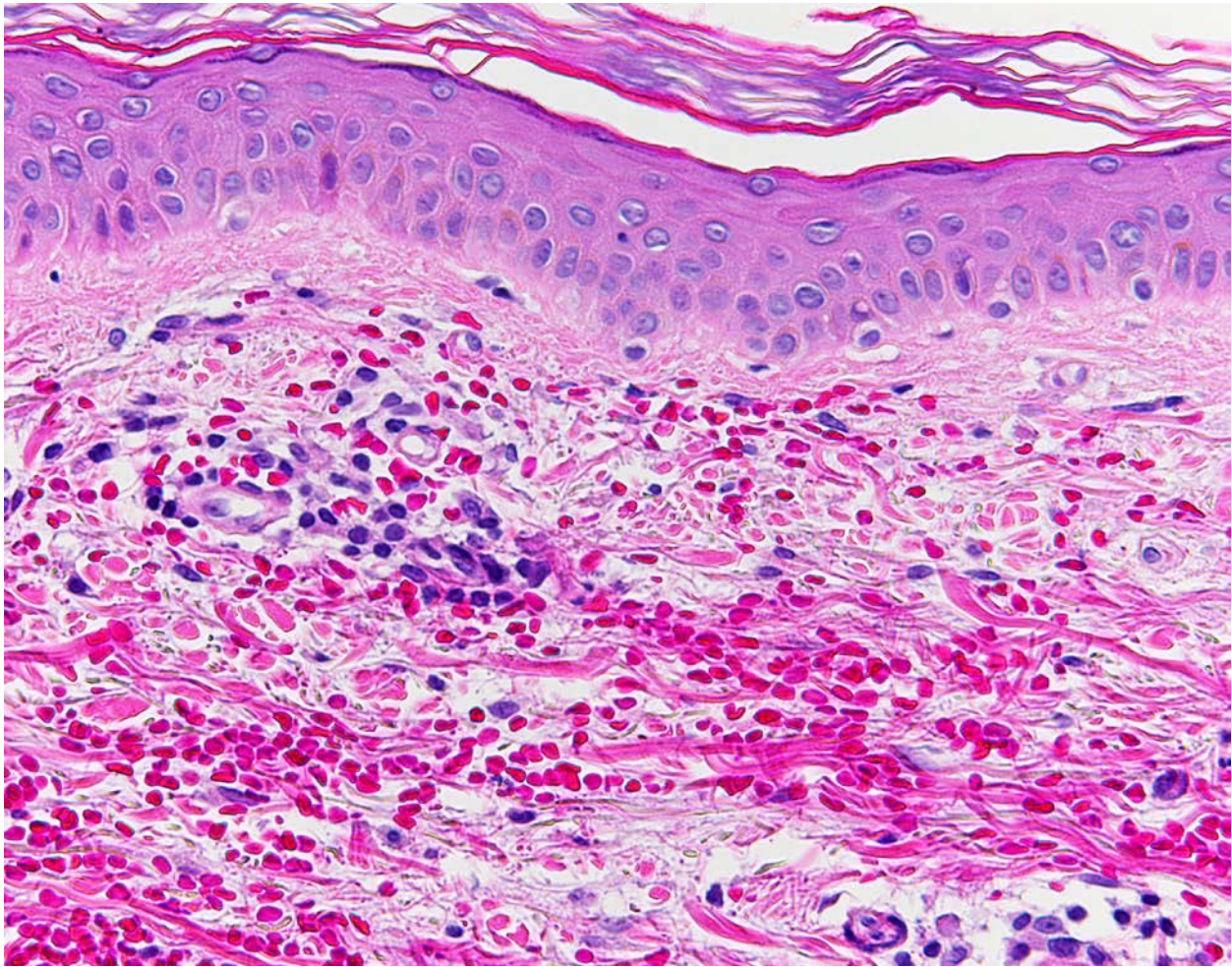
Physical exam revealed a large ecchymosis covering the majority of the right lateral thigh (Figure 1). A 10-centimeter ecchymosis was present on the right lower abdomen, along with a 2-centimeter ecchymosis on the right shaft of the penis. Innumerable 2 to 3-millimeter red palpable petechiae were evident bilaterally on the anterior shins in a dependent distribution, extending up to the distal aspect of the left thigh (Figure 2). Many corkscrew hairs were present amongst the petechiae (Figure 2).



**Figure 1.** Large, dusky, violaceous ecchymosis on right lateral thigh. **Figure 2.** Corkscrew hairs amongst a background of perifollicular hemorrhages and pinpoint palpable petechiae

The patient was admitted for inpatient workup and treatment. Differential diagnosis included nutritional deficiency amongst vasculitic and infectious etiologies. A plasma vitamin C level was obtained and revealed a value of less than 0.1 mg/dL (reference range: 0.6 to 2.0 mg/dL). Vitamin C deficiency was thus the leading etiology of the patient's presentation. Two, 4-millimeter punch biopsies of the left medial thigh and the right lateral thigh were performed. Pathology demonstrated superficial dermal perivascular lymphocytic inflammation with extravasated erythrocytes (Figure 3). Despite nonspecific histology this pathologic

interpretation combined with the patient's history was consistent with scurvy. Histology ruled out vasculitis and there was no evidence of infectious etiology.



**Figure 3.** Punch biopsy demonstrating dermal hemorrhage with sparse perivascular lymphocytic inflammation. Vascular fibrinoid degeneration, neutrophilia, and karyorrhexis were not identified. The epidermis is normal. 200X Original Magnification.

For treatment, the patient underwent ascorbic acid desensitization therapy given his history of hives one hour after ingestion of multiple ascorbic acid preparations. No previous ascorbic acid desensitization protocols could be found in the literature. Therefore the present protocol was derived from expert opinion of the allergy and immunology service (Table 1). The patient tolerated desensitization therapy without allergic manifestations and did not require epinephrine pen injection or antihistamines. He was discharged on 100 mg of ascorbic acid three times daily and instructed to follow up at three months post-vitamin replacement. At follow-up, all cutaneous manifestations had resolved and the patient was asymptomatic. Long-term follow up regarding patient's dietary and supplementation status was not available. The favorable response to ascorbic acid desensitization therapy after a history of prior allergy to ascorbic acid preparations provided compelling representation of an allergy to ascorbic acid.

**Table 1.** Ascorbic Acid Desensitization Therapy Protocol\*

Goal dose of ascorbic acid: 100 mg PO TID		
Dose	Fraction of Final Dose	Instructions
1	1/10,000	Observe patient for 15-30 minutes and advance to next dose.
2	1/5000	
3	1/2500	
4	1/1250	

5	1/625	
6	1/300	
7	1/150	
8	1/75	
9	1/40	
10	1/20	
11	1/10	
12	1/5	
13	1/2.5	
14	1/1	Full dose of final strength. Administer next full dose in 8 hours.
15	Full dose	Administer 100 mg PO TID

\* Oral liquid suspension ascorbic acid was prepared by inpatient pharmacy for desensitization. An anaphylaxis kit was available at the bedside, containing epinephrine intramuscular injection pens. An albuterol inhaler was also available at bedside. The patient received two puffs of albuterol prior to desensitization, but was not premedicated with antihistamines nor required further puffs of albuterol. Liquid cetirizine was additionally present at the bedside as a cautionary measure.

## Discussion

As a water-soluble vitamin also known as ascorbic acid, vitamin C is an essential cofactor for hydroxylase enzymes that catalyze the hydroxylation of procollagen precursors. This modification of procollagen is indispensable for proper collagen formation [1]. In a vitamin C deficient state, the final collagen product is aberrant. When allowed to progress, vitamin C deficiency leads to the clinical syndrome scurvy. Findings of scurvy are largely due to defective collagen synthesis producing disordered connective tissue [2]. Historically scurvy prevailed in sailors lacking access to fruits and vegetables. Although scurvy is a rare occurrence today, subclinical deficiencies of vitamin C remain prevalent. A 2008 study evaluated vitamin C deficiency in low-income populations of the United Kingdom, revealing a deficiency in 25% of men and 16% of women [3]. A 2003-2004 study conducted in the United States found 17.4% of men and 10.4% of women in low-income populations deficient. In general, vitamin C deficiency boasts a higher prevalence in men older than sixty years, smokers, obese individuals, and those belonging to a low socioeconomic status [4].

Scurvy stems secondarily from two causes: inadequate intake and reduced absorption of ascorbic acid. In the United States, inadequate intake affects the impoverished, the psychiatrically ill, severely malnourished individuals, and those lacking dietary fruits and vegetables (such as widowers, food faddists, and individuals with fruit and vegetable allergies) [1,5,6]. Alcoholics are subject to a particularly high risk of vitamin C deficiency; they are affected not only by poor dietary intake, but also by alcohol's effect on decreasing ascorbic acid absorption [7]. In patients with severe infections or malabsorptive bowel disorders, blunted absorption and an increase in metabolic requirements both contribute to a vitamin C deficient state [7].

Patients may develop symptoms of scurvy 1-3 months after a diet devoid of vitamin C [2]. Constitutional symptoms related to vitamin C deficiency include fatigue, weakness, and malaise. Additionally, deficient patients bear a high risk of concomitant folate, vitamin B12, and iron deficiencies producing anemia that may exacerbate global symptoms [6]. Anemia also develops secondary to acute blood loss from hemorrhage into the gastrointestinal tract, muscles, joints, and soft tissues [7]. Other generalized symptoms include depression, neuropathy, vasomotor instability, and edema [2].

The emergence of cutaneous findings alerts the clinician to consider scurvy as a diagnosis. Classical signs manifest as follicular hyperkeratosis and perifollicular hemorrhage predominantly involving the buttocks and lower extremities. The susceptibility of the dependent limbs to hemorrhage is owed to decreased perivascular collagen that cannot withstand the accumulating hydrostatic pressures due to gravity. Consequently extravasation of red blood cells ensues [7]. At times, hemorrhage may be associated with substantial follicular hyperkeratosis prodding the clinician to interpret this finding as palpable purpura. Such misinterpretation

may cloud the clinical picture by introducing vasculitis into the differential diagnosis [7,8,9]. Petechiae and ecchymoses not associated with hair follicles may also be present elsewhere.

In the scurvitic state, hemorrhage is not confined to the skin. Patients spontaneously hemorrhage into muscle, soft tissues, and joints causing painful hematomas and hemarthroses. Subperiosteal bone hemorrhages also develop and provoke excruciating pain [7,8]. Oral abnormalities related to vitamin C deficiency classically manifest as swollen, erythematous, smooth, and shiny gingivae that bleed with minor trauma [10]. Subungual linear splinter hemorrhages may also be present. In advanced disease, teeth loosen secondary to resorption of alveolar bone, and gingivae appear violaceous, black, or necrotic [7].

The defective collagen formation in scurvy results in poor wound healing as well as softening and thinning of precocious scars. The deficient state also causes increased disulfide cross-linking of hair keratins ultimately leading to the development of various hair shaft abnormalities. Hairs become coiled into “corkscrew” configurations while others bend at one or more foci into “swan-neck” deformities [7]. Alopecia has also been noted in scurvitic patients in conjunction with Sjogren’s syndrome symptoms [7,11].

The diagnosis of scurvy is primarily based on clinical presentation; characteristic physical exam findings, evidence of inadequate dietary intake, and rapid reversal of symptomatology after supplementation with ascorbic acid confirm the diagnosis [1,6,7]. Laboratory evaluation is not always necessary. However, if ordered, lab aberrations may reveal anemia, leukopenia, and an elevated erythrocyte sedimentation rate (ESR), which causes confusion of the diagnosis with rheumatologic diseases [7,8]. A plasma vitamin C or ascorbic acid level may be obtained, however, this value tends to reflect recent vitamin C intake rather than total body stores [7]. A plasma concentration below 0.2 mg/dL is considered to be indicative of vitamin C deficiency [12] and clinical features may begin to manifest at this level. Leukocyte ascorbic acid levels are a more reliable indication of total body stores. However, this test is not readily available and requires specific collection and storage guidelines [13].

Cutaneous biopsy is not necessary for diagnosis. However, histologic analysis is advantageous in ruling out other potential diagnoses such as vasculitis. Cutaneous specimens classically demonstrate perifollicular inflammation, hemorrhage, hemosiderin deposition, fibrosis, and hyperkeratosis. Dilated hair follicles with keratin plugging are typically present, along with the occasional coiled hair [6,7].

In order to replenish total body stores of vitamin C, patients are recommended to take 300-1000 milligrams of ascorbic acid daily [6,7,8]. Pain and lethargy may improve within 24 hours of supplementation and significantly subside within 2-3 days. Cutaneous manifestations resolve after 2-4 weeks and oral mucosal changes within 1-2 weeks. Hair shaft abnormalities, including “corkscrew” hairs, typically resolve after 4 weeks of treatment [7].

Although there have been several previous reports of allergic phenomena to citrus fruits [14-17], no cases of explicit ascorbic acid allergies have been previously reported or suggested. Ascorbic acid allergy in this case was diagnosed based on history and response to treatment. Typically patients manifest allergic responses to excipients within oral formulations of supplements. However this patient reacted to two distinct ascorbic acid formulations, making excipient allergy less likely. This patient certainly had an allergy to oranges confirmed by skin prick testing. Although a definitive ascorbic acid allergy was not confirmed with absolute certainty, the history and response to treatment are together highly suggestive of such an allergy.

## Conclusions

Despite the infrequent occurrence of scurvy in the present times, the condition should be included within the differential diagnosis when history and physical exam suggest a deficiency. Retrieving a dietary history is a key element in establishing the diagnosis. In the present case, dietary history suggested an ascorbic acid allergy averting the patient from fruit and vegetable consumption. Ascorbic acid has not been previously reported as a known allergen. There are currently no documented case reports of ascorbic acid allergy, nor any records of desensitization protocols. This case thus marks a rare occurrence, and the earliest record of such an allergic phenomenon. Additionally, this case discloses the first desensitization protocol for managing a presumed ascorbic acid allergy. Future cases of suspected ascorbic acid allergy should be documented and managed with equivalent protocols.

## References

1. Smith A, Di Primio G, Humphrey-Murto S. Scurvy in the developed world. *CMAJ : Canadian Medical Association journal = journal de l'Association medicale canadienne*. Aug 9 2011;183(11):E752-755.
2. Pazirandeh S, Lo CW, Burns DL. Overview of water-soluble vitamins. *UpToDate* Nov 2013. <http://www.uptodate.com/contents/overview-of-water-soluble-vitamins>.
3. Mosdol A, Erens B, Brunner EJ. Estimated prevalence and predictors of vitamin C deficiency within UK's low-income population. *Journal of public health*. Dec 2008;30(4):456-460.

4. Schleicher RL, Carroll MD, Ford ES, Lacher DA. Serum vitamin C and the prevalence of vitamin C deficiency in the United States: 2003-2004 National Health and Nutrition Examination Survey (NHANES). *The American journal of clinical nutrition*. Nov 2009;90(5):1252-1263.
5. Reuler JB, Broudy VC, Cooney TG. Adult scurvy. *Jama*. Feb 8 1985;253(6):805-807.
6. Olmedo JM, Yiannias JA, Windgassen EB, Gornet MK. Scurvy: a disease almost forgotten. *International journal of dermatology*. Aug 2006;45(8):909-913.
7. Hirschmann JV, Raugi GJ. Adult scurvy. *Journal of the American Academy of Dermatology*. Dec 1999;41(6):895-906; quiz 907-810.
8. Mertens MT, Gertner E. Rheumatic manifestations of scurvy: a report of three recent cases in a major urban center and a review. *Seminars in arthritis and rheumatism*. Oct 2011;41(2):286-290.
9. Francescone MA, Levitt J. Scurvy masquerading as leukocytoclastic vasculitis: a case report and review of the literature. *Cutis*. Oct 2005;76(4):261-266.
10. Touyz LZ. Oral scurvy and periodontal disease. *Journal*. Dec 1997;63(11):837-845.
11. Hood J, Burns CA, Hodges RE. Sjogren's syndrome in scurvy. *The New England journal of medicine*. May 14 1970;282(20):1120-1124.
12. Food and Nutrition Board IoM. Chapter 5: Vitamin C. In: *DRI Dietary Reference Intakes for vitamin C, vitamin E, selenium, and carotenoids*. Washington, DC: National Academy Press,2000:185.
13. Emadi-Konjin P, Verjee Z, Levin AV, Adeli K. Measurement of intracellular vitamin C levels in human lymphocytes by reverse phase high performance liquid chromatography (HPLC). *Clinical biochemistry*. May 2005;38(5):450-456.