

Cutaneous leukocytoclastic vasculitis after second dose of mRNA COVID-19 vaccine

Sonja CS Simon^{1,2}, Victor Olsavszky¹

Affiliations: ¹Department of Dermatology, Venereology, and Allergology, University Medical Center and Medical Faculty Mannheim, Heidelberg University, and Center of Excellence in Dermatology, Mannheim, Germany, ²Skin Cancer Unit, German Cancer Research Center (DKFZ), Heidelberg, Germany

Corresponding Author: Victor Olsavszky MD, Department of Dermatology, Venereology and Allergy, University Medical Center and Medical Faculty Mannheim, Heidelberg University, Theodor-Kutzer-Ufer 1-3, DE-68135 Mannheim, Germany, Tel: 49-621-383-2126, Fax: 49-621-383-3815, Email: victor.olsavszky@umm.de

Abstract

Numerous cutaneous reactions following COVID-19 vaccination have already been described. Vasculitis, however, is a rare adverse event, occurring mainly after the first COVID-19 vaccination. Herein, we report a patient with IgA-positive cutaneous leukocytoclastic vasculitis, unresponsive to a moderate dose of systemic corticosteroid that erupted after the second dose of the Pfizer/BioNTech vaccine. Since booster vaccinations are being administered, we intend to raise awareness among clinicians and to highlight this potential reaction and its therapeutic approach.

Keywords: COVID-19, mRNA, vaccination, vasculitis

Introduction

The BNT162b2 vaccine by Pfizer/BioNTech was one of the first messenger ribonucleic acid (mRNA) vaccines against the coronavirus disease 2019 (COVID-19) to receive approval. This vaccine is usually administered in two doses three weeks apart. A broad spectrum of cutaneous reactions after both doses have been documented with local site reactions and acute urticaria being the predominant reported dermatologic findings [1]. We report a case of a patient developing cutaneous leukocytoclastic vasculitis following administration of the second dose of the BNT162b2 mRNA vaccine.

Case Synopsis

A 31-year-old woman presented to our outpatient department with multiple palpable purpuric papules disseminated on her legs, lower arms, and lower abdomen (**Figure 1**). The papules first appeared on her legs together with fever one day after her second Pfizer/BioNTech vaccination. The flare had been treated by her primary care doctor with a low dose of 5mg oral prednisone. After an initial improvement she noted a quick recurrence and progression of the papules to the lower abdomen. She denied any other complaints, infections, or medication. Her medical history was unremarkable. We admitted the patient for further diagnostics and treatment.

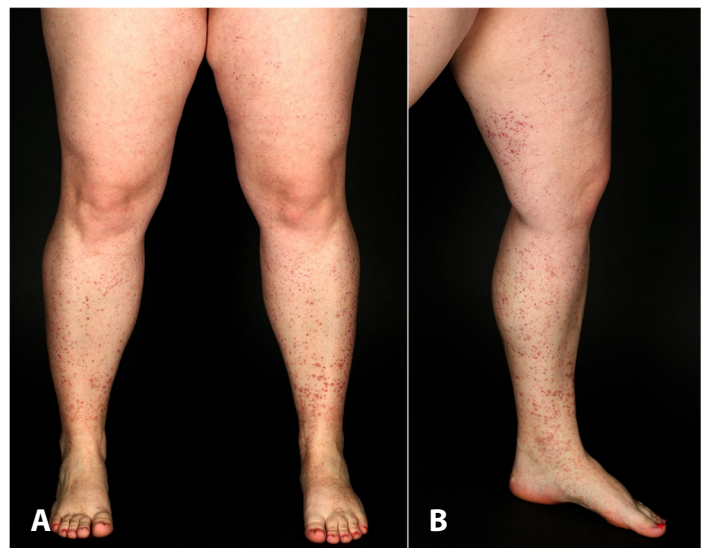

Figure 1. A) Overview of both lower extremities with disseminated palpable purpuric papules. B) Left leg showing the extent of the papules.

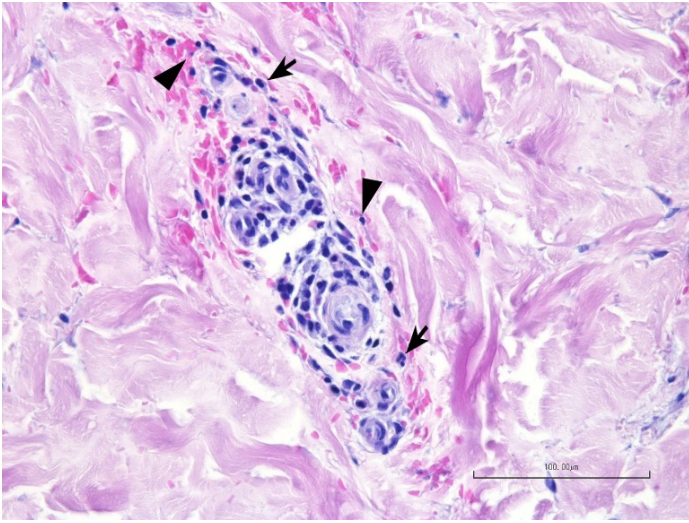


Figure 2. Histological examination from the lower right extremity showing a perivascular lymphocytic infiltrate with neutrophils (arrows), leukocytoclasia (arrowheads) and erythrocyte extravasation in the dermis. H&E, scale bar 100 μ m.

Two punch biopsies taken from her lower right leg revealed a perivascular lymphocytic infiltrate with neutrophils and scattered eosinophils. Leukocytoclasia and dermal erythrocyte extravasation were present as well (**Figure 2**). These histopathological features were highly suggestive of early changes observed in leukocytoclastic vasculitis. Moreover, the direct immunofluorescence testing was positive for perivascular deposits of C3 and IgA. To exclude other potential causes, we performed ultrasound examinations of the abdomen and regional lymph nodes, a chest X-ray, and an electrocardiogram, which were without any pathological findings. Serological tests for HIV, hepatitis B, C and syphilis rendered negative results. Antinuclear and antineutrophil cytoplasmic antibodies were within normal limits. Kidney involvement was ruled out by 24-hour urine test. A diagnosis of IgA-positive cutaneous leukocytoclastic vasculitis was established based on the clinical, histological, and laboratory findings.

We administered 40mg methylprednisolone orally (0.5mg per kg of body weight) and triamcinolone acetonide topically. Compression therapy of the lower legs was initiated. Given the persistence of the papules, we increased the dosage of oral methylprednisolone to 80mg (1mg per kg of body weight), which led to an improvement of the

cutaneous lesions. On a follow-up appointment four weeks later, the patient reported complete remission of the skin lesions and was tapering methylprednisolone 20mg every four days (**Figure 3**). The oral corticosteroid was discontinued after reaching a final dose of 4mg.

Case Discussion

Cutaneous leukocytoclastic vasculitis is an inflammatory condition characterized by deposition of immune complexes at the dermal postcapillary venule wall. Although a cause may not be found, inciting conditions include infections, medications, autoimmune diseases, and rarely vaccinations. General vasculitis has been documented after the administration of various vaccines, such as influenza or hepatitis vaccines. However, the pathophysiology of vasculitis following vaccinations is still poorly understood [2].

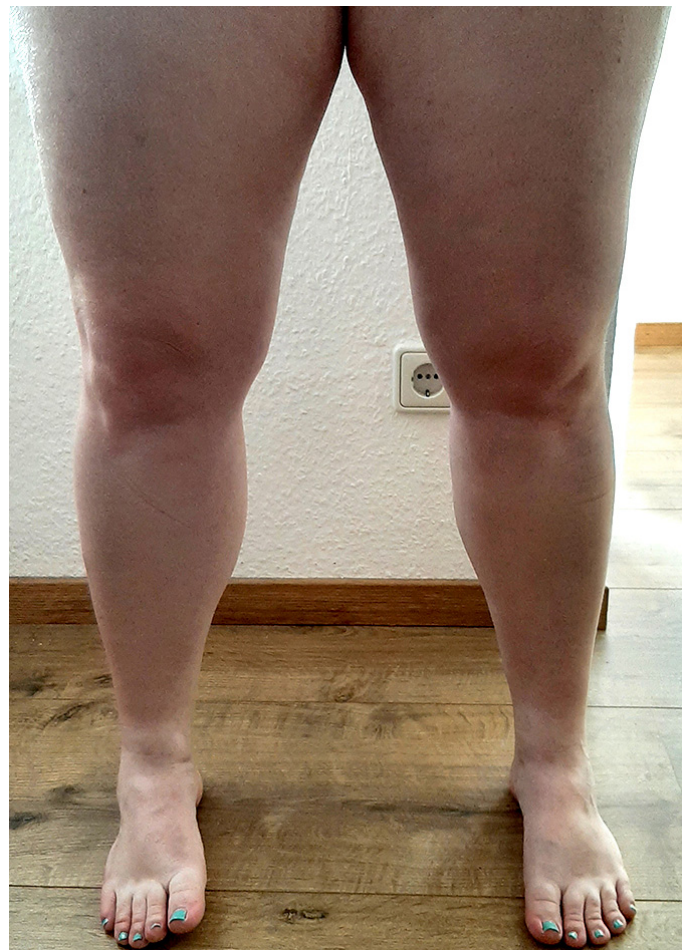

Figure 3. No residual cutaneous lesions at four weeks follow-up.

Only a few cases of leukocytoclastic vasculitis after COVID-19 vaccination can be found in the literature. Cohen et al. reported a vasculitis flare after the first dose of a mRNA COVID-19 vaccine [3], whereas two cases describe a cutaneous vasculitis following a single dose of an adenoviral vector COVID-19 vaccine [4,5]. Moreover, there are reports of IgA-positive vasculitis and lymphocytic vasculitis following the vaccination of previously COVID-19-infected patients [6,7]. A large study with 414 cutaneous reactions after mRNA COVID-19 vaccination collected only three cases of vasculitis after the first vaccine dose [1], further supporting the rareness of this specific adverse event.

Our patient developed skin lesions after the administration of the second mRNA-based vaccine dose. To our knowledge leukocytoclastic vasculitis has been mainly reported after the first dose of a mRNA COVID-19 vaccine, with only one case being published after the second dose [8]. The clinical

course of our patient suggests a causal association between the vaccination with BNT162b2 and the leukocytoclastic vasculitis.

Conclusion

Additional studies are needed to investigate the prevalence and the pathophysiology of vasculitis after more than one vaccine dose administration. Clinicians should be aware of this potential adverse event occurring after the second vaccine application in healthy individuals. This is especially important since refreshments with a second or a third dose of COVID-19 vaccines have already begun in various countries.

Potential conflicts of interest

The authors declare no conflicts of interest.

References

1. McMahon DE, Amerson E, Rosenbach M, et al. Cutaneous reactions reported after Moderna and Pfizer COVID-19 vaccination: A registry-based study of 414 cases. *J Am Acad Dermatol*. 2021;85:46-55. [PMID: 33838206].
2. Bonetto C, Trotta F, Felicetti P, et al. Vasculitis as an adverse event following immunization - Systematic literature review. *Vaccine*. 2016;34:6641-51. [PMID: 26398442].
3. Cohen SR, Prussick L, Kahn JS, et al. Leukocytoclastic vasculitis flare following the COVID-19 vaccine. *Int J Dermatol*. 2021;60:1032-3. [PMID: 33928638].
4. Berry CT, Eliliwi M, Gallagher S, et al. Cutaneous small vessel vasculitis following single-dose Janssen Ad26.COV2.S vaccination. *JAAD Case Rep*. 2021;15:11-4. [PMID: 34337124].
5. Guzman-Perez L, Puerta-Pena M, Falkenhain-Lopez D, et al. Small-vessel vasculitis following Oxford-AstraZeneca vaccination against SARS-CoV-2. *J Eur Acad Dermatol Venereol*. 2021;35:e741-e3. [PMID: 34310763].
6. Bostan E, Gulseren D, Gokoz O. New-onset leukocytoclastic vasculitis after COVID-19 vaccine. *Int J Dermatol*. 2021;60:1305-6. [PMID: 34241833].
7. Vassallo C, Boveri E, Brazzelli V, et al. Cutaneous lymphocytic vasculitis after administration of COVID-19 mRNA vaccine. *Dermatol Ther*. 2021;34:e15076. [PMID: 34327795].
8. Mucke VT, Knop V, Mucke MM, et al. First description of immune complex vasculitis after COVID-19 vaccination with BNT162b2: a case report. *BMC Infect Dis*. 2021;21:958. [PMID: 34530771].