

Photo Vignette

Molluscum contagiosum of the areola and nipple: case report and literature review

Brian S. Hoyt BS¹, Jaime A. Tschen MD², Philip R. Cohen MD³

Dermatology Online Journal 19 (7): 14

¹Medical School, University of Texas Medical School at Houston, Houston, TX, ²St. Joseph Dermatopathology, Houston, TX, ³Department of Dermatology, University of California San Diego, San Diego, CA

Correspondence:

Philip R. Cohen, MD
10991 Twinleaf Ct.
San Diego, CA 92131-3643
713-628-5143
mitehead@gmail.com

Brian S. Hoyt, BS
360-739-2497
Brian.S.Hoyt@uth.tmc.edu

Abstract

Molluscum contagiosum is a common cutaneous infection caused by a double-stranded DNA poxvirus. Skin lesions classically present as small, flesh-colored papules with central umbilication. Lesions are frequently seen on the face, trunk, and extremities of children, or on the genitals of young adults as a sexually transmitted infection. Molluscum contagiosum on the nipple or areola has only been previously described in 4 women. We describe a woman with molluscum contagiosum on the left areola and review the clinical characteristics and histological findings of patients who developed molluscum contagiosum of the nipple or areola.

Introduction

Molluscum contagiosum is a common, contagious infection caused by a double-stranded DNA poxvirus. It frequently occurs on the face, trunk, and extremities of children and adolescents; it is also commonly encountered on the genitals of young adults as a result of sexual contact. However, molluscum contagiosum of the areola or nipple is rare. We present a woman who developed a solitary molluscum contagiosum lesion on her left areola. We also review the characteristics of the other patients who developed molluscum contagiosum of the areola or nipple.

Case Report

A healthy, immunocompetent 28-year-old woman presented with a 6x6 mm flesh-colored flattened papule on her left areola. She first noticed the lesion 3 months earlier and stated that it had been increasing in size. The lesion was neither pruritic nor painful. The patient denied recent trauma, oral or sexual contact with her breast, or any contact with persons who had similar lesions. An 8mm excisional biopsy was performed. Histology revealed keratinocytes with ovoid, amorphous granules (molluscum bodies) in the cytoplasm with peripherally displaced nuclei, pathognomonic for the diagnosis of molluscum contagiosum (Figure 2).

Discussion

Molluscum contagiosum is a common, self-limiting skin lesion associated with molluscum contagiosum virus, a member of the poxviridae family. It is spread by direct contact with infected individuals or fomites [1]. It is primarily found in three distinct patient populations: children, sexually active adults, and immunocompromised individuals [2]. Children frequently develop

molluscum contagiosum lesions on the trunk, arms, and face [1]. Adults may develop lesions near the genitals as a sexually transmitted infection [2]. Lastly, in immunocompromised individuals molluscum contagiosum can present with atypical morphology (such as giant lesions) or unusual distribution (such as disseminated) [3].

The lesions of molluscum contagiosum have a characteristic appearance. They are small (2-8mm), pearly, dome-shaped, skin-colored papules with central umbilication [1]. They can be solitary. However, they more commonly present in clusters, which have an average of 11-20 lesions [1]. Immunocompromised patients or those with atopic dermatitis may develop multiple, diffusely distributed lesions of molluscum contagiosum [2]. Lesions are usually asymptomatic. However, some patients complain of tenderness or pruritus [1].

The areola and nipple are unusual locations to develop molluscum contagiosum. Using the search terms *molluscum contagiosum and breast or nipple or areola*, we identified only 4 reported instances of individuals who developed molluscum contagiosum on their areola or nipple (Table 1) [4-7]. All five patients were women and each had confirmation of the diagnosis using either cytology or histology. None of the patients were immunocompromised.

Three of the five women were in their 20s, and each of them developed a solitary lesion on their areola. The other two women developed molluscum contagiosum lesions on their nipple. A 45-year-old woman developed a raised, umbilicated nodule on her left nipple that was treated with a caustic pencil and subsequently ulcerated [6]. Another woman developed a firm swelling of her nipple that was excised and found to be molluscum contagiosum [7]. Notably, only one of the five patients (20 percent) presented with the classic umbilicated papule [6].

The clinical diagnosis of molluscum contagiosum is usually straightforward and histological examination is often unnecessary. However, when lesions lack the characteristic morphology or when the location is unusual (Table 2), the diagnosis can be more challenging [4-11]. Differential diagnosis includes basal cell carcinoma, benign adnexal tumor, condyloma acuminatum, cutaneous fungal infections (coccidioidomycosis, cryptococcus, or histoplasmosis.), glandular (adenomatous) hyperplasia, keratoacanthoma, leiomyoma, Paget's disease, papilloma, papular granuloma annulare, syringoma, and verruca vulgaris [1, 6, 12].

The definitive diagnosis of molluscum contagiosum is made by visualizing molluscum bodies (Henderson-Patterson bodies), the pathognomonic feature of molluscum contagiosum virus [12]. Molluscum bodies are large, ovoid, homogenous, dense bodies found in the cytoplasm of infected keratinocytes. They often are sufficiently large to displace the nucleus to the cell periphery [6]. Identification of molluscum bodies can be made using either cytology or histology. Clinicians can attempt to express keratinous material through the central pore of the molluscum papule; this material can be applied to a slide and stained, using either Giemsa, Gram, Papanicolaou, or Wright stain [12]. This allows clinicians to make a diagnosis without needing to do a lesional biopsy [6]. Alternatively, molluscum bodies can be identified on tissue obtained from a punch or shave biopsy of a clinical lesion.

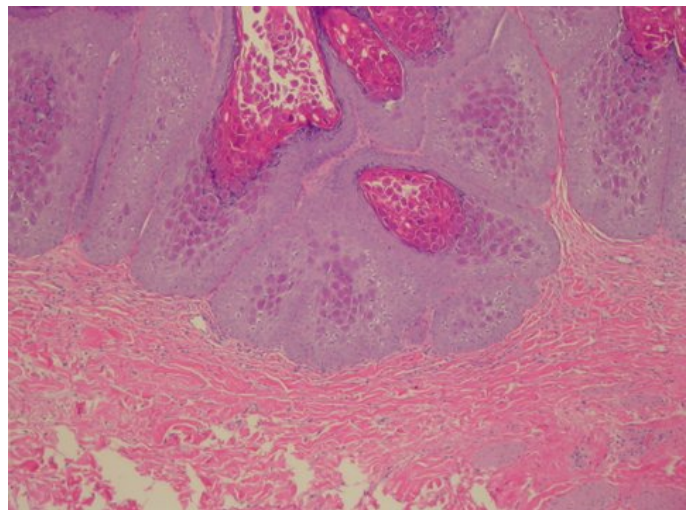
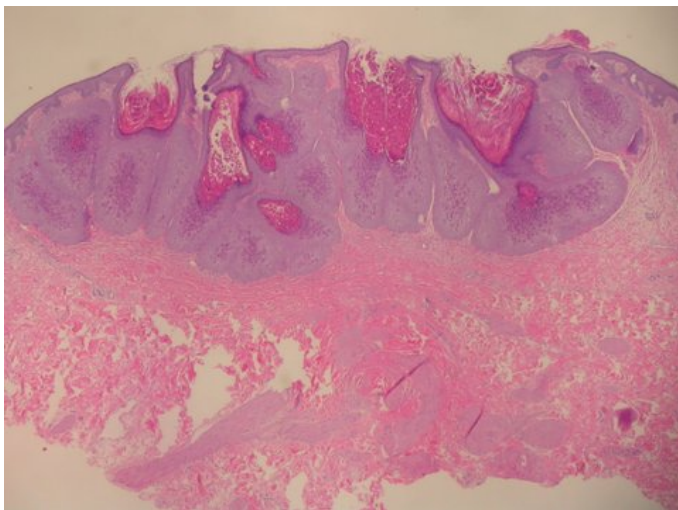
Treatment of molluscum contagiosum is somewhat controversial. The lesions are usually self-limiting. In such individuals, they generally clear spontaneously in six to nine months [2, 13]. However, owing to the highly contagious nature of the disease, many practitioners opt to treat the lesions. Medical options include cantharidin, cidofovir, cimetidine, imiquimod, salicylic acid, or retinoic acid [1, 12]. Alternatively, lesions may be treated with cryotherapy, curettage, or surgical excision [1, 12].

Conclusion

Molluscum contagiosum is a ubiquitous viral infection; yet, it is rare for individuals to develop molluscum lesions on the nipple or areola. Including our patient, only five women have been reported with molluscum contagiosum on the nipple (2 patients) or areola (3 patients). The classic morphology was only seen in one of the five patients. The differential diagnosis for papules on the nipple and/or areola is extensive; the definitive diagnosis of molluscum contagiosum is made by visualizing molluscum bodies by microscopy. The lesions of molluscum contagiosum are usually self-limited. However, a variety of treatment options exist to facilitate the resolution of the skin lesions.

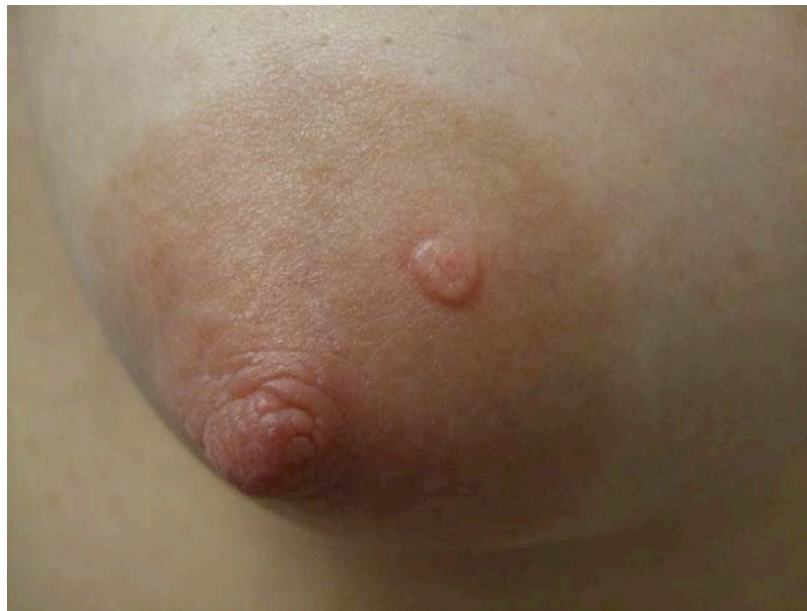
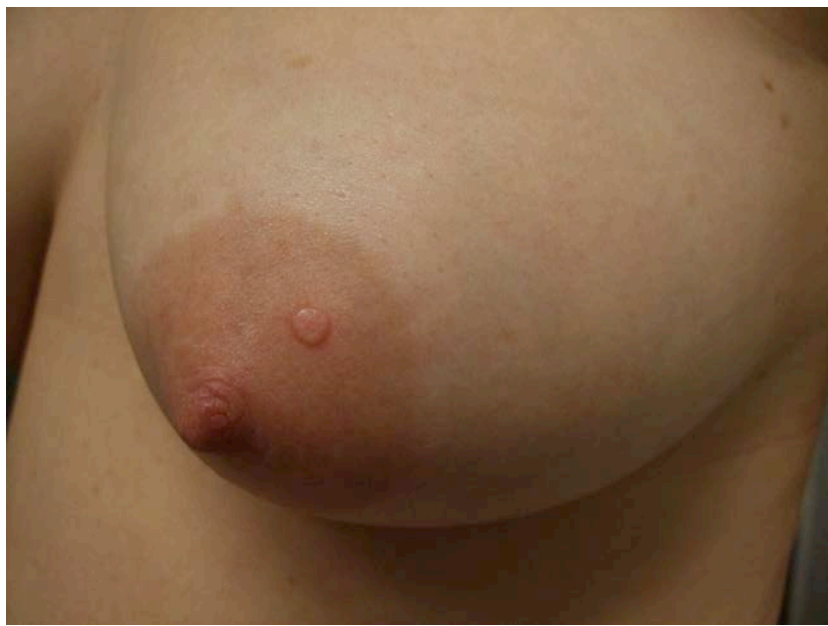
Fig 1 (a and b): A 28-year-old woman developed a solitary 6x6 mm papule on her left breast. Excisional biopsy revealed molluscum contagiosum.



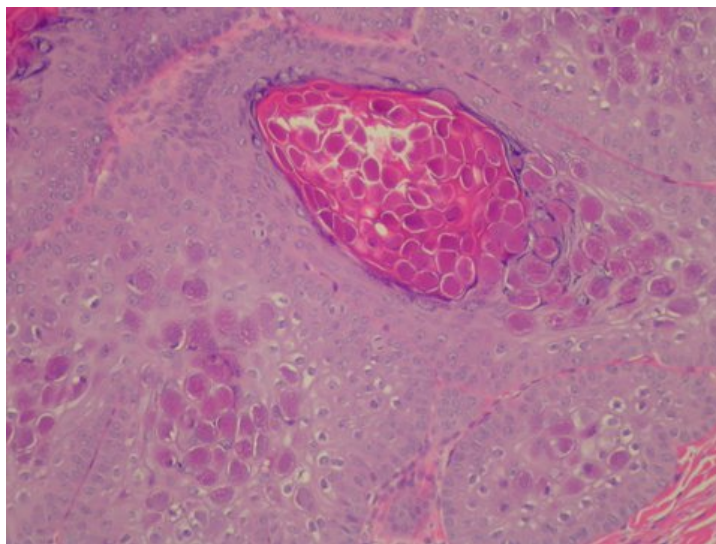


Fig 2 (a, b, and c): Scanning view (a) of molluscum contagiosum lesion with invaginated epithelium and smooth muscle bundles of the areola in superficial and mid dermis. Higher magnification of epidermis (b and c) demonstrates characteristic molluscum bodies in the lesion. (Hematoxylin and Eosin, a=x20, b=x40, c=x100)

Table 1: Molluscum contagiosum of the areola and nipple [a]

| Case | Age Sex | Location | Morphology | Symptoms | Treatment | Follow-up | Ref |
|------|------------|----------|--|---|---|---------------|-----|
| 1 | 20y F | R.areola | Raised, flat, yellowish papule | Rapidly growing | ? | ? | 4 |
| 2 | 22y F | L.areola | Small superficial lesion, subsequent infection | Initially painless, then infected and painful | ? | ? | 5 |
| 3 | 28y F | L.areola | Flesh-colored flattened papule | None | Excision | No recurrence | CR |
| 4 | 45y F | L.nipple | Raised umbilicated nodule treated with caustic pencil; subsequent ulceration | Initially painless, then itchy, painful | ? | ? | 6 |
| 5 | ?y F | Nipple | Cutaneous bulging of nipple with firm mass | ? | Excision, 5% imiquimod 3x/week for 2 months | No recurrence | 7 |

[a] abbreviations: CR, current report; F, female; L, left; R, right; Ref, Reference; x, times; y, years; /, per; ?, not reported; %, percent.

Table 2: Rare locations of molluscum contagiosum

| Location | Reference |
|----------|-----------|
| Areola | 4, 5 |
| Eyelids | 8, 9 |

| | |
|------------------|------|
| Feet (plantar) | 10 |
| Mucous membranes | 11 |
| Nipple | 6, 7 |

References

1. Brown J, Janniger CK, Schwartz RA, Silverberg NB. Childhood molluscum contagiosum. *Int J Dermatol.* 2006 Feb;45(2):93-99. Review. [PMID: 16445494.]
2. Bandino JP, Wohltmann WE, Hivnor CM. What is your diagnosis? Giant molluscum contagiosum. *Cutis.* 2011 Oct;88:164, 170-172. [PMID: 22106720.]
3. Inui S, Asada H, Yoshikawa K. Successful treatment of molluscum contagiosum in the immunosuppressed adult with topical injection of streptococcal preparation OK-432. *J Dermatol.* 1996;23:628-630. Review. [PMID: 8916664.]
4. Schmid-Wendtner MH, Rütten A, Blum A. [Flat rapidly growing tumor in a 20-year-old woman]. *Hautarzt.* 2008;59:838-840. German. [PMID: 18584138.]
5. Carvalho G. Molluscum contagiosum in a lesion adjacent to the nipple. Report of a case. *Acta Cytol.* 1974;18:532-534. [PMID: 4614643.]
6. Kumar N, Okiro P, Wasike R. Cytological diagnosis of molluscum contagiosum with an unusual clinical presentation at an unusual site. *J Dermatol Case Rep.* 2010;4(4):63-65. [PMID: 21886755.]
7. Parlakgumus A, Yildirim S, Bolat FA, Caliskan K, Ezer A, Colakoglu T, Moray G. Dermatoses of the nipple. *Can J Surg.* 2009;52:160-161. [PMID: 19399214.]
8. Schornack MM, Siemsen DW, Bradley EA, Salomao DR, Lee HB. Ocular manifestations of molluscum contagiosum. *Clin Exp Optom.* 2006 Nov;89:390-393. [PMID: 17026608.]
9. Vardhan P, Goel S, Goyal G, Kumar N. Solitary giant molluscum contagiosum presenting as lid tumor in an immunocompetent child. *Indian J Ophthalmol.* 2010;58:236-238. [PMID: 20413930.]
10. Cohen PR, Tschen JA. Plantar molluscum contagiosum: a case report of molluscum contagiosum occurring on the sole of the foot and a review of the world literature. *Cutis.* 2012;90:35-41. [PMID: 22908731.]
11. de Carvalho CH, de Andrade AL, de Oliveira DH, Lima Ed, da Silveira EJ, de Medeiros AM. Intraoral molluscum contagiosum in a young immunocompetent patient. *Oral Surg Oral Med Oral Pathol Oral Radiol.* 2012;114:e57-60. [PMID: 22727108.]
12. Hanson D, Diven DG. Molluscum contagiosum. *Dermatol Online J.* 2003;9:2. PMID: 12639455.
13. Guirguis-Blake J. Interventions for molluscum contagiosum. *Am Fam Physician.* 2006;74:1504. [PMID: 17111888.]