

Case presentation

C-MYC positive angiosarcoma of skin and breast following MammoSite® treatment

W. James Tidwell MD^{1,2}, Jim Haq MD³, Kamila F Kozlowski MD⁴ and Paul B Googe MD^{2,5,6}

Dermatology Online Journal 21 (10): 8

1 University of Louisville Division of Dermatology, Louisville, KY

2 University of Tennessee Graduate School of Medicine, Knoxville, Tennessee

3 Specialty Labs/KDL Pathology, Knoxville, Tennessee

4 Knoxville Comprehensive Breast Center, Knoxville Tennessee

5 Knoxville Dermatopathology Laboratory, Knoxville, Tennessee

6 Vanderbilt University, Nashville

Correspondence:

W. James Tidwell
3810 Springhurst Blvd.
Louisville, KY 40241
270-933-2109 (cell)
502-329-8184 (fax)

Abstract

Angiosarcoma of the skin and breast is a known complication of chronic lymphedema following mastectomy or external radiation therapy for breast cancer. We report a 68-year-old woman who presented with a 2.5 cm violaceous plaque on the skin of the right breast and a 3 cm mixed mass of the same breast by ultrasound 9 years after MammoSite® balloon brachytherapy. Biopsy of the skin lesion and the breast mass showed an infiltrating high grade angiosarcoma. The tumor cells in the skin and breast showed immunohistochemical reactivity for C-MYC. A total mastectomy confirmed the presence of high grade angiosarcoma in the skin and parenchyma of the breast and radiation changes in the breast parenchyma. Surgical margins were considered negative. The patient had cutaneous recurrence of angiosarcoma three months after the mastectomy. There have been only two other case reports in the literature of angiosarcoma on the skin following MammoSite® therapy. The c-myc mutation has been shown to be a specific mutation for angiosarcoma following radiation treatment. It is not found in atypical vascular lesions following irradiation or angiosarcoma unrelated to radiation treatment.

Keywords: Angiosarcoma, c-myc, Mammosite.

Introduction

Angiosarcoma is a rare, highly malignant proliferation of endothelial cells. It is characterized histologically by spindled or epithelioid atypical endothelial cells and poorly demarcated dissecting blood vessels with irregular branching, papillary projections into the lumina. Its prevalence has been reported to be 5 cases per 10,000 patients treated by mastectomy for breast carcinomas, which is the same prevalence of primary breast angiosarcomas occurring in healthy patients [1]. MammoSite balloon

brachytherapy is a double-lumen catheter that applies high dose radiation directly into the breast following the surgical creation of a lumpectomy cavity. To our knowledge, there have been only two reported cases in the literature of angiosarcoma following MammoSite brachytherapy [2,3]. The reports did not comment on staining for c-myc. This is a case report of a 68-year-old woman who developed c-myc positive angiosarcoma of the skin and breast nine years after MammoSite brachytherapy

Case synopsis

A 59-year-old multiparous, woman presented in December of 2004 for excisional biopsy of suspicious density on right breast mass following mammogram. The biopsy found invasive mammary carcinoma, tubular variant, strongly positive for estrogen and progesterone receptors. In January of 2005, the patient underwent full axillary node dissection resulting in six benign lymph nodes. Later that month, she had repeat biopsy of the upper outer quadrant of the breast for a second opinion. Pathology revealed infiltrating ductal carcinoma Nottingham Grade 1. Ultrasound of the mass found a single cyst in the right upper outer quadrant measuring 2.8 cm in diameter.

In February of 2005, a right partial mastectomy and insertion of Mammosite brachytherapy was performed. The patient was administered 340 cGy twice daily for a total of 3400 cGy in 10 fractions. She was monitored annually for follow up treatment with a yearly MRI and mammogram. A 4-5 cm fluid collection secondary to a seroma in the lumpectomy bed was noted every year.

In January 2014, nine years after mammosite brachytherapy, the patient presented with a 2.5 cm violaceous periareolar plaque on her right breast and a 1 cm satellite papule (Figure 1). The lesion had been progressively growing for the past month with associated pruritus and significant mastodynia. The patient said it easily bled. A fine needle aspirate (FNA) yielded 100 mL of bloody fluid was drained in the office of the known seroma that had been followed for 9 years. FNA found numerous atypical cells strongly suspicious for malignancy in the surrounding seroma cavity, degenerated histiocytes in a proteinaceous background, no inflammation, and a negative Gram stain for bacteria.

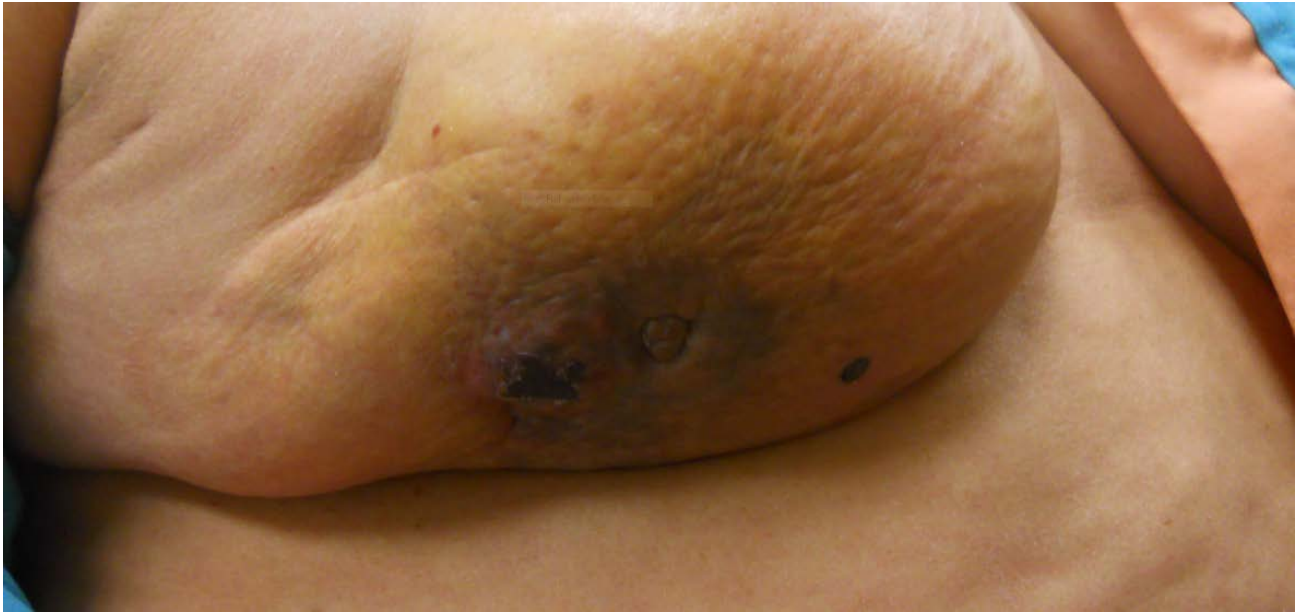

Figure 1. Clinical photo January 2014, a 2.5 cm violaceous periareolar plaque on the right breast with a 1 cm satellite papule. Angiosarcoma with c-myc mutation was found in both the skin and lumpectomy cavity.

A follow up ultrasound directed core needle biopsy of a right breast mixed mass measuring 3 cm and punch biopsy of skin were performed. The breast mass showed anastomosing vascular channels with endothelial enlargement with areas of solid growth of malignant cells with epithelioid appearance and prominent nucleoli. The cytological features suggested high grade angiosarcoma. However, mitoses were not easily detected and no necrosis was seen (Figure 2). Punch biopsy of the skin found dermal lymphedema and minimal chronic inflammation. Rare abnormal blood vessels were seen in the dermis. Staining of the specimens was positive for c-myc, CD 31, CD 34, D2-40, and Ki-67 and negative for AE1/AE3 (Figure 3). A diagnosis of radiation-induced angiosarcoma in both the skin and breast cavity was made.

One week later, a right total mastectomy was performed. Follow up surgical pathology confirmed diagnosis of angiosarcoma involving the dermis, subcutaneous, and underlying breast tissue. Necrosis of over 50% was seen and a mitotic rate of 4 per 10 in the high power fields. All surgical margins were negative for sarcoma (Figure 4).

Three months later, a biopsy of the right chest wall in May 2014 found recurrence of high grade angiosarcoma after mastectomy (Figure 5).

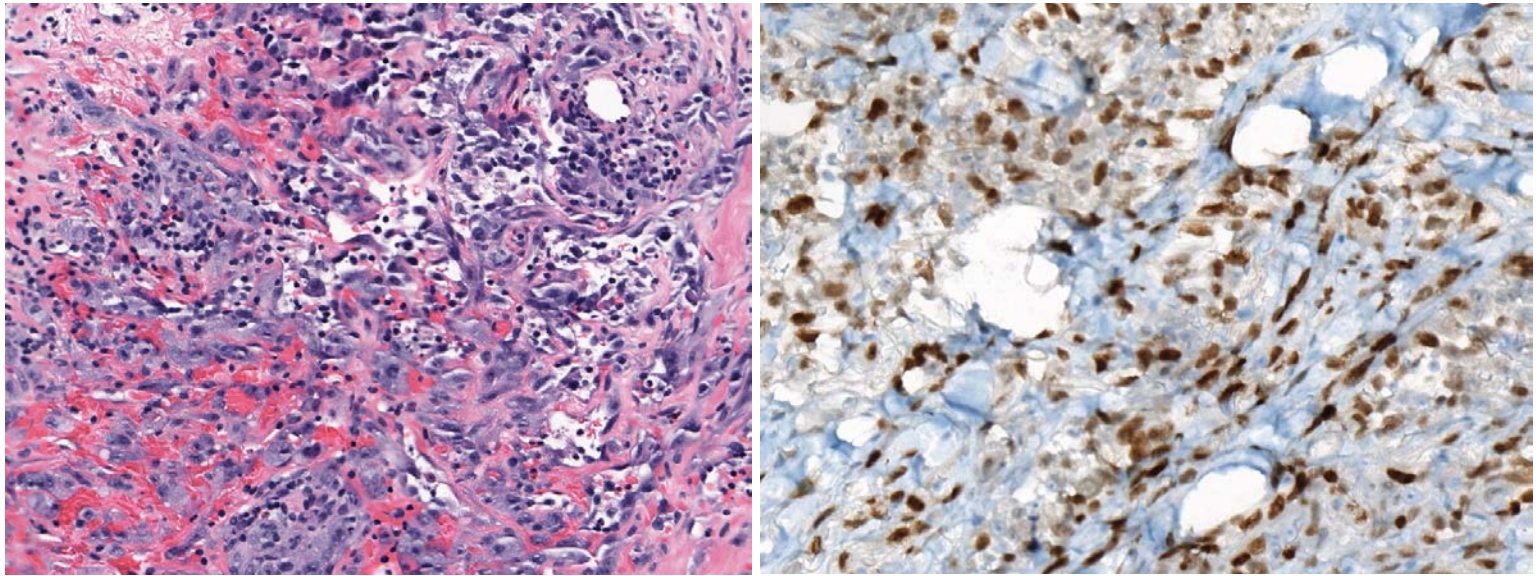


Figure 2. Breast biopsy January 2014, malignant endothelial infiltrate and irregular vascular formations. **Figure 3.** Breast cavity biopsy January 2014, positive immunohistochemical staining for c-myc indicating radiation induced angiosarcoma.

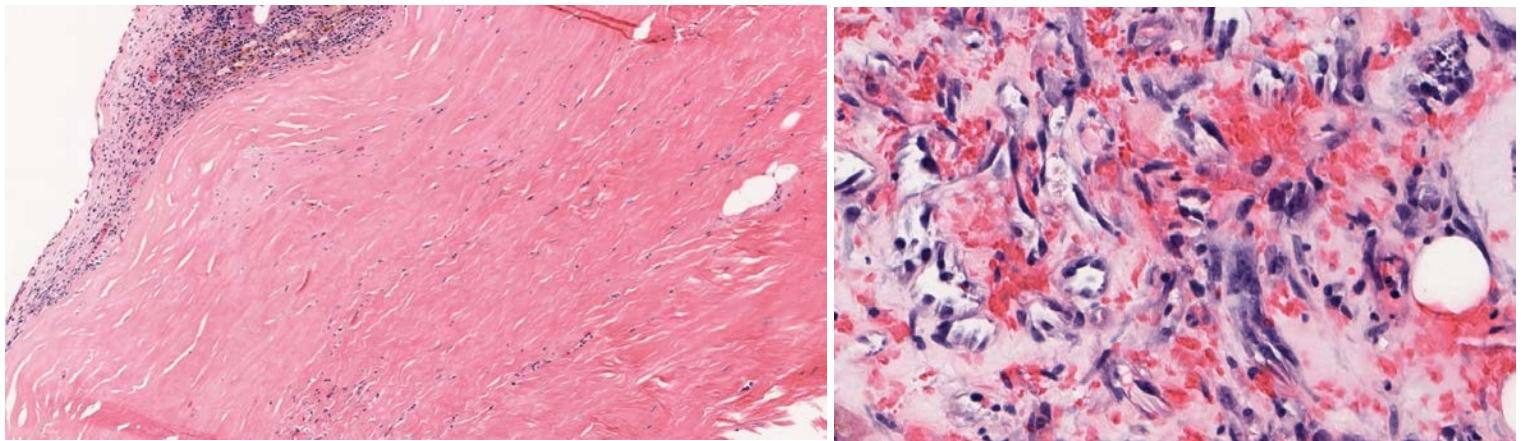


Figure 4. Mastectomy February 2014: Breast parenchyma shows hyalinized fibrosis, telangiectasia, and atrophy consistent with radiation effect. No residual mammary carcinoma was found. **Figure 5.** Soft tissue biopsy of right chest wall in May 2014, recurrence of high-grade angiosarcoma after mastectomy.

Discussion

MammoSite balloon brachytherapy applicator was first approved by the American Food and Drug Administration (FDA) in May 2002. It is a double-lumen catheter with an inflatable balloon at the distal tip. Following lumpectomy, the catheter is placed inside the surgically created cavity and inflated with saline and contrast material. A high dose radiation source is inserted based on the regimen selected. The most widely used regimen, 34 Gy in 10 fractions [4], was used in this case. Lymphangiosarcoma in postmastectomy lymphedema was first reported in 1948 [5]. After breast-conserving treatment became the standard of care for breast cancer, angiosarcoma was found in irradiated breast tissue years after treatment [6-7]. A review of the literature finds only two previous case reports of angiosarcoma following MammoSite balloon brachytherapy [2,3].

Angiosarcoma is a rare, highly malignant proliferation of endothelial cells manifesting as pruritic macules or papules of bright red or violaceous color. It may contain nodules that easily bleed and ulcerate. It can occur in normal skin, especially near the scalp, or in localized lymphedema. Stuart-Treves syndrome is angiosarcoma occurring in postmastectomy lymphedema [5]. It may also be seen in post-irradiated tissue with subsequent lymphedema.

The histology of angiosarcoma shows spindle or epithelioid atypical endothelial cells and poorly demarcated dissecting blood vessels with irregular branching, papillary projections into the lumina. Prominent extravasated erythrocytes and hemosiderin are also seen. Staining of the tissue is positive for endothelial cell markers such as CD31 and CD34.

The rate of angiosarcoma following breast conservation treatment for carcinoma was 5 per 10,000 in a French cancer center review [1]. The median latency time in this review between treatment of the breast carcinoma and the diagnosis of the breast angiosarcoma was 6.2 year (74 months). A review of two breast centers in the United States found 11 angiosarcomas in more than 5,000 malignant breast neoplasms following radiation therapy, an incidence rate of 0.1%-0.2% [8]. A United States single center, retrospective study of ninety-five patients found a latency period of radiation-associated angiosarcoma from 1.4 to 26 (median 7) years. One-year and five-year disease specific survival rates were 93.5% and 62.6% respectively [9].

Myc is a regulator gene that codes for a transcription factor and is found on Chromosome 8. Its official name is v-myc avian myelocytomatosis viral oncogene homolog but commonly referred to as c-myc. The gene acts as a DNA binding protein and is part of the MYC/MAD/MAX family of helix-loop-helix zipper motif proteins. The c-myc gene was first discovered in Burkitt lymphoma. Translocation of t(8;14) involves c-myc and can lead to the development of Burkitt lymphoma. A mutated version of c-myc is found in many cancers such as breast, prostate, lymphoma, lung, and colon. The protein encoded by this gene is a multifunctional, nuclear phosphoprotein that plays a role in cell cycle progression. A mutation that causes c-myc to be constitutively expressed is thought to increase cellular proliferation and cancer. [10,11].

Over the past few years, pathologists have been using c-myc amplification by fluorescence in situ hybridization (FISH) to diagnosis angiosarcoma secondary to irradiation. The distinction between post radiation atypical vascular proliferations and post radiation angiosarcoma can be difficult due to overlapping clinical and microscopic features. Spontaneous angiosarcomas of the skin and soft tissue unrelated to radiotherapy have not been found to stain for c-myc. (12-15)

Conclusions

The observation of angiosarcoma of the lumpectomy cavity after MammoSite brachyradiation therapy is a rare finding. We conclude that angiosarcoma can occur secondary to a c-myc mutation where endothelium is exposed to radiation and subsequent chronic lymphedema is formed. The patient did not have clinical symptoms or signs of angiosarcoma until 9 years after the MammoSite treatment. This is longer than the median time of 6.2 years by surface radiation reported by Marchal [1] and the 7 years reported by Torres [9]. Owing to radiation occurring beneath the skin, it could take longer for the patient to notice the development of angiosarcoma with MammoSite treatment.

The pathogenesis of angiosarcoma in irradiated soft tissue and c-myc mutation is still unclear. In our case, the healing lumpectomy cavity was exposed to high dose radiation. The healing would have had granulation tissue with cells growing at a fast rate exposed to large amount of radiation. This could have caused the c-myc mutation and subsequent angiosarcoma 9 years later.

It is interesting to note that c-myc mutations are not found in postradiation atypical vascular proliferations, which aids in the differentiation of these growths and questions the role of atypical vascular proliferation as a precursor lesion to secondary angiosarcoma.

References

1. Marchal C, Weber B, De Lafontan B, Resbeut M, Mignotte H, du Charelard PP, Chutuli B, Reme-Saumon M, Broussier-Leroux A, Chaplain G et al (1999). Nine breast angiosarcomas after conservative treatment for breast carcinoma: a survey from French comprehensive Cancer Centers. *Int J Radiat Oncol Biol Phys* 44(1): 133-199 [PMID: 10219803]
2. Andrews S, Wilcoxon R, Benda J, Jacobson G (2010) Angiosarcoma following MammoSite partial breast irradiation. *Breast Cancer Res Treat* 124: 279-282 [PMID: 20496164]
3. Mansfield SA, Zynger DL, Agnese DM. (2014) Angiosarcoma and Breast Cancer Recurrence Eight Years Following Mammosite Therapy. *The Breast Journal* 2014 Sep 17. [Epub ahead of print] [PMID: 25228265]
4. Offersen BV, Overgaard M, Kroman N, Overgaard J (2009) Accelerated partial breast irradiation as part of breast conserving therapy of early breast carcinoma: a systematic review. *Radiother Oncol* 90(1): 1-13. [PMID: 18783840]
5. Stewart FW, Treves N (1948) Lymphangiosarcoma in postmastectomy lymphedema; a report of six cases in elephantiasis chirurgica. *Cancer* 1(1): 64-81. [PMID: 18867440]
6. Stokkel MP, Peterse HL (1992) Angiosarcoma for the breast after lumpectomy and radiation therapy for adenocarcinoma. *Cancer* 69(12): 2965-2968. [PMID: 1317249]

7. Wijnmaalen A, van Ooijen B, van Geel BN, Henzen-Logmans SC, Trurniet-Conker AD (1993) Angiosarcoma of the breast following lumpectomy, axillary node dissection, and radiotherapy for primary breast cancer: three case reports and a review of the literature. *Int J Radiat Oncol Biol Phys* 26(1): 135-139. [PMID: 8387065]
8. Wang XY, Jakowski J, Tawfik OW, Thomas PA, Fan F (2009) Angiosarcoma of the breast: a clinicopathologic analysis of cases from the last 10 years. *Ann Diagn Pathol* 13(3) 147-150.
9. Torres KE, Ravi V, Kin K, Yi M, Guadagnolo, BA, et al. (2013) Long-Term Outcomes in Patients with Radiation-Associated Angiosarcoma of the Breast Following Surgery and Radiotherapy for Breast Cancer. *Ann Surg Oncol* 20:1267-1274. [PMID: 19433291]
10. MYC v-myc avian myelocytomatosis viral oncogene homolog (2014) Available at: www.ncbi.nlm.nih.gov/gene/4609 [accessed on 22 April 2014] Gene ID: 4609
11. Ventana Medical Systems (2011). Anti C-MYC(Y69) Rabbit Monoclonal Primary Antibody. Available at: http://productlibrary.ventanamed.com/ventana_portal/OpenOverlayServlet?launchIndex=1&objectId=790-46281011077EN [accessed on 7 May 2014]
12. Mentzel T, Schildhaus HU, Palmedo G, Buttner R, Kutzner H (2012) Postradiation cutaneous angiosarcoma after treatment of breast carcinoma is characterized by MYC amplification in contrast to atypical vascular lesions after radiotherapy and control cases: clinicopathological, immunohistochemical and molecular analysis of 66 cases. *Modern Pathol* 25, 75-85. [PMID: 21909081]
13. Fernandez A, Sun Y, Tubbs R, Goldblum J, Billings S (2011) FISH for MYC amplification and anti-MYC immunohistochemistry: useful diagnostic tools in the assessment of secondary angiosarcoma and atypical vascular proliferations. *J Cutan Pathol* 39: 234-242. [PMID: 22121953]
14. Manner J, Radlwimmer B, Hohenberger P, Mossinger K, et al (2010) MYC high level gene amplification is a distinctive feature of angiosarcomas after irradiation or chronic lymphedema. *Am J of Pathol* 176, 34-39. [PMID: 20008140]
15. Guo T, Zhang L, Chang N, Singer S, Maki R, Antonescu C (2011) Consistent MYC and FLT4 gene amplification in radiation induced angiosarcoma but not in other radiation-associated atypical vascular lesions. *Gene Chromo Cancer* 50(1): 25-33. [PMID:20949568]