

**Photo vignette**

**A rare clinical manifestation of spinulate demodicosis**

**Funda Tamer, Evren Sarifakioglu, Ozge Mine Orenay**

**Dermatology Online Journal 22 (11): 17**

**Department of Dermatology, Turgut Ozal University, Ankara, Turkey**

**Correspondence:**

Funda Tamer  
Turgut Ozal University Faculty of Medicine, Department of Dermatology  
Alparslan Turkes Cd, No:57  
Emek, Ankara, Turkey  
Tel. +90 312 203 55 55  
E-mail: fundatmr@yahoo.com

---

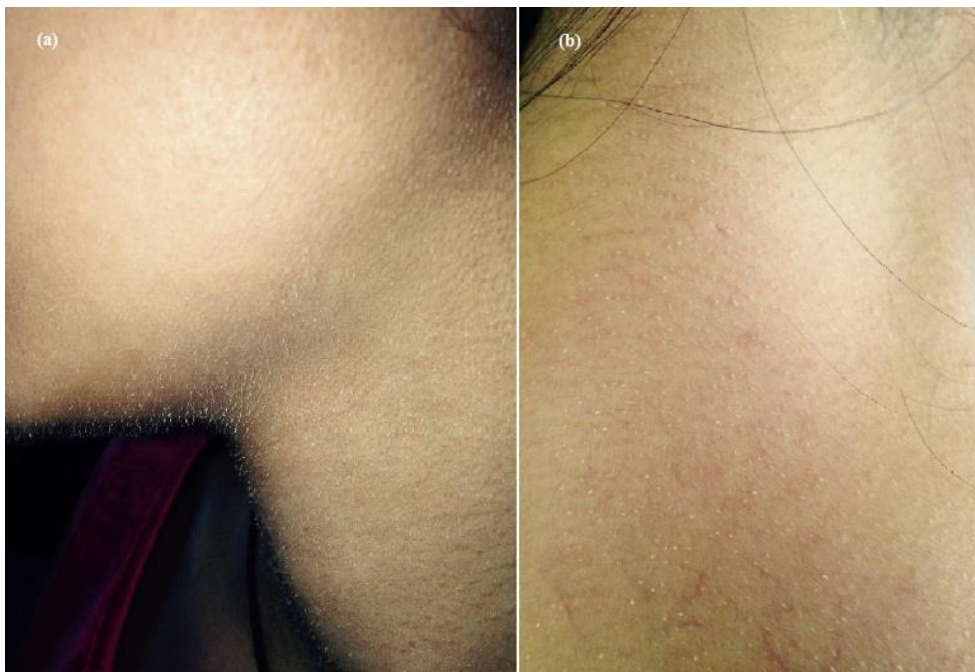
**Abstract**

Demodicosis is a chronic skin disease caused by *Demodex* mites such as *Demodex folliculorum* and *Demodex brevis*. *Demodex* mites live in pilosebaceous units and they are regarded as a part of the normal skin flora. Nevertheless, it has been suggested that the presence of five or more mites per cm<sup>2</sup> by the standardized skin surface biopsy technique could be considered as pathogenic.

**Keywords: demodicosis, demodex, demodex folliculitis**


**Case synopsis**

A 15-year-old girl, presented with an asymptomatic eruption on the face, neck and trunk for one week. The patient noted that the lesions first appeared on her face and then they spread to the trunk. The past medical history and family history were both unremarkable. However, the patient stated that she had diarrhea and fever, which resolved spontaneously without treatment two weeks prior. The physical examination showed multiple, skin colored, follicular hyperkeratotic spicules on the perioral region, chin, neck, chest, and upper back (Figure 1).



**Figure 1. (a.b)** Multiple follicular hyperkeratotic spicules on the face, neck, and upper back.

Standardized skin surface biopsy was performed to confirm our initial clinical diagnosis of demodicosis. The patient's skin was cleaned with 70% alcohol. Ethyl cyanoacrylate liquid glue was applied on a slide in a 1 cm<sup>2</sup> area. The slide was pressed over the skin lesions on the left nasolabial fold and kept for about 30 seconds. The slide was removed gently and a drop of immersion oil was placed on the sample. Then the specimen was covered with a glass cover slip and examined by light microscopy. Direct light microscopic examination revealed multiple demodex mites (Figure 2). Therefore she was treated with tea tree oil shampoo and 5% permethrin cream twice daily. The lesions disappeared completely within 10 days.



**Figure 2** Microscopic examination revealed more than five mites per cm<sup>2</sup> (original magnification  $\times 10$ ).

## Discussion

Demodicosis can be classified clinically into primary and secondary types. Primary demodicosis describes the lesions in patients without an underlying condition. However, secondary demodicosis occurs in patients with medical history of inflammatory dermatoses or systemic diseases causing immunosuppression. Other predisposing factors include treatment with epidermal growth factor receptor inhibitors, topical glucocorticoids, calcineurin inhibitors, phototherapy, and chronic renal failure [1]. The infestation is common in elderly patients. The sites of predilection are forehead, cheeks, nasolabial folds, and nose. However, *D. brevis* may also be found in the ear canal, on the trunk, and on the pubis. *Demodex* mite infestations may play a role in various skin diseases such as chronic blepharitis, keratoconjunctivitis, chronic ear pruritus, and external otitis [2]. Clinical forms of the infestation include pityriasis folliculorum (spinulate demodicosis), rosacea like demodicosis, perioral, periorbital, and periauricular dermatitis, demodex abscess, papulopustular rashes of the scalp, solitary granuloma, facial rash after phototherapy, facial hyperpigmentation, and demodectic alopecia [1-3]. There have been a few reports of patients with facial spinulosis associated with *demodex* mites. Microscopic examination of these spicules could reveal several

mites and keratin debris protruding through the follicle. It should be kept in mind that follicular spicules may be a clinical manifestation of hypovitaminosis A, chronic renal failure, Crohn disease, lymphoma, monoclonal gammopathy, multiple myeloma, filiform hyperkeratosis, and multiple minute digitate hyperkeratosis [3-5].

Multiple tiny spicules, which are localized to the face have been reported as a clinical feature of demodicosis. However, the patient we presented above had widespread lesions on her face, neck, chest, and upper back. Furthermore, demodicosis occurred in our patient at the age of 15. Thus, we thought that the condition might be triggered by her acute diarrhea accompanied by fever. Our case is a unique example of *demodex* mite infestation with hyperkeratotic follicular spicules that developed not only on the face but also on the neck and trunk.

## References

1. Chen W, Plewig G. Human demodicosis: revisit and a proposed classification. *Br J Dermatol.* 2014 Jun;170(6):1219-25. [PMID:24471456]
2. Elston CA, Elston DM. Demodex mites. *Clin Dermatol.* 2014 Nov-Dec;32(6):739-43. [PMID:25441466]
3. Monteagudo B, Cabanillas M, García-Rego JA et al. Spinulosis as a manifestation of demodicidosis. *Actas Dermosifiliogr.* 2009 Jul-Aug;100(6):512-4. [PMID:19709560]
4. Fariña MC, Requena L, Sarasa JL et al. Spinulosis of the face as a manifestation of demodicidosis. *Br J Dermatol.* 1998 May;138(5):901-3. [PMID:9666844]
5. Boutli F, Delli FS, Mourellou O. Demodicidosis as spinulosis of the face: a therapeutic challenge. *J Eur Acad Dermatol Venereol.* 2007 Feb;21:273-4. [PMID:17243980]