

Photo Vignette

Omphalolith: a rare entity but important to recognize

Gallouj salim¹, Harmouch Touafiq², Amarti Afaf², Mernissi Fatima Zahra¹

Dermatology Online Journal 20 (5): 14

¹Department of Dermatology, University Hospital Hassan second, Faculty of Medicine of Fez, Morocco.

²Department of Pathology, University Hospital Hassan second, Faculty of Medicine of Fez, Morocco.

Correspondence:

Salim Gallouj
University Hospital Hassan II
sgallouj@gmail.com

Abstract

Omphalolith (umbolith) is an uncommon entity under normal circumstances. However, in a deeply retracted umbilicus in an obese individual, the accumulation of sebum and keratin may lead to the formation of a stone. This calculus may remain undiagnosed for many years until revealed by secondary infection or ulceration. We report an interesting case of an omphalolith in a young woman. In our literature search, very few cases of omphalolith have been reported.

Keywords: umbilicus. omphalolith . umbilical concretion.

Introduction

Omphalolith is an uncommon entity under normal circumstances. However in a deeply retracted umbilicus in an obese individual, the accumulation of sebum and keratin may lead to the formation of a stone. This calculus may remain undiagnosed for many years. We report an interesting case of an omphalolith in a young woman.

Case synopsis

A 16-year-old woman presented with a pigmented tumor in the umbilicus of 14 years duration. The patient did not give any history of passage of mucous, feces, or other discharge through the umbilicus. There was no history of fever. Local examination of the umbilicus revealed, on palpation, a firm to hard mass of 3 cm. Although there was no frank ulceration, she complained about pain from the crevices of the umbilicus. The dermoscopic examination did not show a pigmented network or vascular pattern. The nodule had a dry crusted appearance and was black-brown in color. The remainder of the examination was unremarkable. Routine laboratory examination of blood and urine showed no abnormality.

Upon surgical excision, a single hard calculus was encountered and was extracted in toto. The histopathological examination of the specimen revealed concentric lamellae of keratin without evidence of any tumor. The patient remained asymptomatic when reviewed 2 months later.

Discussion

Omphalolith generally presents with a firm, black umbilical mass, resembling a malignant melanoma. Patients usually complain of umbilical discharge and pain [1]. It is often accompanied by seborrhea and abscess formation may occur. The formation of the omphalolith may be related to poor hygiene [2].

At birth, the umbilical cord contains two arteries and a vein, the rudimentary urachus (allantois), and the vitelline (omphalo-mesenteric) duct enveloped in Wharton's jelly [3]. After separation and retraction of the stump, an umbilicus, a puckered scar in the centre of the anterior abdominal wall, is formed. This umbilicus may have variable depth. In some cases persistence of the urachus or vitelline duct at the umbilicus may cause trouble in early or adult life [4].

Omphaloliths are generally asymptomatic and affected patients most often seek medical attention only in the face of secondary inflammation or infection. Poor hygiene is the most likely cause and an umbilical cleft deep enough to contain a significant concretion is also a requirement. Drs. Ichiki and Kitajima describe a greater than expected frequency in elderly Japanese individuals and suggest an association with the superstition that cleansing of "umbilical sesame" causes abdominal pain [2,5].

Awareness of the diagnosis of omphalolith is important owing to the rarity of the condition and the need to differentiate it from other benign and malignant conditions of the umbilicus, including keloid, dermatofibroma, cholesteatoma, malignant melanoma, umbilical endometriosis, primary umbilical malignancy, and umbilical metastasis. The latter is also referred to as a Sister Mary Joseph nodule [2,5].

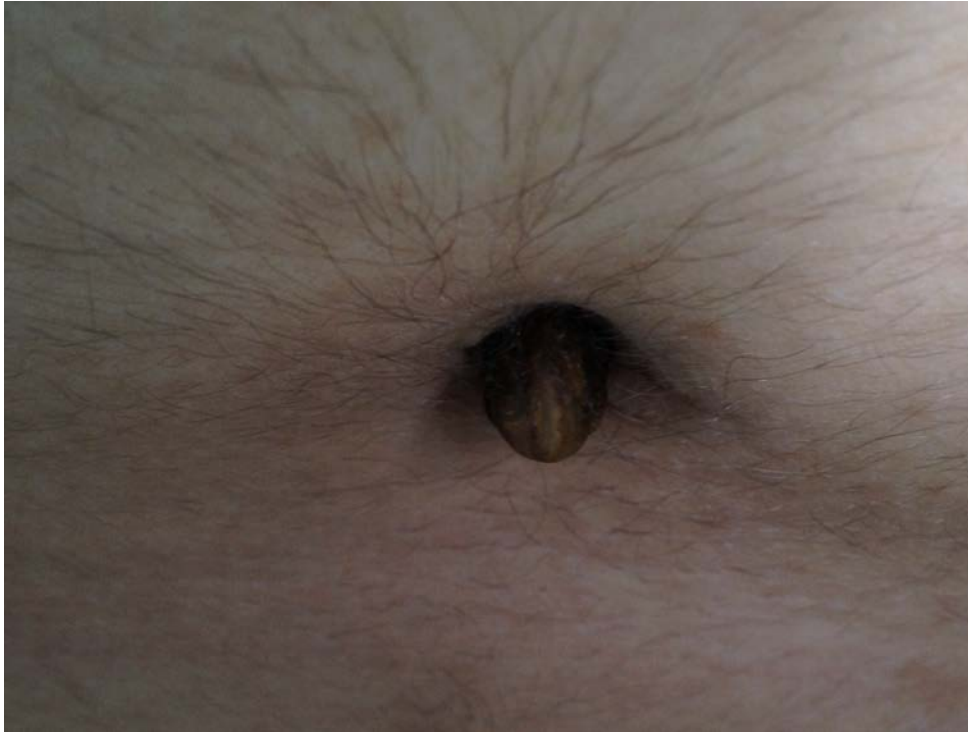

Figure 1. The umbilical concretion measured approximately 2 centimeters in length. The concretion was firm with dark brown color.

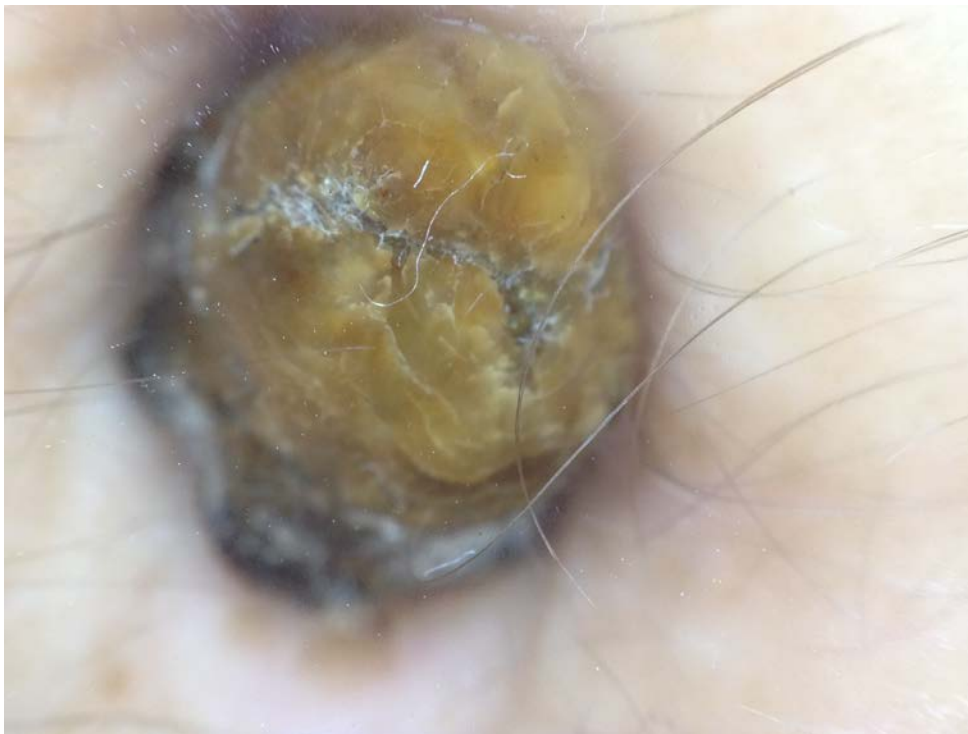

Figure 2. The dermoscopic examination did not show a pigmented network. There were no globules, dots, or vascular patterns. It exhibited a dry crusted appearance.

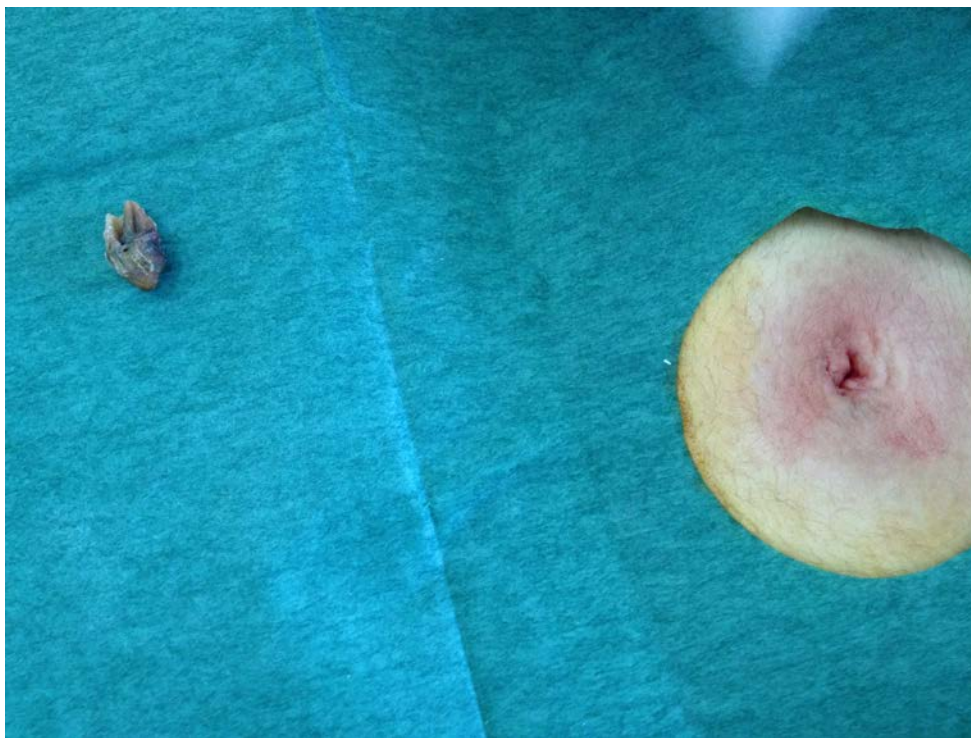

Figure 3. The appearance of the lesion after extraction.

Histologic examination showed that it contained laminated keratin, amorphous material resembling sebum, numerous terminal hairs, and scattered collections of bacteria. Moderate amounts of argentaffin staining material were detected throughout the specimen and the black color of the lesion probably related to melanin and oxidized lipids, much like an open comedone [1,5].

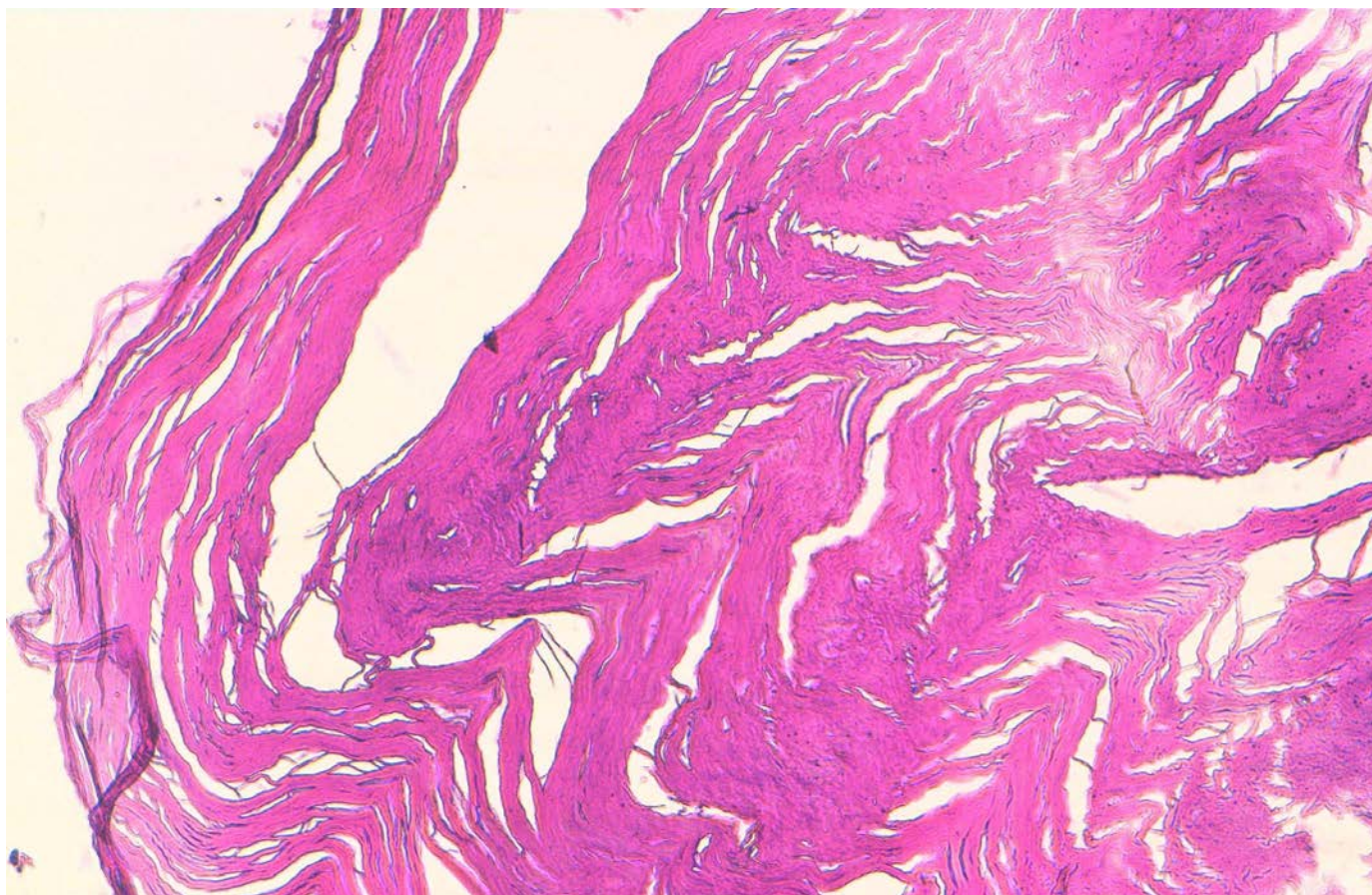


Figure 4. Histological section showing strips of laminated keratin and airy, amorphous substance without tissue structure (Hematoxylin eosin staining, magnification $\times 10$).

Cross-sectional imaging shows a well-defined hyperdense nodule within the umbilicus. In symptomatic patients, there may be an associated abscess and subcutaneous edema. MR imaging reveals a well-defined signal void of both T1- and T2-weighted sequences with no contrast enhancement [2].

The treatment is to dilate the orifice, extract the calculus, and cleanse the umbilicus. To prevent recurrence, proper hygiene should be emphasized, but in unusual cases, it may be necessary to excise the umbilicus [2,5,6].

References

1. Hijran R M and Hany M E .Omphalolith presented with peritonitis: a case report. *Cases J.* 2009, 2:8191. [PMID:19918359]
2. Nittala P . Omphalolith/umbolith: CTand MR imaging appearances in two patients. *Singapore Med J* ,2009; 50(7): 745.[PMID:19644635]
3. Burns T, Breathnach S, Cox N, Griffiths C.The general, perineal and umbilical regions. *Rook's text book of dermatology*, volume 4, 7th edn. Blackwell Science, 2004; 68:102-168.
4. Nix TE, Young CJ .Congenital umbilical anomalies. *Arch Dermatol* .1964; 90:160–165. [PMID: 14162317]
5. Sheehan D et al. Umbilical Concretion . *Radiology Case.* 2011 ; 5(4):25-31.[PMID:22470788]
6. Russel RCG, Williams NS, Bulstrode CJK (eds) .*Bailey and love's short practice of surgery*, 24th edn. Holder Arnold, London, (2004): 1288