

**Case report**

**Cyclosporine-induced sebaceous hyperplasia in a hematopoietic stem cell transplant patient: delayed onset of a common adverse event**

**Reason Wilken, Maxwell A Fung, Vivian Y Shi, Michelle Y Cheng, Forum Patel, Hawa Sultani, Emanuel Maverakis**

**Dermatology Online Journal 22 (1): 4**

**Department of Dermatology, University of California Davis Medical Center, Sacramento**

**Correspondence:**

Emanuel Maverakis, MD  
Department of Dermatology  
University of California, Davis School of Medicine  
3301 C Street, Suite 1400  
Sacramento, CA 95816  
Telephone (916) 843-7336  
Fax (916) 843-9444  
emaverakis@ucdavis.edu

---

**Abstract**

Cyclosporine-induced sebaceous hyperplasia (SH) is a well-documented entity, occurring in up to 30% of renal transplant patients treated with cyclosporine and has also been reported to occur following heart or hematopoietic stem cell transplantation (HCST). Cyclosporine has a stimulatory effect on undifferentiated sebocytes, resulting in the clinical and histologic findings in these patients. Sebaceous hyperplasia most commonly presents as asymptomatic papules over the face, chest, or groin. Herein we describe a case of a 27-year-old man who developed facial sebaceous hyperplasia five months after completing cyclosporine therapy for cutaneous graft versus host disease (GVHD) following HSCT.

**Keywords: sebaceous hyperplasia, cyclosporine, transplant**

**Introduction**

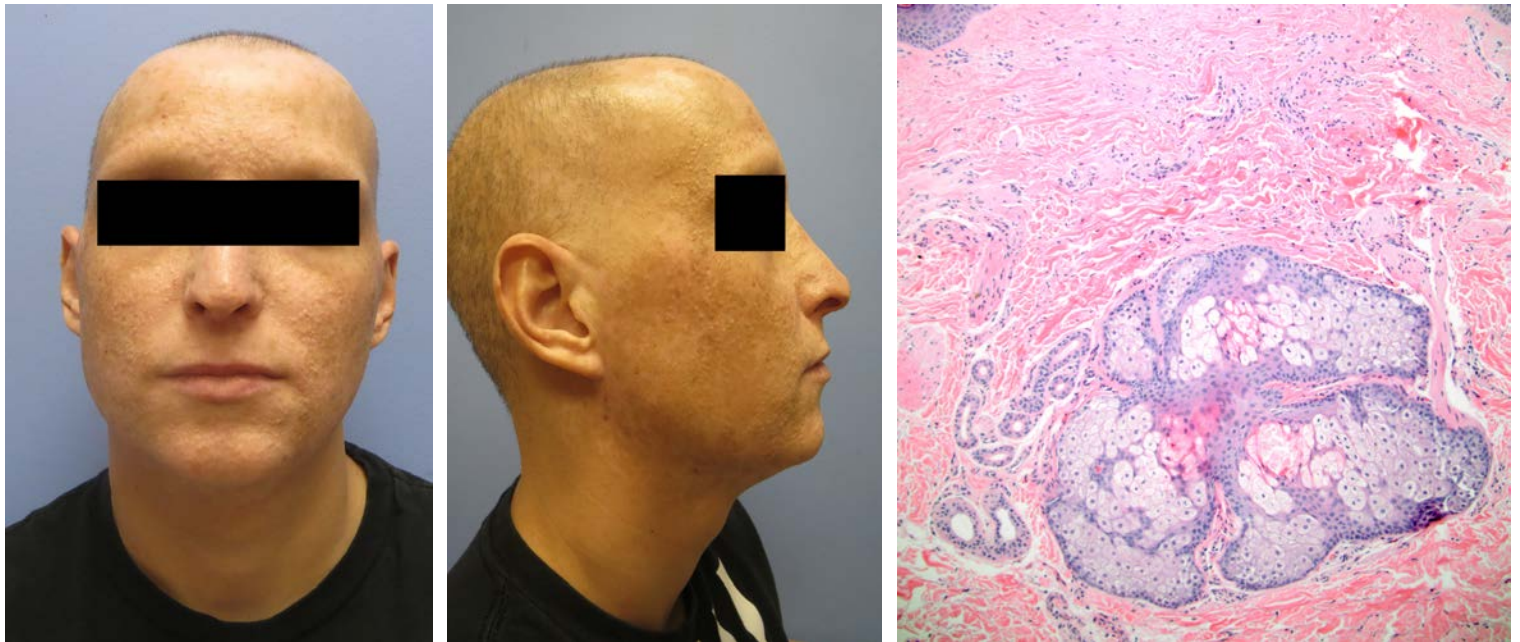
A well-described cutaneous side effect of cyclosporine administration, sebaceous hyperplasia (SH), has been described in up to 30% of renal transplant patients treated with the medication and is the result of a stimulatory effect on undifferentiated sebocytes [1, 2]. SH has also been reported following cyclosporine treatment in the setting of heart and hematopoietic stem cell transplantation (HCST) [3, 4]. Herein we describe a case of a 27-year-old man who developed facial SH five months after completing cyclosporine therapy for cutaneous graft versus host disease (GVHD) following HSCT.

**Case synopsis**

A 27-year-old man presented 26 months status post match-unrelated HCST for treatment of acute lymphocytic leukemia (ALL) for evaluation of a flesh-colored papular eruption over his face that began approximately one year prior. The lesions were asymptomatic and the patient did not have any history of acne or other skin conditions. Treatment with over-the-counter facial exfoliants had failed to produce any improvement over the past several months. In addition to his prior HSCT for ALL, the patient's medical history was significant for alopecia involving his scalp, eyebrows, and facial hair. In addition, he exhibited areas

of acquired depigmentation of his face, scalp, and trunk, which had developed in the setting of acute Grade 4 cutaneous graft-versus-host disease (GVHD) one month following HSCT. His GVHD had been treated with extracorporeal photopheresis, high-dose prednisone (tapered off over the course of six months), cyclosporine 10 mg/kg daily, and mycophenolate mofetil 2 grams/day (both tapered off over the course of nine months). Approximately four weeks after discontinuation of the cyclosporine and mycophenolate mofetil, he experienced a recurrence of acute cutaneous GVHD that resolved over six months with topical clobetasol 0.05% ointment. Five months after completing cyclosporine and mycophenolate mofetil therapy, the patient noticed the appearance of multiple fine flesh-colored papules over his face, which had remained stable in appearance since onset. He otherwise felt well without any systemic or gastrointestinal symptoms. His current medications were daily acyclovir and posaconazole for prophylaxis.

**Physical Examination:** Multiple monomorphic, 1-3 mm yellow to flesh colored papules were noted over the patient's face in a follicular distribution (Figure 1). Alopecia and hypopigmentation were noted over the scalp, face and trunk and the patient's eyelashes were also depigmented. Oral examination revealed normal mucosa with no lesions and the remainder of the examination, including assessment of his neurologic and musculoskeletal systems was within normal limits. Biopsy of a cheek papule revealed prominent sebaceous gland lobules (Figure 2).



**Figure 1.** Clinical presentation. Fine, monomorphic flesh-toned papules are noted in a follicular distribution over the patient's face. **Figure 2.** Biopsy of a papule showing a hyperplastic sebaceous gland on hematoxylin-eosin staining (magnification 100X).

**Laboratory Data:** Laboratory evaluation revealed a white blood cell count of 4800/ $\mu$ l (reference range 4500-11,000/ $\mu$ L), hemoglobin level of 12.9 mg/dL (reference range 14.0-18.0 mg/dL) and a platelet count of  $157 \times 10^3$ / $\mu$ L (reference range  $130 \times 10^3$ / $\mu$ L to  $400 \times 10^3$ / $\mu$ L). A hepatic function panel was significant for slight elevations in alkaline phosphatase at 123 U/dL (reference range 35-115 U/dL) and aspartate transaminase at 73 U/dL (reference range 15-43 U/dL). Results of a serum chemistry panel were all within normal range.

## Discussion

Sebaceous hyperplasia (SH) is a benign condition characterized by the appearance of multiple yellowish or flesh-colored, umbilicated papules [5]. The lesions commonly occur on the face, but have also been described in other locations including the chest and groin [5, 6]. The incidence of sporadic or senile SH increases with advancing age and is seen most commonly in middle-aged (40 to 50 years) or older adults [7]. There are several major forms of SH including senile SH, functional familial SH, iatrogenic SH as a result of cyclosporine treatment and SH occurring as part of Muir-Torre syndrome (MTS). MTS is a rare autosomal dominant condition characterized by the presence of sebaceous neoplasms and/or keratoacanthomas in conjunction with internal malignancies (most commonly colon adenocarcinoma) [3, 8, 9].

Decreased levels of circulating androgens are postulated to be a major underlying cause of the senile form of SH, leading to a reduced rate of cellular turnover within the sebaceous glands and subsequent accumulation of sebocytes resulting in glandular enlargement and a decrease in the rate of sebum production [10]. Photoaging is considered to be an important cofactor in the development of SH in adults. Supporting this notion is the finding that exposure to ultraviolet radiation (namely UVA) has been

demonstrated to induce SH in a nude mouse model [11]. In contrast, the familial variant of SH characteristically presents prior to the onset of puberty as thick plaques sparing the preauricular, periorbital, and perinasal areas [8].

Cyclosporine-induced SH has been primarily described in renal transplant patients with several large published case series in the literature [1, 3, 12-14]. However, it has also been reported in patients following cardiac, liver, and HSC transplantation [3, 4, 15]. An increased frequency of pilosebaceous lesions in renal transplant patients including SH, hypertrichosis, acne, and epidermal cysts was first described by Bencini and colleagues in 1986. In their review of 100 patients, 10% were noted to have SH [12]. De Berker and colleagues analyzed a large series of 104 heart transplant patients and found that 16% of the transplant patients had SH as compared to 1% of an age and sex-matched control group. All of the transplant patients with SH were male and were on concurrent cyclosporine, at an average dose of 5.1 mg/kg/day [3]. Salim et al performed a similar analysis in 117 renal transplant patients and found a 30% prevalence of SH in the transplanted group compared to 24% in an age and sex-matched control group [1]. Although SH in the setting of transplantation has been associated with male gender, a series by Salim et al also reported SH in female patients (both transplant and matched controls), albeit at a significantly lower rate than that observed in their male counterparts (15.4% and 7.7% in female transplant and control patients versus 37% and 32% respectively in male transplant and control patients) [1]. The increased incidence of SH in organ transplant patients is postulated to relate primarily to the direct effects of cyclosporine on the pilosebaceous unit, as similarly increased rates of SH have not been observed in patients on other immunosuppressive medications such as azathioprine or prednisolone [1, 3]. In the series by De Berker et al, all the transplant patients with SH were taking cyclosporine [3]. In the analysis by Salim et al, SH was observed in transplant patients who were not on cyclosporine, but the prevalence was significantly lower than that of cyclosporine-treated patients (19% versus 37%) and comparable to that of the age and sex-matched control patients (24%) [1]. A summary of the cutaneous side effects of cyclosporine (including SH) observed in renal transplant patients treated with cyclosporine is provided in Table 1.

**Table 1.** Summary of Cutaneous Adverse Effects of Cyclosporine in Renal Transplant Patients

Adverse Effect	Frequency of Occurrence
Hirsutism	9.2% [16]
Sebaceous Hyperplasia	30% [1]
Acne	2.6% [16]
Hyperpigmentation	Case report [17]

Cyclosporine is a lipophilic medication and thus accumulates in the body lipid stores as well as in the skin, correlating with the high frequency of cutaneous side effects involving the pilosebaceous units [18, 19]. Zouboulis and Boschnakow examined the histological changes seen in patients with SH over time as a result of normal aging, as well as SH in the setting of organ transplantation and cyclosporine administration [2, 10]. In senile SH, an age-related decrease in androgen stimulation leads to reduced cellular turnover within the sebaceous glands and enlargement of the sebaceous lobules [10]. In contrast, cyclosporine appears to induce hyperproliferation of undifferentiated sebocytes while inhibiting their differentiation into mature sebum-producing cells. As a result of this stimulatory effect on immature sebocytes, cyclosporine-induced SH is characterized by multilayered basal cells at the periphery of the sebaceous lobules and a relative paucity of differentiated sebocytes [2].

The majority of described cases of cyclosporine-induced SH occurred in patients who were currently on the medication [1, 3, 12]. However, Chin et al reported a case of SH in a renal transplant patient on sirolimus that developed five years after discontinuation of long-term (15 year) cyclosporine therapy [20]. In this case, the patient first noted the appearance of facial papules approximately five months after completing nine months of cyclosporine therapy for his GVHD.

Various procedural treatment modalities exist for SH, including surgical excision/curettage, cryotherapy, electrodesiccation, laser treatment (pulsed-dye, CO2 and diode), and chemical peels (trichloroacetic and bichloroacetic acids) [21-25]. However, potential complications of these procedural methods include scarring and pigmentation changes. Oral isotretinoin and photodynamic therapy (PDT) with visible light and 5-aminolevulinic acid (ALA) have been described as non-surgical treatments for SH. Isotretinoin promotes apoptosis and cell cycle arrest in sebocytes, which is its presumed mechanism of action in treating SH [26]. For isotretinoin monotherapy, doses ranging from 0.3-1mg/kg daily have been described for the treatment of both cyclosporine-induced and familial SH [3, 26, 27]. However, lesions often recur following cessation of isotretinoin therapy. In the case of

phototherapy, the lipophilic nature of ALA promotes accumulation in the pilosebaceous units and allows targeting of the sebaceous glands. The published phototherapy regimens for SH range from 2-3 sessions, with reported durations of response between 6 and 12 months [28, 29].

## Conclusion

Sebaceous hyperplasia (SH) is a well-documented cutaneous adverse effect of cyclosporine administration in recipients of both solid organ and hematopoietic stem cell (HSC) transplants. Cyclosporine-induced SH has been found to be histologically distinct from SH owing to normal aging. In this situation, a predominance of undifferentiated sebocytes is seen within the sebaceous lobules and is thought to be the result of a stimulatory effect of the medication on sebaceous glands. A variety of treatment modalities may be utilized for SH including surgical excision/curettage, electrodesiccation, laser treatments (pulsed dye, CO<sub>2</sub>, and diode), phototherapy (PDT), and oral isotretinoin.

## References

1. Salim, A., et al., Sebaceous hyperplasia and skin cancer in patients undergoing renal transplant. *J Am Acad Dermatol*, 2006. 55(5): p. 878-81.
2. Boschnakow, A., et al., Cyclosporin A-induced sebaceous gland hyperplasia. *Br J Dermatol*, 2003. 149(1): p. 198-200.
3. de Berker, D.A., et al., Sebaceous hyperplasia in organ transplant recipients: shared aspects of hyperplastic and dysplastic processes? *J Am Acad Dermatol*, 1996. 35(5 Pt 1): p. 696-9.
4. Marini, M., et al., Eruptive lesions in a patient with bone marrow transplantation. *Int J Dermatol*, 2001. 40(2): p. 133-5.
5. Eisen, D.B. and D.J. Michael, Sebaceous lesions and their associated syndromes: part I. *J Am Acad Dermatol*, 2009. 61(4): p. 549-60; quiz 561-2.
6. Ma, H.J., G. Zhao, and Y.X. Wang, Sebaceous hyperplasia of the scrotum in an adolescent boy. *Pediatr Dermatol*, 2007. 24(3): p. 340-2.
7. Plewig, G. and A.M. Kligman, Proliferative activity of the sebaceous glands of the aged. *J Invest Dermatol*, 1978. 70(6): p. 314-7.
8. Dupre, A., J.L. Bonafe, and P. Lamon, Functional familial sebaceous hyperplasia of the face and premature sebaceous gland hyperplasia: a new and unique entity. *J Am Acad Dermatol*, 1983. 9(5): p. 768-9.
9. Schwartz, R.A. and D.P. Torre, The Muir-Torre syndrome: a 25-year retrospect. *J Am Acad Dermatol*, 1995. 33(1): p. 90-104.
10. Zouboulis, C.C. and A. Boschnakow, Chronological ageing and photoageing of the human sebaceous gland. *Clin Exp Dermatol*, 2001. 26(7): p. 600-7.
11. Lesnik, R.H., L.H. Kligman, and A.M. Kligman, Agents that cause enlargement of sebaceous glands in hairless mice. II. Ultraviolet radiation. *Arch Dermatol Res*, 1992. 284(2): p. 106-8.
12. Bencini, P.L., et al., Cutaneous lesions in 67 cyclosporin-treated renal transplant recipients. *Dermatologica*, 1986. 172(1): p. 24-30.
13. Lugo-Janer, G., J.L. Sanchez, and E. Santiago-Delpin, Prevalence and clinical spectrum of skin diseases in kidney transplant recipients. *J Am Acad Dermatol*, 1991. 24(3): p. 410-4.
14. Chen, Q.P. and D.C. Aw, Epidemiology of skin diseases in renal transplant recipients in a tertiary hospital. *Ann Acad Med Singapore*, 2010. 39(12): p. 904-5.
15. Salard, D., et al., [Cutaneous complications following liver transplantation: epidemiologic and clinical study in 86 patients]. *Ann Dermatol Venereol*, 2002. 129(10 Pt 1): p. 1134-8.
16. Pharmaceuticals, N., Package Insert for Sandimmune (Cyclosporine) capsules (25 and 100 mg), Oral (100 mg/mL) and Injection (50 mg/mL) Solutions. March 2015.
17. Brady, A.J. and A.J. Wing, Hyperpigmentation due to cyclosporin therapy. *Nephrol Dial Transplant*, 1989. 4(4): p. 309-10.
18. Wagner, O., et al., Tissue distribution, disposition, and metabolism of cyclosporine in rats. *Drug Metab Dispos*, 1987. 15(3): p. 377-83.
19. Pang, S.M. and Y.P. Chau, Cyclosporin-induced sebaceous hyperplasia in renal transplant patients. *Ann Acad Med Singapore*, 2005. 34(5): p. 391-3.
20. Chin, M. and A. Anstey, Sebaceous hyperplasia in a renal transplant patient on sirolimus. *J Am Acad Dermatol*, 2013. 68(4, Supplement 1): p. AB141.
21. Wheeland, R.G. and M.D. Wiley, Q-tip cryosurgery for the treatment of senile sebaceous hyperplasia. *J Dermatol Surg Oncol*, 1987. 13(7): p. 729-30.
22. Bader, R.S. and D.A. Scarborough, Surgical pearl: intralesional electrodesiccation of sebaceous hyperplasia. *J Am Acad Dermatol*, 2000. 42(1 Pt 1): p. 127-8.
23. Schonermack, M.P., C. Schmidt, and C. Raulin, Treatment of sebaceous gland hyperplasia with the pulsed dye laser. *Lasers Surg Med*, 1997. 21(4): p. 313-6.
24. No, D., et al., Sebaceous hyperplasia treated with a 1450-nm diode laser. *Dermatol Surg*, 2004. 30(3): p. 382-4.

25. Walther, T., U. Hohenleutner, and M. Landthaler, [Sebaceous gland hyperplasia as a side effect of cyclosporin A. Treatment with the CO2 laser]. *Dtsch Med Wochenschr*, 1998. 123(25-26): p. 798-800.
26. McDonald, S.K., M.S. Goh, and A.H. Chong, Successful treatment of cyclosporine-induced sebaceous hyperplasia with oral isotretinoin in two renal transplant recipients. *Australas J Dermatol*, 2011. 52(3): p. 227-30.
27. Grimalt, R., J. Ferrando, and J.M. Mascaró, Premature familial sebaceous hyperplasia: successful response to oral isotretinoin in three patients. *J Am Acad Dermatol*, 1997. 37(6): p. 996-8.
28. Horio, T., et al., Photodynamic therapy of sebaceous hyperplasia with topical 5-aminolaevulinic acid and slide projector. *Br J Dermatol*, 2003. 148(6): p. 1274-6.
29. Perrett, C.M., et al., Topical photodynamic therapy with methyl aminolevulinate to treat sebaceous hyperplasia in an organ transplant recipient. *Arch Dermatol*, 2006. 142(6): p. 781-2.