

Case Presentation

Disseminated Herpes Simplex Virus presenting as crusted papules on the palms and soles of an immunosuppressed patient

Whitney Fancher MD¹, Amanda Marsch MD¹, John Landers MD^{1,2}, Jane Scribner MD^{1,2}

Dermatology Online Journal 20 (9): 6

¹University of Illinois at Chicago

²James A. Lovell Federal Health Care Center, Department of Dermatology

Correspondence:

Whitney Fancher, M.D.
University of Illinois at Chicago
Department of Dermatology
Phone: 417-848-6148
Fax: (312) 996-1188
Email: whitneyfancher@gmail.com
University of Illinois at Chicago
808 S. Wood St. Chicago, IL 60612

Abstract

Disseminated Herpes Simplex Virus (HSV) may occur in immunosuppressed patients, most commonly causing visceral organ involvement and rarely presenting solely with cutaneous lesions. We report an interesting case of disseminated HSV in a 77-year-old immunocompromised man, presenting as necrotic papules and pustules with no associated systemic involvement.

Keywords: HSV, Herpes Simplex Virus, immunosuppressed, papulonecrotic

Case synopsis

A 77 year-old man, with a history of chronic obstructive pulmonary disease (COPD) on chronic immunosuppression with daily prednisone, presented with new-onset asymptomatic papules on his extremities shortly after hospitalization for a COPD exacerbation. The patient denied pain, fevers, or chills, and otherwise felt healthy except for the “black spots” present on his palms and soles. Examination revealed necrotic, crusted papules on his bilateral palms and soles (Figure 1) and sparse deep-seated hemorrhagic vesicopustules. On his anterior legs, there were scattered hemorrhagic ulceronecrotic papules. His lower lip revealed a large crusted plaque (Figure 2). Laboratory workup revealed a normal complete metabolic profile and complete blood count. A serum RPR was negative. Three punch biopsies were performed from the right palm, left leg, and left foot and sent for routine hematoxylin and eosin (H&E) staining and bacterial and fungal cultures.

Histopathology revealed a discrete intraepidermal blister cavity containing ballooned keratinocytes with ground glass nuclear inclusions, multi-nucleated giant cells, and nuclear molding (Figure 3). Immunohistochemical stains were performed with HSV-1, HSV-2, and Varicella. HSV-1 staining revealed diffuse strong positivity (Figure 4); the other two stains were negative.

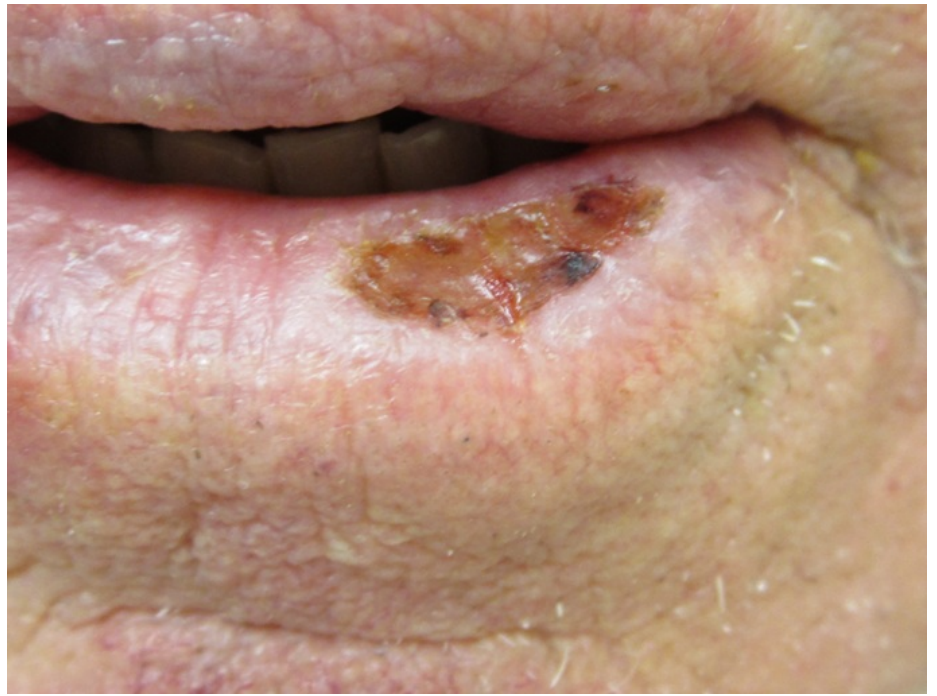
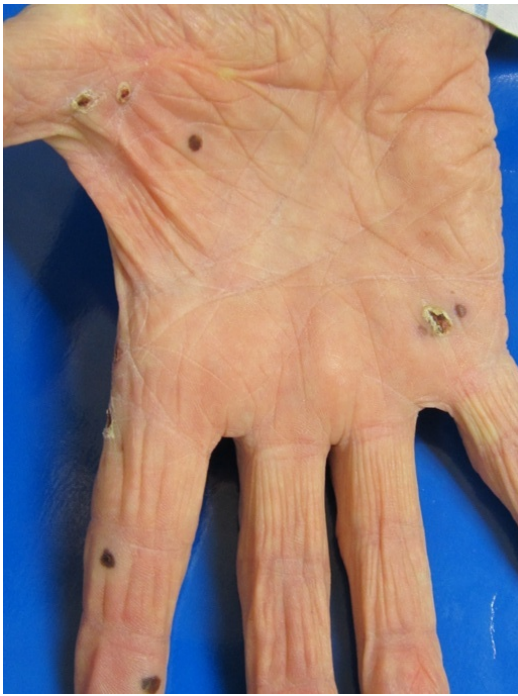

Figure 1. Crusted, hemorrhagic papules on the palms **Figure 2.** A crusted ulceration on the lower lip

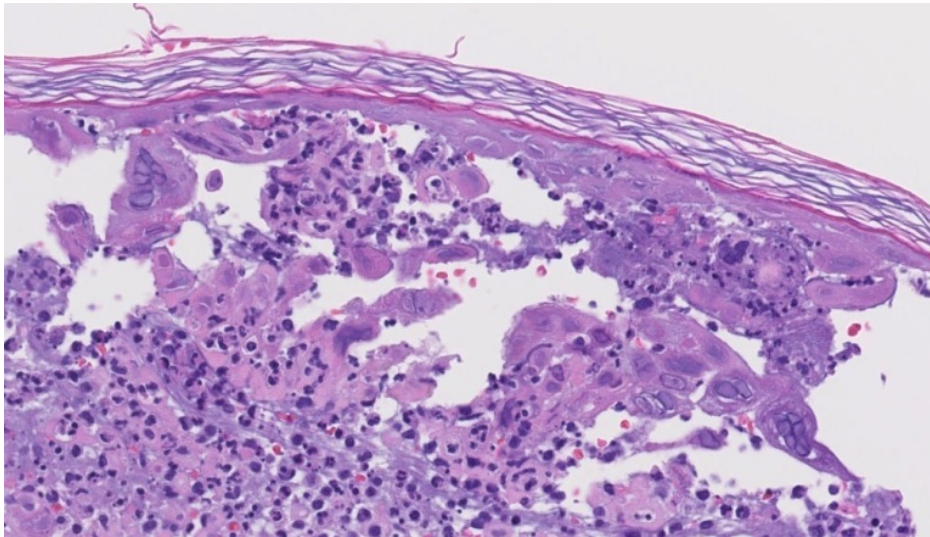


Figure 3. (H&E, 20X) Ballooned keratinocytes with ground glass nuclear inclusions, multi-nucleated giant cells, and nuclear molding were seen within the blister cavity.

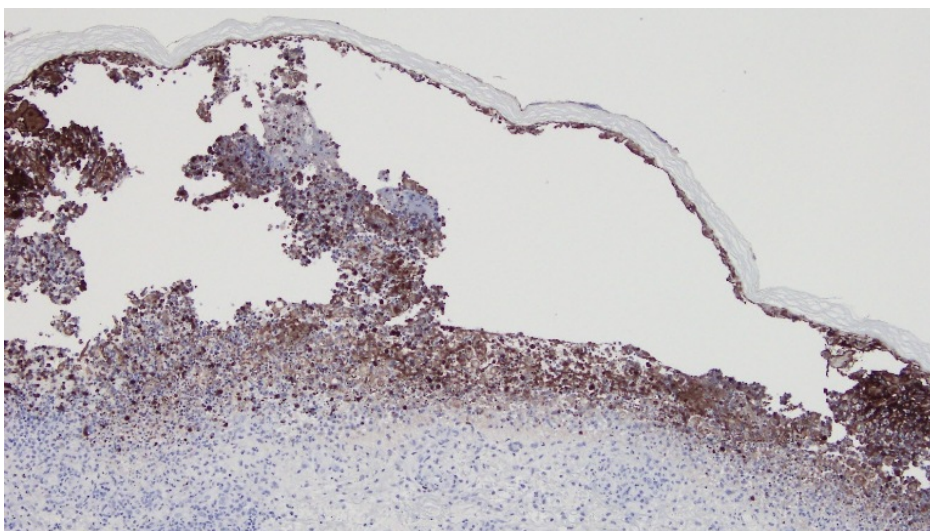


Figure 4. (HSV-1, 10X) HSV-1 immunostaining showed strong positivity within the blister cavity.

Discussion

After primary exposure, HSV-1 or 2 viruses become latent in sensory neurons localized to the skin or mucosa of the lips and genitals [1]. Approximately 60-90% of the population has seropositivity to the HSV-1 virus [2,3]. Reactivation of HSV-1 from the trigeminal ganglia is accompanied by asymptomatic shedding of the virus into saliva and the subsequent development of herpetic ulcerations on the vermilion border of the lip or external facial skin [1]. In immunosuppressed patients, especially those with defective cell-mediated immunity, cutaneous infection with herpes simplex, whether recurrent or primary, can lead to disseminated disease [4]. The virus most likely disseminates via the bloodstream, as previous studies have demonstrated viral DNA present in the peripheral blood during acute herpes labialis [4]. Disseminated disease in immunosuppressed hosts most commonly leads to visceral organ involvement with resultant fulminant hepatitis [1,5], encephalitis, and pneumonia [3]. Dissemination of HSV most frequently occurs in patients with hematologic malignancy, followed by those with bone marrow and organ transplants [6]. The reports of disseminated HSV-2 infections in solid organ transplant patients were all associated with visceral organ involvement [5].

The mode of disseminated cutaneous HSV infection without systemic involvement is somewhat unclear, although it is known that extension of the infection into mucosal or deep cutaneous layers can occur in immunosuppressed patients [1]. Solely cutaneous dissemination of HSV is exceedingly rare. Recently, a patient with Crohn disease developed disseminated cutaneous HSV infection in the context of double immunosuppression (corticosteroids and azathioprine) [2]. In this case, cutaneous dissemination was manifested as scattered papules, vesicles, and pustular lesions in different stages of evolution on the upper limbs and trunk, mimicking chickenpox. However, this patient had no mucosal lesions and the patient had constitutional symptoms such as fever. Another reported case of cutaneous disseminated HSV-1 occurred again in the context of triple immunosuppression (methotrexate, prednisone, and infliximab) in a woman with rheumatoid arthritis [3]. This patient also presented with constitutional symptoms (fever) and a generalized cutaneous vesicular eruption characteristic of HSV infection.

In contrast to previous reports of cutaneous dissemination of HSV-1, our patient had no associated constitutional symptoms and had a unique confounding morphology of necrotic, crusted papules and hemorrhagic pustules. We suspect that the purpuric nature of his lesions may have been related to his warfarin use. However, the palpable nature of most of the lesions suggested an underlying inflammatory component.

Upon diagnosis, our patient was hospitalized and treated with IV acyclovir; a full systemic workup revealed no evidence of systemic disease. After an uncomplicated hospitalization, the patient was discharged and followed-up in clinic. Many of his skin lesions had resolved and his lip ulceration was completely healed. Viral serologies were obtained. Both HSV-1 and Varicella IgG confirmed evidence of prior infection and elevated HSV-1 IgM confirmed the diagnosis of recent HSV infection. Subsequently, the patient developed recurrent papules on his hands. Given that his immune status will not likely change, we recommended that the patient be placed on suppressive doses of acyclovir.

Although primary infections with HSV-1 are usually associated with systemic signs and symptoms [1], recurrent herpes labialis with subsequent cutaneous dissemination can be asymptomatic, as demonstrated in our patient. Additionally, cutaneous dissemination of HSV-1 should be added to the differential diagnosis of papulonecrotic lesions. We feel this patient's case is unique owing to the lack of systemic symptoms or involvement and the unique morphology that was not initially suggestive of herpes virus infection.

References

1. Corey L, Spear PG. Infections with herpes simplex viruses (1). *N Engl J Med*. 1986;314(11):686-91. [PMID: 3005858]
2. Santos-Antunes J, Abreu C, Magro F, Coelho R, Vilas-Boas F, Andrade P, et al. Disseminated cutaneous herpes simplex infection in a patient with Crohn's disease under azathioprine and steroids: First case report and literature review. *Journal of Crohn's & colitis*. 2014;8(4):326-30. [PMID:24257435]
3. Justice EA, Khan SY, Logan S, Jobanputra P. Disseminated cutaneous Herpes Simplex Virus-1 in a woman with rheumatoid arthritis receiving infliximab: a case report. *Journal of medical case reports*. 2008;2:282. [PMID:18727822]
4. Brice SL, Stockert SS, Jester JD, Huff JC, Bunker JD, Weston WL. Detection of herpes simplex virus DNA in the peripheral blood during acute recurrent herpes labialis. *J Am Acad Dermatol*. 1992;26(4):594-8. [PMID:1317892]
5. Basse G, Mengelle C, Kamar N, Ribes D, Selves J, Cointault O, et al. Disseminated herpes simplex type-2 (HSV-2) infection after solid-organ transplantation. *Infection*. 2008;36(1):62-4. [PMID:18165863]
6. Krishnam AS, Sachan Y, Rani GG. Co-reactivation of varicella zoster virus and herpes simplex virus with disseminated cutaneous lesions in a lymphoma patient. *Indian J Dermatol Venereol Leprol*. 2013;79(5):709-11. [PMID:23974591]