

# UC Davis

## Dermatology Online Journal

### Title

Capillary hemangioma associated with dermal atrophy masquerading as a deep fungal infection

### Permalink

<https://escholarship.org/uc/item/4109m7ds>

### Journal

Dermatology Online Journal, 24(3)

### Authors

Strunck, Jennifer L  
Florell, Scott R  
Grossman, Douglas

### Publication Date

2018

### DOI

10.5070/D3243038621

### Copyright Information

Copyright 2018 by the author(s). This work is made available under the terms of a Creative Commons Attribution-NonCommercial-NoDerivatives License, available at <https://creativecommons.org/licenses/by-nc-nd/4.0/>

Peer reviewed

# Capillary hemangioma associated with dermal atrophy masquerading as a deep fungal infection

Jennifer L Strunck<sup>3</sup> BS, Scott R Florell<sup>1</sup> MD and Douglas Grossman<sup>1,2,3</sup> MD PhD

Affiliations: <sup>1</sup>Department of Dermatology, University of Utah Health Sciences Center, Salt Lake City, Utah, USA, <sup>2</sup>Department of Oncological Sciences University of Utah Health Sciences Center, Salt Lake City, Utah, USA, <sup>3</sup>Huntsman Cancer Institute, University of Utah Health Sciences Center, Salt Lake City, Utah, USA

Corresponding Author: Doug Grossman, Huntsman Cancer Institute, 2000 Circle of Hope, Salt Lake City, UT 84112, Tel: 801-581-4682, Email: [doug.grossman@hci.utah.edu](mailto:doug.grossman@hci.utah.edu)

## Abstract

Hemangiomas are benign vascular neoplasms which arise in early adulthood. Herein we present a 79-year-old woman with a hemangioma of the lower flank masquerading as a cutaneous manifestation of a systemic fungal infection upon initial histological analysis. Decreased elastin and collagen within the lesion likely accounted for the clumping and splaying of the capillaries into "hyphae-like" structures. Loss of dermal elastic tissue and collagen apparently concentrated the capillary proliferation into an unusual morphology mimicking the hyphal structures. Through additional staining methods the lesion was confirmed to be an unusual presentation of a capillary hemangioma.

Keywords: hemangioma, fungal, CD31, FLI-1

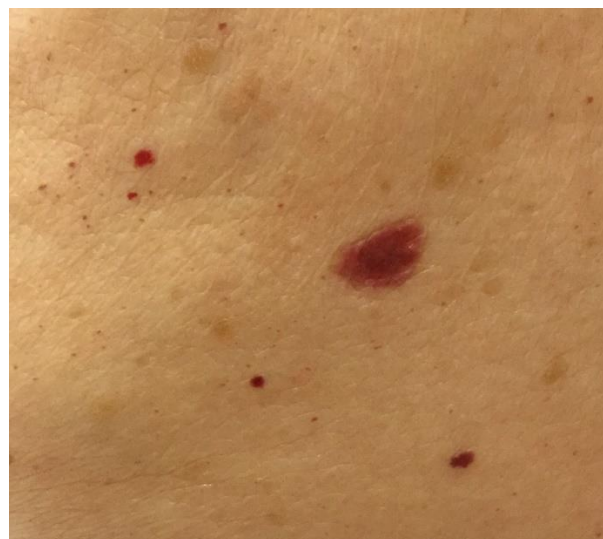## Introduction

Small hemangiomas are commonly seen in adults. Herein we present an elderly patient with a hemangioma of the lower flank masquerading as a cutaneous manifestation of a systemic fungal infection upon initial histological analysis. Through additional staining methods the lesion was confirmed to be an unusual presentation of a capillary hemangioma.

## Case Synopsis

A 79-year-old woman presented to the dermatology clinic with an asymptomatic 1.3 x 0.8 cm non-tender

plaque on the left lower flank. The color was not uniform throughout the lesion; it was red peripherally and a darker violaceous color centrally. There was no history of trauma, intraslesional steroid injection, or application of topical steroids. Surrounding the lesion were multiple additional small red papules (**Figure 1**). The patient's medical history included squamous cell carcinoma treated with 5-fluorouracil and Sjogren syndrome treated with oral hydroxychloroquine and ophthalmic suspensions of loteprednol etabonate and latanoprost. The initial clinical differential diagnosis included basal cell carcinoma and amelanotic melanoma. A shave biopsy of the plaque was performed.



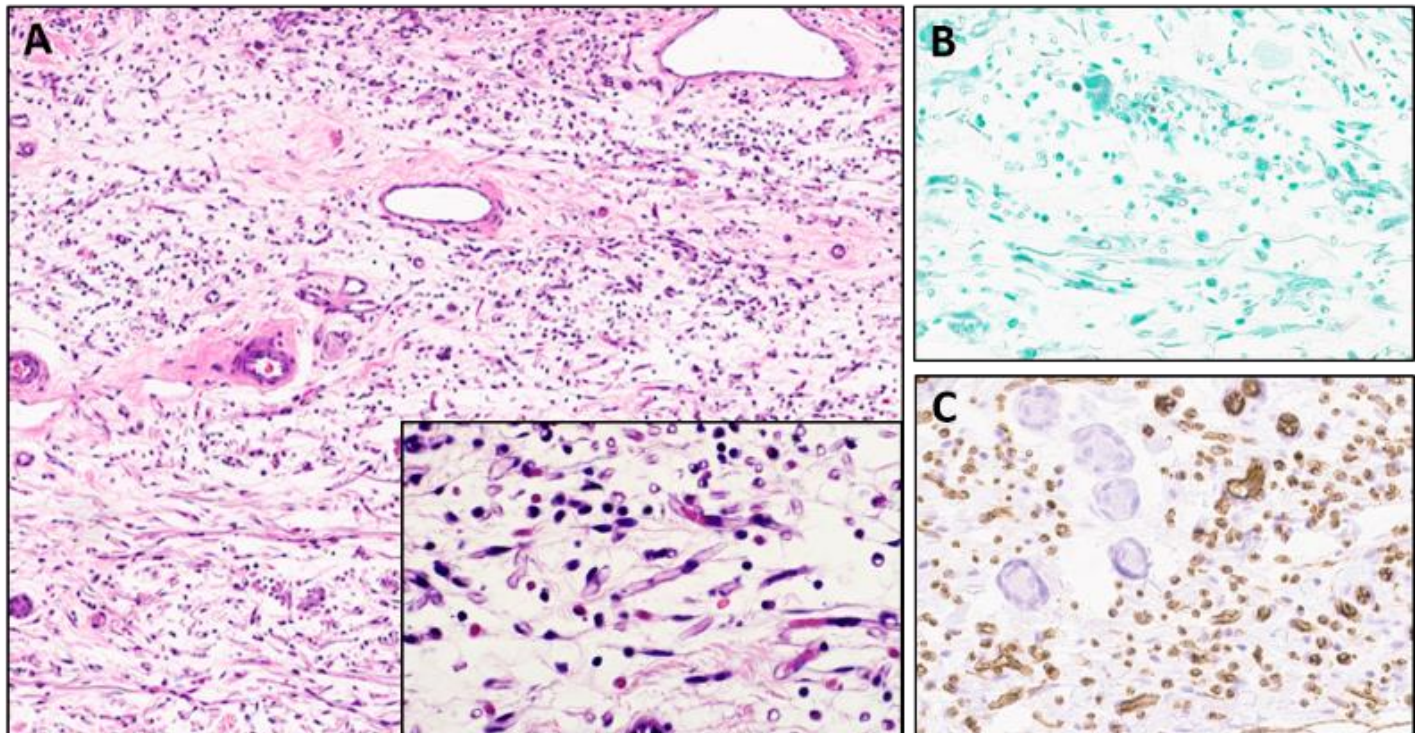
**Figure 1.** Clinical presentation. Red-violaceous plaque on the flank.

Histopathologic examination of serial sections revealed small vascular spaces in the setting of dermal edema and atrophy without significant signs of solar damage (**Figure 2A**). Within the dermis were tubular structures resembling fungal hyphae that also contained erythrocytes and occasional cell nuclei (**Figure 2A**, inset). Technically-adequate staining with GMS, with appropriately staining control material, was negative (**Figure 2B**). Similarly, staining for PAS was also negative (not shown). Staining for CD31 highlighted endothelial cells lining capillaries (**Figure 2C**), confirming the presence of a dermal proliferation of small, thin walled blood vessels diagnostic for capillary hemangioma. A similar staining pattern was seen for FLI-1 (not shown). No significant staining was noted for HHV-8, S100, or cytokeratin 5/6 (not shown). Finally, an EVG elastic stain showed decreased elastic tissue in the area of capillary proliferation, and a trichrome stain showed decreased collagen fibers in this area (not shown).

## Case Discussion

Hemangiomas are composed of endothelial cell proliferations and are further sub-classified based on histological appearance into capillary hemangiomas, cavernous hemangiomas, and mixed hemangiomas [1]. Smaller lesions are also commonly seen in adults. Interestingly, the unusual lesion we describe was surrounded by smaller clinically apparent hemangiomas, possibly indicating a field effect of vascular proliferations in this area.

There have been numerous reported cases describing hemangiomas clinically masquerading as other entities. Prior cases have described hemangiomas mimicking peripheral ossifying fibroma, pyogenic granuloma, lipoma, angiosarcoma, squamous cell carcinoma, and Kaposi sarcoma. However, in all these cases a diagnosis of hemangioma was readily apparent upon routine histopathological examination [3-5]. There are also reports of malignancies such as cutaneous metastasis of lung carcinoma [6] and mycosis fungoides [6] clinically mimicking fungal infections. However, in these cases fungal infections were ruled out by histologic examination. Histologic mimics of



**Figure 2.** Skin biopsy specimen findings consistent with hemangioma. A) H&E stain (100x), showing vascular spaces; inset (400x), showing hyphae-like structures. B) GMS stain (100x), showing no reactivity. C) CD31 stain (100x), showing reactivity of endothelial-lined structures.

fungal infections that have been reported include filter debris resembling pseudo-hyphal elements in the cytological examination of cerebrospinal fluid [7] and “lollipop lesions” consisting of sclerotic amorphous eosinophilic bodies with entrapped elastic fibers seen in nephrogenic systemic fibrosis [8].

This case is unusual because initial histological examination suggested a cutaneous fungal infection as commonly seen in immunocompromised patients given the presence of structures resembling hyphae. However, both PAS and GMS stains were negative ruling out the possibility of a fungal infection. Further staining for S-100, cytokeratins, and HHV-8 were negative and ruled out amelanotic melanoma, squamous cell carcinoma, and Kaposi sarcoma, respectively. Positive immunostaining for CD31 and FLI-1 identified endothelial cells lining capillaries and confirmed a diagnosis of a capillary hemangioma. Decreased elastin and collagen within the lesion, demonstrated by decreased EVG and trichrome staining, was the structural basis for the atrophy,

which likely accounted for the clumping and splaying of the capillaries into “hyphae-like” structures. The cause of the atrophy is unclear, as the lesion had not been previously treated with steroids. Loss of dermal elastic tissue and collagen apparently concentrated the capillary proliferation into an unusual morphology mimicking the hyphal structures.

We were unable to find any other cases of a hemangioma histologically mimicking a fungal infection and so we point out this potential pitfall. This case highlights the importance of utilizing specialized stains in cases in which the diagnosis is not readily apparent on H&E staining.

## Conclusion

We present an unusual case of a hemangioma histologically mimicking a fungal infection that was resolved through use of special stains.

## References

1. Bauland CG, van Steensel MA, Steijlen PM, Rieu PN, Spauwen PH. The pathogenesis of hemangiomas: a review. *Plast Reconstr Surg*. 2006;117:9e-35e. [PMID: 16462311].
2. Reddy KV, Roohi S, Maloth KN, Sunitha K, Thummala VS. Lipoma or hemangioma: A diagnostic dilemma? *Contemp Clin Dent*. 2015;6:266-269. [PMID: 26097370].
3. Singh P, Parihar AS, Siddique SN, Khare P. Capillary haemangioma on the palate: a diagnostic conundrum. *BMJ Case Rep*. 2016; Feb 16;2016. pii: bcr2015210948. [PMID: 26884070].
4. Patil A, Pattanshetti C, Varekar A, Huddar SB. Oral capillary haemangioma mimicking pyogenic granuloma: a challenge for diagnosis and management. *BMJ Case Rep*. 2013; Feb 14;2013. pii: bcr2012007874. [PMID: 23417375].
5. Ladizinski B, Alavi A, Jambrosic J, Mistry N, Sibbald GR. Cancers Mimicking Fungal Infections. *Adv Skin Wound Care*. 2014;27:301–09. [PMID: 24932950].
6. Martínez-Girón R, Martínez-Torre C. Millipore™ filter debris mimicking fungal organisms in CSF cytology. *Diagn Cytopathol*. 2017;45:545-46. [PMID: 28371530].
7. Grekin SJ, Holcomb MJ, Modi GM, Huttenbach YT, Poythress EL, Diwan AH. Lollipop lesions in nephrogenic systemic fibrosis mimicking a deep fungal infection. *J Cutan Pathol*. 2012;39:981-84. [PMID: 23072417].