

# Acquired Darier disease in a patient with metastatic prostate cancer: a paraneoplastic process?

Abirami Pararajasingam BSc MBChB (Hons) MRCP, Nabil Ponnambath MBBS MD MRCP FRCP

Affiliations: Department of Dermatology, Aneurin Bevan University Health Board, Newport, UK

Corresponding Author: Abirami Pararajasingam, Department of Dermatology, St Woolos Hospital, 131 Stow Hill, Newport, NP20 4SZ, UK, Tel: 44-1633 234234, E-mail: [apararajasingam@nhs.net](mailto:apararajasingam@nhs.net)

## Abstract

Darier disease is considered a hereditary acantholytic dermatosis that is inherited in an autosomal dominant manner and usually manifests in the first or second decade of life. We describe a 62-year-old man with an acquired variant of Darier disease after a recent diagnosis of metastatic prostate cancer. We discuss and postulate a novel mechanism for this unusual presentation.

*Keywords: Darier disease, acantholysis, paraneoplastic syndrome*

## Introduction

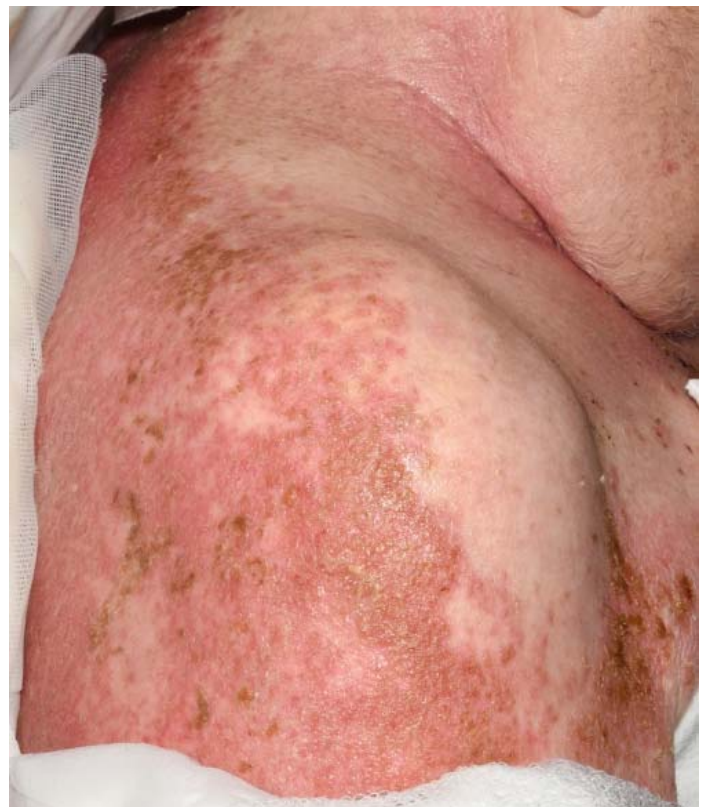Darier disease, described independently by White and Darier in 1889, is a disorder of keratinization usually involving the skin and nails. The condition is believed to arise because of a mutation in the *ATP2A2* gene and typically manifests in the first and second decades of life [1]. It is characterized by persistent, greasy, scaly papules involving seborrheic sites. The linear form of Darier disease is caused by acquired somatic mutations in the *ATP2A2* gene and presents with localized cutaneous changes. Cases of non-localized acquired Darier disease are extremely rare.

## Case Synopsis

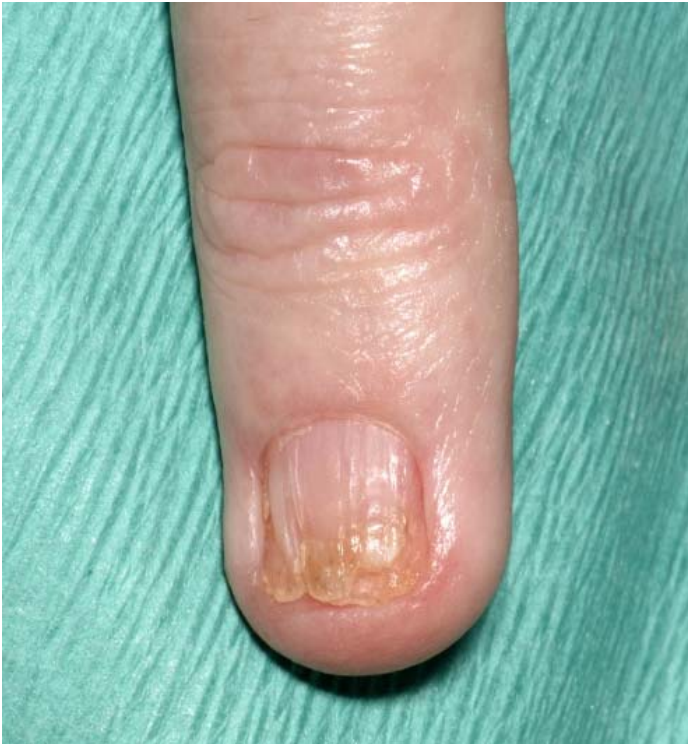A 62-year-old man was referred to our dermatology department with a three-month history of an asymptomatic rash involving the face, torso, and

groin. The patient had a past medical history of asthma and a recent diagnosis of metastatic prostate cancer. His regular medications consisted of tramadol, amitriptyline, and leuprorelin (hormonal therapy). There was no personal or family history of any skin disorders.

Physical examination revealed erythematous and brown verrucous papules on the post-auricular and nasolabial area as well as the eyebrows, upper back, central chest, lower abdomen, and groin (**Figure 1**).



**Figure 1.** Erythematous verrucous papules involving the back and extending to the posterior neck.



**Figure 2.** Fingernail demonstrating longitudinal ridges and V-shaped nick at the free edge.

There was evidence of crusting and erosions on the right side of the neck and lower abdomen. The nails were brittle and demonstrated longitudinal ridges with red lines and a V-shaped nick at the free edge (**Figure 2**).

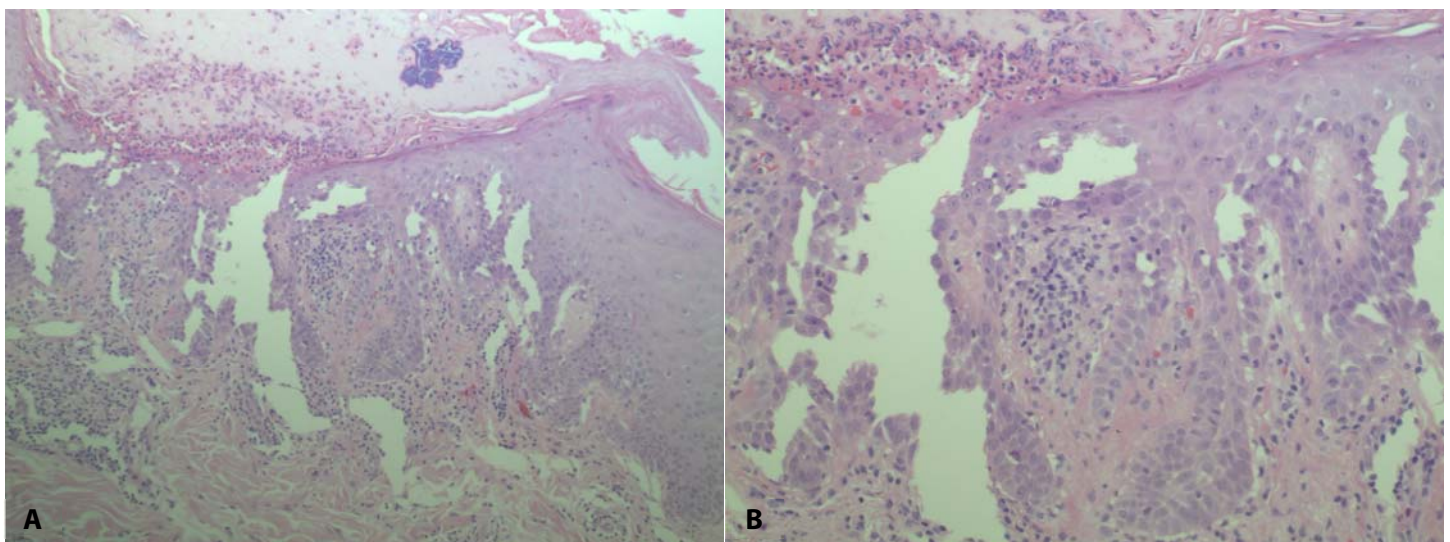
The initial clinical impression was seborrheic dermatitis with a superadded infection. Treatment

with oral flucloxacillin, topical clobetasone ointment, and topical miconazole combined with hydrocortisone ointment were unsuccessful. A lesional skin biopsy from the upper back demonstrated widespread suprabasal acantholysis and corps ronds (**Figure 3**). Superficial neutrophilic inflammation and subjacent dermal inflammation was also noted. Staining for fungi and bacteria was negative.

The clinical history and histological findings were in keeping with an acquired variant of Darier disease. Treatment for the metastatic prostate cancer was intensified with docetaxel chemotherapy and the leuprorelin acetate therapy was switched to enzalutamide (second-line hormonal therapy) after a rise in prostate-specific antigen levels. At 3-month follow-up repeat imaging with computed tomography demonstrated absence of disease progression. Our patient showed a good response to acitretin 30mg once a day, which was successfully reduced to a maintenance dose of 10mg on alternate days and finally stopped after nearly two years.

### Case Discussion

The *ATP2A2* gene is implicated in classic Darier disease and encodes the sarco/endoplasmic reticulum calcium ATPase isoform two (SERCA2), which is responsible for regulating calcium



**Figure 3.** Punch biopsy from the upper back demonstrating widespread suprabasal acantholysis with evidence of corps ronds. Presence of bacteria within serosanguinous crust overlying the epidermis. H&E, **A)** 100 $\times$ , **B)** 200 $\times$ .

**Table 1.** Literature review of acquired Darier disease associated with malignancy.

Demo-graphics	Site of Darier	Histology	Malignancy and treatment	Treatment of malignancy	Treatment of Darier	Outcome	Reference
62, male (our case)	Face (post-auricular, nasolabial and eyebrows), upper back, central chest, lower abdomen and groin. Typical nails changes present	Widespread suprabasal acantholysis and corps ronds	Recent diagnosis metastatic prostate cancer	First line hormonal therapy with Leuprorelin, switched to Enzalutamide, Docetaxel	Acitretin 30mg once a day, reduced to 10mg once daily and then stopped	Darier disease and metastatic prostate cancer both in remission	Our patient
74, male	Ear lobes, back, abdomen, hands, oral mucosa. Typical nail changes present	Epidermal acanthosis, papillomatosis, suprabasilar acantholysis, corp ronds and grains	Concurrent diagnosis, 1) undifferentiated metastatic carcinoma 2) well-differentiated papillary thyroid carcinoma	1) localized radiotherapy 2) not known	Etretinate 25mg once daily, later switched to methotrexate 10mg once weekly, increasing to 20mg once weekly	Poor response to treatment, patient became depressed and committed suicide	Dortzbach et al. [6]
62, male	Head, neck, trunk and back. Typical nail changes present	Suprabasal acantholytic cleft and dyskeratotic cells like corps ronds and grains	Concurrent diagnosis gastric adenocarcinoma	Surgical resection	Not required	Spontaneous resolution of Darier disease after resection of gastric carcinoma	Gangopadhyay et al. [7]

homeostasis in the endoplasmic reticulum. Impaired expression causes abnormal epidermal cell-to-cell adhesion and altered differentiation. Certain tumors may secrete factors such as transforming growth factor  $\beta$  which can interfere with keratinocyte calcium homeostasis either involving or independent of the SERCA2 pump [1].

Curth proposed criteria to establish a causal relationship between internal malignancy and cutaneous disease in the context of paraneoplastic syndromes [2,3]. Two of these important criteria include concurrent diagnosis and parallel disease course, both of which our case fulfils. Our patient was diagnosed with metastatic prostate cancer just a few months prior to his diagnosis of Darier disease. Both conditions progressed in synchrony and once treatment was established both entered remission. The remaining four criteria include: dermatosis specific to the type of neoplasia and rare in the general population, a high frequency of association

between both conditions, and lack of association with a genetic syndrome. Although Darier disease is considered a rare dermatosis, affecting 1-4 per 100,000, the remaining criteria are not satisfied most likely because the phenomenon is only reported in three cases and understanding of disease pathogenesis is limited [4,5]. Curative treatment of the malignant condition in our patient was not possible because it was metastatic at presentation. However, both conditions appear to be in remission at the last follow-up.

Our patient developed an acquired form of Darier disease shortly after a diagnosis of metastatic prostate cancer. A literature search reveals just two other reported cases of acquired Darier disease both associated with malignancy (**Table 1**). One report describes a gastric malignancy presenting with Darier disease in a 62-year-old man. The cutaneous manifestations diminished on treating the underlying malignancy [6]. The second report



describes a 74-year-old man with metastatic undifferentiated carcinoma of unknown primary who subsequently developed a fibroproliferative disorder and concurrent Darier disease [7]. He was treated with localized radiotherapy which appeared to keep his malignant condition in remission. However, despite being initiated on methotrexate and etretinate, the cutaneous changes persisted and unfortunately the patient committed suicide. These cases suggest that an acquired variant of Darier disease, although rare, may exist in association with malignancy. We postulate the mechanism to be of paraneoplastic origin.

## References

1. Sakuntabhai A, Ruiz-Perez V, Carter S, et al. Mutations in *ATP2A2*, encoding a Ca<sup>2+</sup> pump, cause Darier disease. *Nat Genet.* 1999;21:271–277. [PMID: 10080178].
2. Silva JA, Mesquita Kde C, Igreja AC, et al. Paraneoplastic cutaneous manifestations: concepts and updates. *An Bras Dermatol.* 2013;88:9-22 [PMID: 23538999].
3. Curth HO. Dermatoses and malignant internal tumors. *AMA Arch Derm.* 1955;71:95-107. [PMID: 13217478].
4. Cooper SM, Burge SM. Darier's disease: epidemiology, pathophysiology, and management. *Am J Clin Dermatol.* 2003;4:97-105. [PMID: 12553850].
5. Godic A, Miljkovic J, Kansky A, Vidmar G. Epidemiology of Darier's Disease in Slovenia. *Acta Dermatovenerol Alp Pannonica Adriat.* 2005;14:43-48 [PMID: 16001099].
6. Gangopadhyay A, Ghosh A, Biswas S, et al. Darier Disease in Gastric Malignancy: An Unusual Paraneoplastic Phenomenon. *Indian J Dermatol.* 2015;60:423. [PMID: 26288448].
7. Dortzbach KL, Seykora JT, Werth VP. Darier's disease associated with an underlying neoplasm in combination with a nodular fibroproliferative disease. *J Am Acad Dermatol.* 2003;49:S237-9. [PMID-1457663]

## Conclusion

In summary we present a patient with acquired Darier disease and metastatic prostate cancer. We postulate a paraneoplastic mechanism, which may suggest a novel variant of Darier disease or paraneoplastic exacerbation of subclinical disease. Further research is required to elucidate pathogenesis.

## Potential conflicts of interest

The authors declare no conflicts of interests