

Retronychia: the importance of proper footwear

Alexandria M Riopelle¹ MD, Susruthi Rajanala¹ MD, Saara Khan² BS, Sindhu B Kosuru² BA, Bria Bryant³ BS, Chris G Adigun³ MD, Louis Kuchnir² MD PhD

Affiliations: ¹Department of Dermatology, Boston Medical Center, Boston, Massachusetts, USA, ²Kuchnir Dermatology, Massachusetts, USA, ³Dermatology & Laser Center of Chapel Hill, Chapel Hill, North Carolina, USA

Corresponding Author: Alexandria Riopelle MD, 609 Albany Street Boston, MA 02118, Tel: 925-786-0738, Email: LexiRiopelle@gmail.com

Abstract

Retronychia is commonly underdiagnosed and exhibits classic features of proximal nail fold elevation and nail plate layering. Herein we summarize the literature and discuss cause, diagnosis, and treatment of this condition.

Keywords: avulsion, paronychia, prevention, retronychia, treatment

Introduction

Retronychia, first described in 1999 [1], is an inflammatory condition in which the proximal nail plate grows towards the proximal nail fold (PNF) with subsequent nail plate layering and nail fold inflammation (paronychia), [2-4]. The condition, most commonly affecting young adult women, is clinically characterized by chronic paronychia, PNF elevation, yellow discoloration of the nail (xanthonychia), thickened proximal nail plate, and PNF granulation tissue. Retronychia exists on a pathophysiological spectrum with Beau lines and onychomadesis but differs in that the lateral matrix horns remain intact [2,5,6].

Despite several studies recently published in the literature, this condition is underdiagnosed and rarely treated appropriately [2]. Depending on the severity of the disease, treatment options include high potency topical corticosteroids, intralesional corticosteroid injections, orthoses, onycholytic plate clipping, and chemical or surgical avulsion [2,7]. In our experience, patients must also address the

inciting factor to successfully halt the disease process. We report several patients who developed retronychia related to ill-fitting shoes. Resolution was only seen in those who received therapeutic treatment in conjunction with shoe modification.

We present a series of 6 patients who presented to a private practice clinic in Chapel Hill, North Carolina with classic features of retronychia including PNF elevation and nail plate layering (**Figure 1**). The demographic and clinical features of these patients along with disease course is summarized in **Table 1**.

Average age at the time of presentation to dermatology clinic was 28. Most patients were female (N=5). Five patients presented with symptoms limited to the great toe and three patients presented with associated acute paronychia. Duration of symptoms ranged from three months to four years. One patient had a history of major trauma to the affected toe. Two patients had prior surgical avulsion of the affected nail. Nail clippings were obtained in four patients and all were negative for fungal organisms. Moreover, three patients received antifungal treatment for presumed onychomycosis prior to presentation. All patients reported wearing

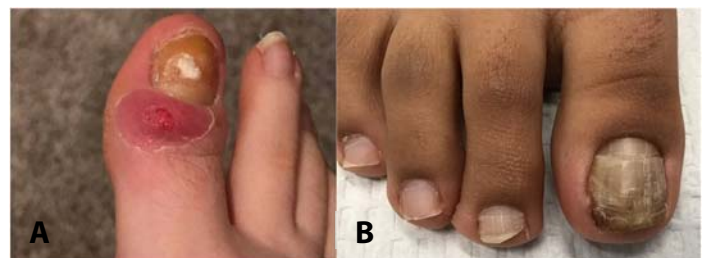


Figure 1. A) Patient 3. Right hallux with severe acute retronychia and paronychia. **B)** Patient 2. Representative example of nail color discoloration and thickening which can mimic onychomycosis.

Table 1. Clinical characteristics of patients and retronychia course.

ID	Age gender	Location	Duration	Shoe type, Brand	History of major trauma	Severity	Paronychia	Disease course
1	48 F	R first toenail	3 m	Sperrys and Toms	No	Mild	No	Avulsion years ago Shoe change, resolution
2	18 F	R first toenail, L second toenail	1 y	Converse	No	Int	No	Avulsion years ago ILK × 1, shoe change, resolution
3	22 F	R first toenail	5 m	Converse	No	Severe	Yes	ILK × 2, mild improvement Avulsion, shoe change, resolution Partial recurrence after wearing Converse brand sneakers again
4	27 M	L first toenail	4 y	Vans, running shoes	Yes	Int	Yes	ILK × 3, resolution Recurrence with running long distances
5	35 F	L first toenail, R first toenail	5 m	Heels	No	Mild	No	Shoe modification, some improvement
6	18 F	L first toenail, R first toenail	4 y	Converse	No	Int	Yes	Avulsion, shoe modification, moderate improvement

F indicates female; ILK, intralesional triamcinolone injection 20mg/mL; Int, intermediate; L, left; M, male; m, months; R, right; y, year.

poorly fitting shoes. Five patients reported wearing tight casual shoes with three of those patients wearing Converse brand sneakers “almost always.” One patient frequently wore high heel shoes, which was required for her occupation as a model. No patients had congenital malalignment.

For treatment, all patients were encouraged to wear closed-toe shoes with a wide toe box to remove pressure on the great toenail or open-toe shoes as much as possible to avoid further microtrauma to the affected toe(s). In patient 1, with history of prior therapeutic nail avulsion, resolution was achieved with shoe modification only. In patient 2, who had also previously been treated with nail avulsion, successful treatment consisted of shoe modification combined with intralesional triamcinolone (ILK) 20mg/ml. Patient 3 underwent ILK 20mg/mL on two occasions followed by nail avulsion and shoe modification for severe retronychia (**Figure 1A**) with resolution, followed by partial recurrence once she started working on her feet again and wearing the

same tight shoes. Likewise, patient 4’s retronychia resolved with a series of ILK 20mg/mL but experienced recurrence once running was re-introduced. Patient 5, a prior model, had mild retronychia. She began wearing shoes with generous toe space and noticed some improvement, avoiding nail avulsion. Finally, patient 6 underwent nail avulsion with a change in shoes and experienced improvement with mild residual dystrophy attributable to her longstanding disease.

The causes of retronychia have been well documented. In order of decreasing frequency, retronychia is related to long-term ill-fitting footwear, athletic activities, a single traumatic event, or systemic illness [3,5,6]. Following microtrauma or blunt trauma, the nail plate and part of the nail matrix detaches from the nail bed but remains held in place via the lateral wings of the nail matrix (due to the curvature of the nail), [3]. As a result, longitudinal nail growth is halted, the nail fails to shed properly, and the newly formed nail grows

vertically into the PNF (**Figure 1B**). The entire nail unit becomes unstable resulting in onycholysis and further microtrauma in a cyclical fashion [4]. Treatment modalities currently focus on decreasing inflammation and abating the secondary microtrauma to the PNF.

Recently Sechi et al. analyzed 231 patients with retronychia from 24 case reports, case series, and retrospective reviews and demonstrated a global cure rate of 41.2% and 71.2% with conservative and non-conservative therapy, respectively [2]. Conservative therapy included topical or intralesional high-potency corticosteroids with adjuvant podiatric treatment such as taping or clipping back the nail plate. Non-conservative therapy included chemical or surgical avulsion. In that report, 9.6% of individuals had long-term sequelae based on their analyses [2]. We have likewise observed that despite conservative or nonconservative therapy, retronychia may persist. All patients in this case series developed retronychia due to ill-fitting shoes, and we found that patients only responded to medical or surgical treatment when they also stopped wearing the shoes that incited the microtrauma. These lifestyle alterations include wearing open-toe shoes or closed-toe shoes that do not crowd the toes. Our case series also demonstrates that intervention without shoe wear modification puts patients at increased risk for recurrence. Therefore, patients should be counseled

that adequate treatment requires shoe wear modification in addition to medical or surgical interventions in moderate to severe cases.

Improper fitting shoes are known to worsen numerous podiatric conditions including bunions, corns, calluses, diabetic ulcers, and gout [8-11]. One study conducted in 356 women found that the majority of women surveyed were wearing shoes that were too small or constrictive for their feet [11]. The most common designs that are detrimental to the human foot include 1) narrow toe box, and 2) heel elevation [12]. Although there is no standard grading system for toe box shape that we are aware of, prior studies have used the terms "very wide," "wide," "narrow," and "very narrow" to describe the degree of constriction on the toes [12]. Patients can find wide toe box shoes by purchasing shoes with a "wide" or "extra-wide" width.

One biomechanical study evaluated the effect of toe box shape and demonstrated that shoes with a narrow toe box placed more pressure on the medial foot and interdigital area compared to those with a wider toe box [13]. Another study found that high heel shoes limit motion of the first metatarsophalangeal joint, suggesting that pressure on the first toenail is also high [14]. As women age, they tend to wear shoes with a broader toe box, seeking comfort rather than style [12], which could explain why young women are at the highest risk of developing retronychia. One recent article also recommends the use of "protective toe tubes," which are thin rubber tubes worn around the toe to minimize friction and trauma when wearing closed toe footwear [15]. We recommend patients avoid constrictive footwear until the retronychia resolves but counsel they are at risk of recurrence if they resume using that footwear. Further studies are needed to elucidate the exact measurements of shoes that may be protective against retronychia.

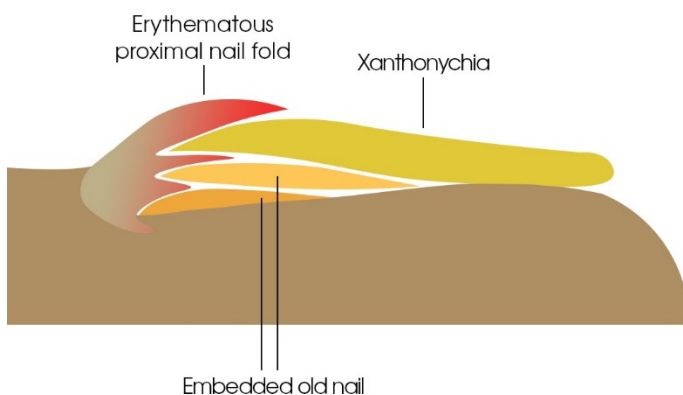


Figure 2. Mechanism of retronychia. Microtrauma or trauma to the nail middle portion of the proximal nail matrix and plate detaches lateral wings of the nail matrix hold the lateral proximal nail matrix in place (complete onychomadesis does not occur) improper nail shedding new nail starts to grow vertically nail fold inflammation and secondary paronychia.

Conclusion

Retronychia is under-recognized and largely nonexistent in the major dermatologic textbooks. This difficult-to-treat condition therefore poses a diagnostic dilemma due its similarities with other

diseases, most notably onychomycosis as demonstrated in **Figure 2**. We suggest this diagnosis be considered in patients with the characteristic nail findings and negative fungal nail clipping results. In addition, clinicians should remain aware of the distinct clinical findings of retronychia: acute retronychia presents with classic morphology and pain from the proximal paronychia (but will not respond to traditional paronychia treatments). On the other hand, chronic retronychia is painless and may present with an absent cuticle, a layered nail

plate, and a reported history of not needing to trim the affected nails frequently [15]. Dermatologists should become more familiar with suggested treatment algorithms [2], recommend shoe wear modification early in the disease course, and work closely with podiatry peers to make this diagnosis swiftly.

Potential conflicts of interest

The authors declare no conflicts of interest.

References

1. de Berker DA, Rendall JR. Retronychia-proximal in growing nail. *J Eur Acad Dermatol Venereol*. 1999;12:S126. [PMID: 18375016].
2. Sechi A, Zengarini C, Piraccini BM, et al. Treatment of retronychia: A systematic review and suggested treatment algorithm. *Dermatol Ther*. 2022;35:e15251. [PMID: 34877747].
3. Mello C, Souza M, Noriega LF, Chiacchio ND. Retronychia. *An Bras Dermatol*. 2018;93:707-11. [PMID: 30156621].
4. de Berker DA, Richert B, Duhard E, et al. Retronychia: proximal ingrowing of the nail plate. *J Am Acad Dermatol*. 2008;58:978-83. [PMID: 18375016].
5. Lee DK, Lipner SR. Optimal diagnosis and management of common nail disorders. *Ann Med*. 2022;54:694-712. [PMID: 35238267].
6. Baumgartner M, Haneke E. Retronychia: diagnosis and treatment. *Dermatol Surg*. 2010;36:1610-4. [PMID: 20722655].
7. Alessandrini A, Sechi A, Merli Y, et al. Intralesional steroid treatment for the intermediate stage of retronychia: A pilot study. *Dermatol Ther*. 2020;33:e14174. [PMID: 32779351].
8. Silfverskiöld JP. Common foot problems. Relieving the pain of bunions, keratoses, corns, and calluses. *Postgrad Med*. 1991;89:183-8. [PMID: 1826149].
9. Brenton-Rule A, Dalbeth N, Edwards NL, Rome K. Experience of finding footwear and factors contributing to footwear choice in people with gout: a mixed methods study using a web-based survey. *J Foot Ankle Res*. 2019;12:3. [PMID: 30636975].
10. Bulat T, Kosinski M. Diabetic foot: strategies to prevent and treat common problems. *Geriatrics*. 1995;50:46-50. [PMID: 7835725].
11. Frey C, Thompson F, Smith J, Sanders M, Horstman, H. American Orthopaedic Foot and Ankle Society women's shoe survey. *Foot Ankle*. 1993;14:78-81. [PMID: 8454237].
12. Menz HB, Roddy E, Marshall M, et al. Epidemiology of Shoe Wearing Patterns Over Time in Older Women: Associations With Foot Pain and Hallux Valgus. *J Gerontol A Biol Sci Med Sci*. 2016;71:1682-7. [PMID: 26834078].
13. Branthwaite H, Chockalingam N, Greenhalgh A. The effect of shoe toe box shape and volume on forefoot interdigital and plantar pressures in healthy females. *J Foot Ankle Res*. 2013;6:28. [PMID: 23886242].
14. Sussman RE, D'Amico JC. The influence of the height of the heel on the first metatarsophalangeal joint. *J Am Podiatry Assoc*. 1984;74:504-8. [PMID: 6491144].
15. Haneke E, Manola I, Smiljan Benko I, Jozić M, Hursa AM. Chronic Retronychia: Nonsurgical Treatment. *Skin Appendage Disord*. 2022;8:291-294. [PMID: 35983471].