

# Papular mucinosis, or localized lichen myxedematosus (LM) (discrete papular type)

Mitalee P Christman MD, Kumar Sukhdeo MD PhD, Randie H Kim MD PhD, Shane Meehan MD, Evan Rieder MD, Kristen Lo Sicco MD, and Andrew Franks MD

Affiliations: New York University Langone Health, New York

## Abstract

Lichen myxedematosus is a condition characterized by localized areas of dermal deposition of mucin, presenting with firm papules localized to few areas of the body. The condition needs to be excluded from scleromyxedema, which, in addition to the firm papular eruption, has areas of induration and is usually associated with a monoclonal gammopathy and systemic symptoms. We present a 62-year-old woman with a several-year history of asymptomatic, firm papules over the face and arms with no evidence of thyroid disease or a monoclonal gammopathy, which is consistent with a diagnosis of localized lichen myxedematosus, the discrete papular variant. The patient is being treated with a topical calcineurin inhibitor.

*Keywords: papular mucinosis*

## Introduction

A 62-year-old woman presented to the Skin and Cancer Unit for the evaluation of persistent, asymptomatic firm, white lesions on her face and arms for many years. The onset was gradual, and there was no recent worsening or improvement. She denied other symptoms and reported no fever, chills, weight loss, chest pain, shortness of breath, trouble swallowing, joint pain, abdominal pain, muscle weakness, limited mobility, or Raynaud's phenomenon.

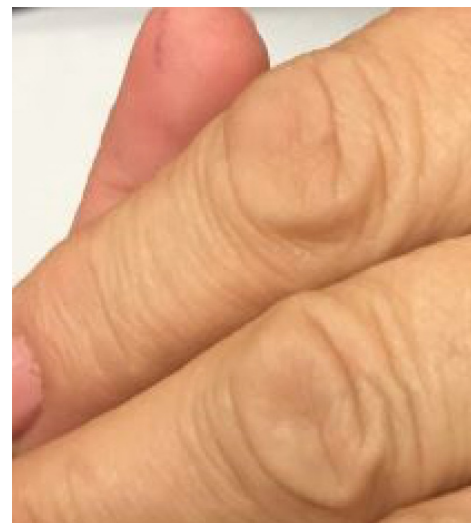
There were several firm, waxy, white-to-flesh-colored, 2-4 mm-sized, closely spaced papules distributed symmetrically over the patient's forehead, upper cutaneous lip, and upper arms. The skin overlying the proximal interphalangeal joints demonstrated a central depression surrounded by a raised rim. There was no thickening or induration of the skin.

A complete blood count and a comprehensive metabolic panel were normal. The thyroid stimulating hormone level and free thyroxine level were within normal limits. Serum protein electrophoresis and urine protein electrophoresis with immunofixation both showed a normal protein pattern without a monoclonal spike. Both serum and 24-hour-urine kappa free light chains and lambda free light chains were within normal limits with a normal kappa/lambda ratio.

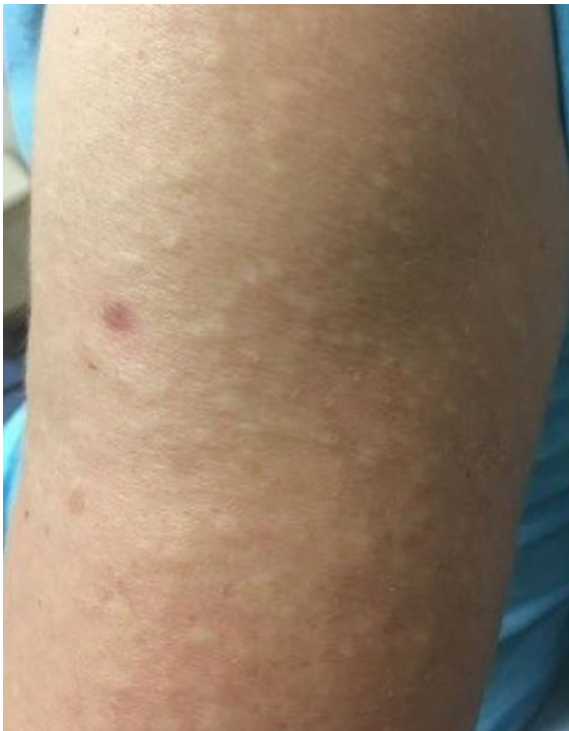Within the reticular dermis, there is an increased amount of connective tissue mucin in association with fibroblasts.

## Conclusion

Papular mucinosis is one of the cutaneous mucinoses, an assorted group of disorders in which mucin, composed primarily of hyaluronic acid, accumulates focally within the dermis [1]. The reason for this abnormal accumulation of mucin is not clear. One theory is that immunoglobulins or cytokines might



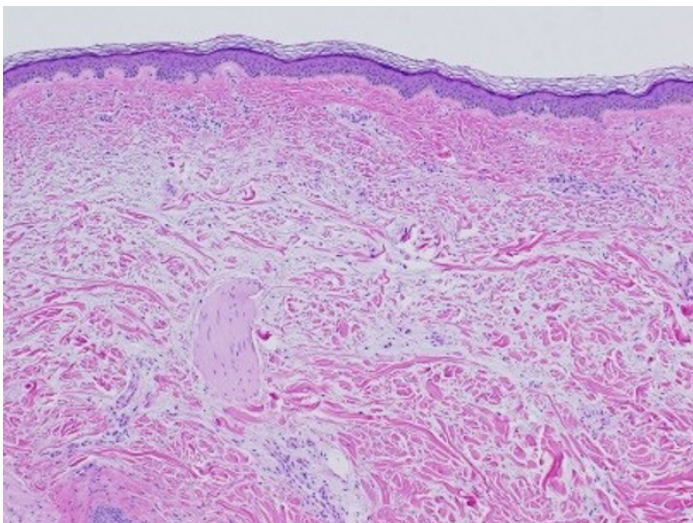
**Figure 1.** Doughnut sign over the proximal interphalangeal joints.



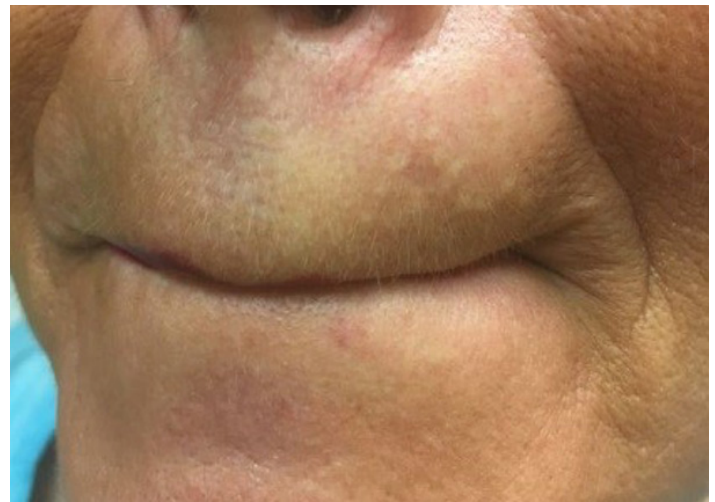**Figure 2.** Firm papules on arm.

increase glycosaminoglycan (GAG) synthesis [2]. This theory is supported by evidence that certain cutaneous mucinoses are associated with increased levels of serum immunoglobulins and circulating autoantibodies. Also, the cytokines IL-1, TNF-alpha and TGF-beta are known to stimulate GAG synthesis, and might contribute to mucin deposition [2].

In localized lichen myxedematosus, the discrete papular lichen myxedematosus variant, the skin is the only organ affected. Firm papules and plaques affecting limited areas of the skin are typically seen,



**Figure 4.** Within the reticular dermis, there is an increased amount of connective tissue mucin in association with fibroblasts.



**Figure 3.** Firm papules on face.

usually sparing the face. The lesions progress slowly without induration or systemic involvement. Rarely, they resolve spontaneously [3].

This condition needs to be distinguished from scleromyxedema. In addition to a widespread distribution of firm papules, patients with scleromyxedema exhibit evidence of a plasma cell dyscrasia in 80-90% of cases. The plasma cell dyscrasia is usually an IgG monoclonal gammopathy consisting of lambda free light chains. Less than 10% of these patients progress to multiple myeloma [2, 4].

Patients with scleromyxedema also have areas of thickening or induration of the skin, creating characteristic signs which may aid in diagnosis. Skin thickening over the forehead might form glabellar furrows creating leonine facies; over the trunk, deep furrows and grooves might create the Shar-Pei sign; and over the proximal interphalangeal joints, induration might create the doughnut sign. Mat telangiectasias, nailfold changes and calcinosis are usually not seen, distinguishing this condition from systemic sclerosis. Scleromyxedema often has systemic manifestations due to mucin deposition in other organs, manifesting as dysphagia and muscle weakness due to myositis, arthralgias of the hands, peripheral neuropathy, lung disease, congestive heart failure, unexplained coma, and scleroderma-like renal disease [4].

Our patient has a symmetric eruption of firm papules on the face and arms, but no areas of induration (apart from the doughnut sign), no systemic symptoms, and

no evidence of a monoclonal gammopathy in the serum or urine. The lack of these features supports a diagnosis of localized lichen myxedematosus (most likely the discrete papular variant) as opposed to scleromyxedema. She reports her condition has been stable for many years, while scleromyxedema typically slowly progresses with skin thickening and sclerodactyly. It is possible her condition might represent an atypical case of scleromyxedema without monoclonal gammopathy, suggesting the need of clinical monitoring for the aforementioned systemic manifestations.

Treatment of cutaneous mucinoses is usually disappointing, and patients and families need to be counseled accordingly. First-line therapy for scleromyxedema usually includes intravenous immunoglobulin (IVIg), and evidence for this is largely based on case reports and case series [5, 6]. Patients refractory to IVIg may be treated with a regimen based on myeloma therapies including combinations of melphalan, systemic steroids, thalidomide, lenalidomide and bortezomib [7-9]. Intralesional and topical corticosteroids are of limited benefit [4]. On the other hand, localized lichen myxedematosus is usually observed without treatment. Topical calcineurin inhibitors and topical steroids may show partial improvement [3, 10].

Treatment in this patient was initiated with topical tacrolimus 0.1% ointment applied daily to affected areas. She will continue to be monitored in our clinic every three months.

## References

1. Rongioletti F, Rebora A. The new cutaneous mucinoses: a review with an up-to-date classification of cutaneous mucinoses. *J Am Acad Dermatol.* 1991;24:265. [PMID: 2007673].
2. Rongioletti F, Rebora A. Updated classification of papular mucinosis, lichen myxedematosus, and scleromyxedema. *J Am Acad Dermatol.* 2001;44:273. [PMID: 11174386].
3. Rongioletti F, Zaccaria E, Cozzani E, Parodi A. Treatment of localized lichen myxedematosus of discrete type with tacrolimus ointment. *J Am Acad Dermatol.* 2008;58:530. [PMID: 18280368].
4. Rongioletti F, Merlo G, Cinotti E, et al. Scleromyxedema: a multicenter study of characteristics, comorbidities, course and therapy in 30 patients. *J Am Acad Dermatol.* 2013;69:66. [PMID: 23453242].
5. Blum M, Wigley FM, Hummers LK. Scleromyxedema: a case series highlighting long-term outcomes of treatment with intravenous immunoglobulin (IVIg). *Medicine (Baltimore).* 2008;87:10. [PMID: 18204366].
6. Sroa N, Campbell S, Bechtel M. Intravenous immunoglobulin therapy for scleromyxedema: a case report and review of the literature. *J Drugs Dermatol.* 2010;9:263. [PMID: 20232589].
7. Sansbury J, Cocuroccia B, Jorizzo JL, et al. Treatment of recalcitrant scleromyxedema with thalidomide in 3 patients. *J Am Acad Dermatol.* 2004;51:126. [PMID: 15243538].
8. Donato M, Feasel AM, Weber DM, et al. Scleromyxedema: role of high-dose melphalan with autologous stem cell transplantation. *Blood.* 2006;107:463. [PMID: 16179379].
9. Bos R, de Waal EG, Kuiper H, Hazenberg BP, Vellenga E. Thalidomide and dexamethasone followed by autologous stem cell transplantation for scleromyxedema. *Rheumatol.* 2011;50:1925. [PMID: 21719421].
10. Jun J, Oh SH1, Shim JH1, Kim JH1, Park JH1, Lee DY. Acral persistent papular mucinosis with partial response to tacrolimus ointment. *Ann Dermatol.* 2016;28:517. [PMID: 27489445].