

# A novel case of NKX3.1-positive metastatic cutaneous prostate cancer

Jennifer K Wong<sup>1</sup> DO, John P Minni<sup>2</sup> DO, Michael A Nowak<sup>3</sup> MD

Affiliations: <sup>1</sup>Larkin Community Hospital, Miami, Florida, USA, <sup>2</sup>Water's Edge Dermatology, Stuart, Florida, USA, <sup>3</sup>Palm Beach Dermatology, West Palm Beach, Florida, USA

Corresponding Author: Jennifer Wong, 4901 NW 75<sup>th</sup> Avenue, Lauderhill, FL 33319, Tel: 954-803-4863, Email: [j.wong8390@gmail.com](mailto:j.wong8390@gmail.com)

## Abstract

Prostate carcinoma is the most common non-dermatological malignancy in men and only second to lung cancer as the leading cause of cancer related deaths in America. Moreover, metastasis to the skin is even more uncommon following apparently successful treatment of a preexisting prostate cancer. We present an 87-year-old man previously diagnosed with prostate cancer treated with brachytherapy, who presented with a metastatic prostate adenocarcinoma of the scalp mimicking a basal cell carcinoma. Herein, we present a patient with an NKX 3.1 positive cutaneous metastatic prostate carcinoma identified through NKX3.1 stain rather than the typical PSA/PSAP stain.

*Keywords: cutaneous metastasis, prostate, adenocarcinoma, NKX3.1 stain*

## Introduction

Prostate cancer is the most common non-cutaneous cancer in men with adenocarcinomas making up 95% of all prostate cancers [13]. Cases are usually discovered through screening asymptomatic men. However, symptoms associated with prostate cancer include urinary retention or frequency, back pain, and hematuria. Abnormal screening findings include an elevated prostate-specific antigen (PSA) level and/or abnormal digital rectal exam. A needle biopsy of the prostate is required for definitive diagnosis. Moreover, immunohistochemical (IHC) markers are often employed as adjunctive diagnostic aids,

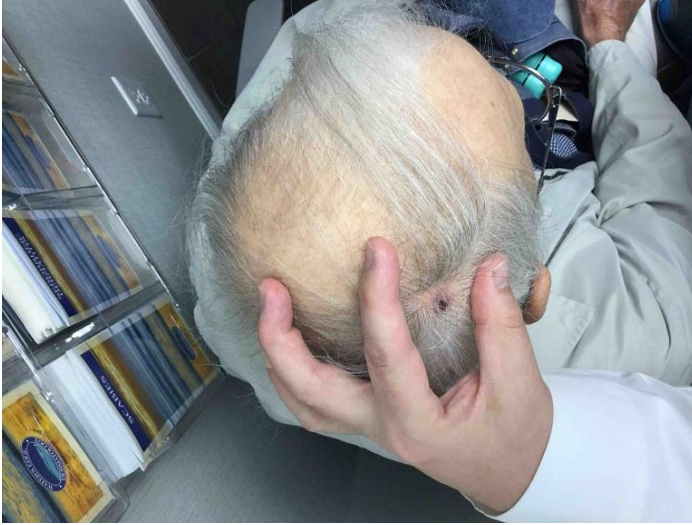especially in the setting of limited cancer foci in a needle biopsy [2].

Depending on the PSA value, pathologic stage, and histologic grade of the tumor, approximately 30% of patients with clinically localized prostate cancer are estimated to progress and metastasize despite treatment [3]. Although prostate cancer is very common, the incidence of prostate carcinoma metastasizing to the skin is less than 1% [9].

## Case Synopsis

An 87-year old man with a past medical history of prostate cancer diagnosed in October 2002 and treated previously with brachytherapy presented to his dermatologist with a new asymptomatic, rapidly growing skin lesion. There was no history of a previously treated skin cancer in this area. The patient had no current urinary symptoms. Skin examination revealed a non-tender pearly nodule with a bluish hue clinically resembling a basal cell carcinoma located on the right parietal scalp (**Figure 1**).

Histologic examination revealed a multinodular dermal tumor composed of epithelioid cells with abundant amphophilic cytoplasm and ovoid nuclei with prominent nucleoli. There were foci of necrosis, duct-like structures, and abundant mitoses (**Figure 2**). There was a Grenz zone of uninvolved upper dermis and epidermal continuity was not identified. The histologic differential diagnosis included a poorly differentiated cutaneous adnexal

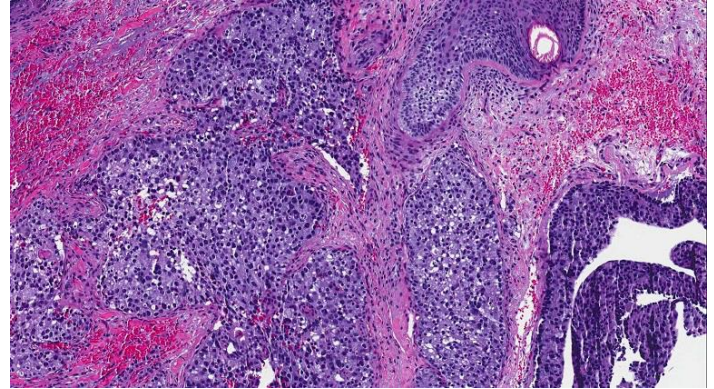


**Figure 1.** Initial presentation of metastatic cutaneous lesion. Pearly bluish-red nodule with surrounding erythema located on the right parietal scalp.

adenocarcinoma and metastatic adenocarcinoma. Preliminary immunohistochemical stain revealed Ber-EP4 positivity, CAM5.2 positivity, CK5/6 negativity, and podoplanin negativity. Additional immunohistochemical stains were performed to distinguish a primary cutaneous carcinoma from a metastatic carcinoma. The tumor was strongly positive for NKX-3.1, cytokeratin 20, and ERG (**Figure 3**). Stains for EMA, cytokeratin 7, TTF-1, P63, and CDX-2 were all negative. PSA and PSAP were not performed. Nevertheless, the positive NKX-3.1 and ERG confirmed metastatic prostate adenocarcinoma, whereas the negative P63 stain helped distinguish metastatic carcinoma from a cutaneous adnexal tumor.

The patient was sent to a plastic surgeon for conservative excision and to his oncologist. Serum PSA level was 17. A bone scan revealed a solitary metastasis to a right rib. Consequently, the patient was put on leuprolide and bicalutamide. One month later, his PSA was 12 and his oncologist noticed regrowth of the scalp lesion. Biopsy revealed recurrent adenocarcinoma with identical microscopic findings. The patient was sent for radiation therapy and received 3000Gy over 10 treatments with complete clinical resolution.

Despite all of these treatments, his PSA level began increasing steadily from 12 to 42 over the next several weeks and a bone scan revealed additional

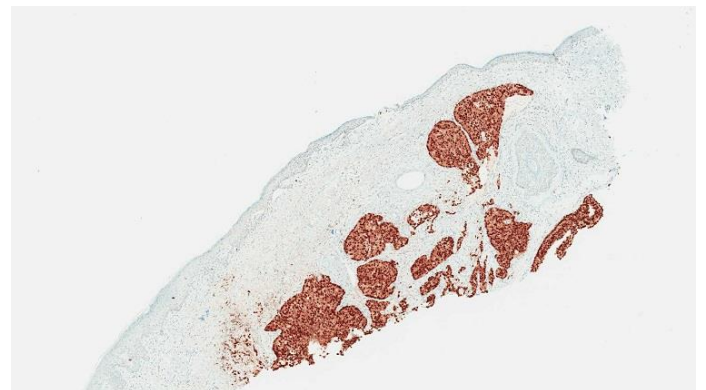


**Figure 2.** H&E stain from the shave biopsy depicts a multinodular tumor consisting of epithelioid cells and amphophilic cytoplasm, 10x. Ductal structures, foci of necrosis, and mitosis are seen throughout the lesion.

metastases in the left trochanter and left rib. His oncologist then added enzalutamide, which resulted in lowering his PSA levels to 12. He continues leuprolide acetate every 3 months and denosumab every 4 weeks. The patient so far is responding well.

### Case Discussion

Carcinoma of the prostate typically metastasizes to the bone, lymph nodes, lungs, and liver [12]. Metastasis to the skin is considered to be exceptional, accounting for less than 1% of all cutaneous metastasis [5]. Parth et al. has hypothesized that such cutaneous manifestations may be a result of direct extension of the malignancy, seeding during surgical resection, or hematogenous or lymphatic spread [8]. No unified theory on the pathogenesis of distant cutaneous metastasis has been established.



**Figure 3.** NKX3.1 immunohistochemical stain highlights tumor cell nuclei including nucleoli, 4x.

According to Wang et al. [13] and Mueller et al. [5], cutaneous metastasis from genitourinary malignancies are associated with a poor prognosis despite prostate cancer having a 98.6% five-year survival rate [3]. Average survival period is about seven months to a year after discovery of this cutaneous finding [13]. Consequently, discovering a cutaneous lesion of metastatic prostatic origin will allow dermatologists and oncologists to formulate a more robust treatment regimen. In the few reported cases of cutaneous metastasis of prostate cancer to the skin, the lesions present as multiple infiltrated nodules most frequently found in the inguinal area [10]. Exceptional metastatic cutaneous lesions were found on the abdomen, head and neck, chest, extremities, and back in decreasing order of frequency [13].

Histopathological examinations of cutaneous metastases resemble the primary tumor of origin. Gland-like structures may be present if the primary tumor is an adenocarcinoma [1]. Lack of epidermal continuity and an associated Grenz zone are characteristic of most cutaneous metastasis. However, primary cutaneous adnexal carcinomas typically share these findings. Immunohistochemical studies, especially P63 positivity, favor a primary adnexal carcinoma over metastatic adenocarcinoma to the skin [4]. CK20 and CDX2 help differentiate metastatic cutaneous lesions from gastrointestinal and prostatic origin [11]. PSA and PSAP are traditional immunohistochemical markers for prostate carcinoma. However, some poorly differentiated prostatic adenocarcinomas weakly express these stains [2]. Therefore, a negative PSA does not exclude prostate carcinoma and NKX3.1

staining becomes paramount in identifying prostatic differentiation in a cutaneous metastasis.

NKX3.1 is an androgen-regulated homeodomain transcription factor located on chromosome 8p21.2 that plays a role in early prostate development and functions as a prostate-specific tumor suppressor [6]. A recent study discovered that NKX3.1 staining was highly sensitive and specific for high-grade prostatic adenocarcinoma [2]. It has been reported that the NKX3.1 stain has a specificity of 99.7% and sensitivity of 98.6% compared to PSA with a sensitivity of 94.2% [2]. Gurel et al. documented NKX3.1 positivity as a marker of metastatic prostate adenocarcinoma; however, there was no mention of cutaneous metastasis.

## Conclusion

Prostate carcinoma metastasizing to the skin is rare. Recognition is paramount because it may be the first initial sign of visceral malignancy or recurrence. Cutaneous lesions may mimic other dermatologic conditions [7]. Therefore, a proper immunohistochemical workup is essential. NKX3.1 should be considered as an integral addition to the workup of a cutaneous nodule for patients with a history of prostate cancer. This stain is relatively new and may not be used widely at this point by all laboratory institutions. With more patients experiencing long term cancer survival, the possibility exists for cutaneous metastasis presenting to dermatologists. Therefore, a high index of suspicion and awareness of new stains such as NKX 3.1 is a valuable adjunct to the practicing dermatologist.

## References

1. Brown G, Kurtzman D, Lian F, Sligh J. Eruptive nodules of the head and neck: a case report of metastatic prostate cancer. *Dermatol Online J*. 2014;20(2). [PMID: 24612577].
2. Gurel B, Ali TZ, Montgomery EA, et al. NKX3.1 as a marker of prostatic origin in metastatic tumors. *Am J Surg Pathol*. 2010;34(8):1097-105. [PMID: 20588175].
3. Key Statistics for Prostate Cancer: American Cancer Society; 2018 [updated January 4, 2018; cited 2018]. Available from: [www.cancer.org/cancer/prostate-cancer/about/key-statistics.html](http://www.cancer.org/cancer/prostate-cancer/about/key-statistics.html). Accessed May 8, 2018.
4. Mahalingam M, Nguyen LP, Richards JE, Muzikansky A, Hoang MP. The diagnostic utility of immunohistochemistry in distinguishing primary skin adnexal carcinomas from metastatic adenocarcinoma to skin: an immunohistochemical reappraisal using cytokeratin 15, nestin, p63, D2-40, and calretinin. *Mod Pathol*. 2010;23(5):713-9. [PMID: 20190734].
5. Mueller TJ, Wu H, Greenberg RE, et al. Cutaneous metastases from genitourinary malignancies. *Urology*. 2004;63(6):1021-6. [PMID: 15183939].

6. Padmanabhan A, Rao V, De Marzo AM, Bieberich CJ. Regulating NKX3.1 stability and function: Post-translational modifications and structural determinants. *Prostate*. 2016;76(6):523-33. [PMID: 26841725].
7. Pal D, Talwar V, Doval DC, Jalpota YP, Kumar N. Cutaneous metastasis in prostatic carcinoma. *Indian J Dermatol Venereol Leprol*. 2009;75(3):311-2. [PMID: 19439894].
8. Patel P, Patel J, Siddiqui S. Recurrence of prostate cancer with cutaneous metastasis after radical prostatectomy. *Case Rep Urol*. 2015;2015:825175. [PMID: 25861515].
9. Patne SC, Naik B, Patnaik P, Trivedi S. Cutaneous metastases of prostatic adenocarcinoma. *J Cytol*. 2015;32(2):121-3. [PMID: 26229250].
10. Reddy S, Bang RH, Contreras ME. Telangiectatic cutaneous metastasis from carcinoma of the prostate. *Br J Dermatol*. 2007;156(3):598-600. [PMID: 17300266].
11. Telis L, Wolf V, Yaskiv O, et al. Skin metastasis, an uncommon course of prostate carcinoma: a report of two cases. *Malays J Pathol*. 2016;38(2):165-8. [PMID: 27568675].
12. Tengue K, Kpatcha, T, Sewa E, et al. Prostate cancer revealed by skin metastasis: A case report in black African man. *Afr J Urol*. 2016(324):4. [doi: 10.1016/j.afju.2016.10.003].
13. Wang SQ, Mecca PS, Myskowski PL, Slovin SF. Scrotal and penile papules and plaques as the initial manifestation of a cutaneous metastasis of adenocarcinoma of the prostate: case report and review of the literature. *J Cutan Pathol*. 2008;35(7):681-4. [PMID: 18201228].