

**Case presentation**

**A case of acanthosis nigricans coexisting with mycosis fungoides**

**Esther Cheng DO<sup>1</sup>, David B Roy DO<sup>2</sup>, Cynthia M Magro MD<sup>1</sup>**

**Dermatology Online Journal 21 (7): 11**

**<sup>1</sup>Department of Pathology and Laboratory Medicine, New York Presbyterian Hospital – Weill Cornell Medical Center, New York, NY, USA**

**<sup>2</sup>South Central Dermatology, Laurel, MS, USA**

**Correspondence:**

Cynthia Magro, M.D.  
Professor of Pathology & Laboratory Medicine  
Division of Dermatopathology  
Director of Dermatopathology  
Weill Cornell Medical College of Cornell University  
1300 York Ave, Room F309-B  
New York, NY 10065  
212-746-6434

---

**Abstract**

Acanthosis nigricans maligna (ANM) is a paraneoplastic phenomenon most commonly associated with visceral adenocarcinoma, in particular, gastric adenocarcinoma. Clinically, ANM is characterized by rapidly progressive symmetrical skin thickening and hyperpigmentation of the intertriginous areas with peripheral acrochorda. The diagnosis is made by a detailed medical work-up for occult malignancies with particular emphasis on endocrinological diseases. We report a 67-year-old man that presented clinically with acanthosis nigricans, in which a subsequent diagnosis of mycosis fungoides was made.

**Keywords: Acanthosis nigricans, Acanthosis nigricans maligna, Paraneoplastic acanthosis nigricans, Mycosis fungoides**

**Introduction**

Acanthosis nigricans (AN) is an inflammatory condition that is classically associated with endocrine and metabolic dysregulation. The clinical presentation is characterized by symmetrical hyperpigmented thickened skin with a velvety surface along intertriginous folds [1]. The benign form of AN is most commonly caused by diseases of insulin resistance such as diabetes mellitus and polycystic ovarian syndrome. Infrequently, the development of malignant AN is secondary to the effects of a neoplasm and is termed acanthosis nigricans maligna (ANM) or paraneoplastic acanthosis nigricans (PAN).

Acanthosis nigricans maligna is postulated to be secondary to the effects of secreted transforming growth factor- $\alpha$ , epidermal growth factor- $\alpha$ , insulin-like growth factor and fibroblast growth factor by the tumor cells on keratinocytes [2]. Transforming growth factor- $\alpha$  acts as a soluble or transmembrane-bound ligand that on binding an epidermal growth factor receptor, allows keratinocytes to differentiate and proliferate and thus, cause epidermal thickening [3].

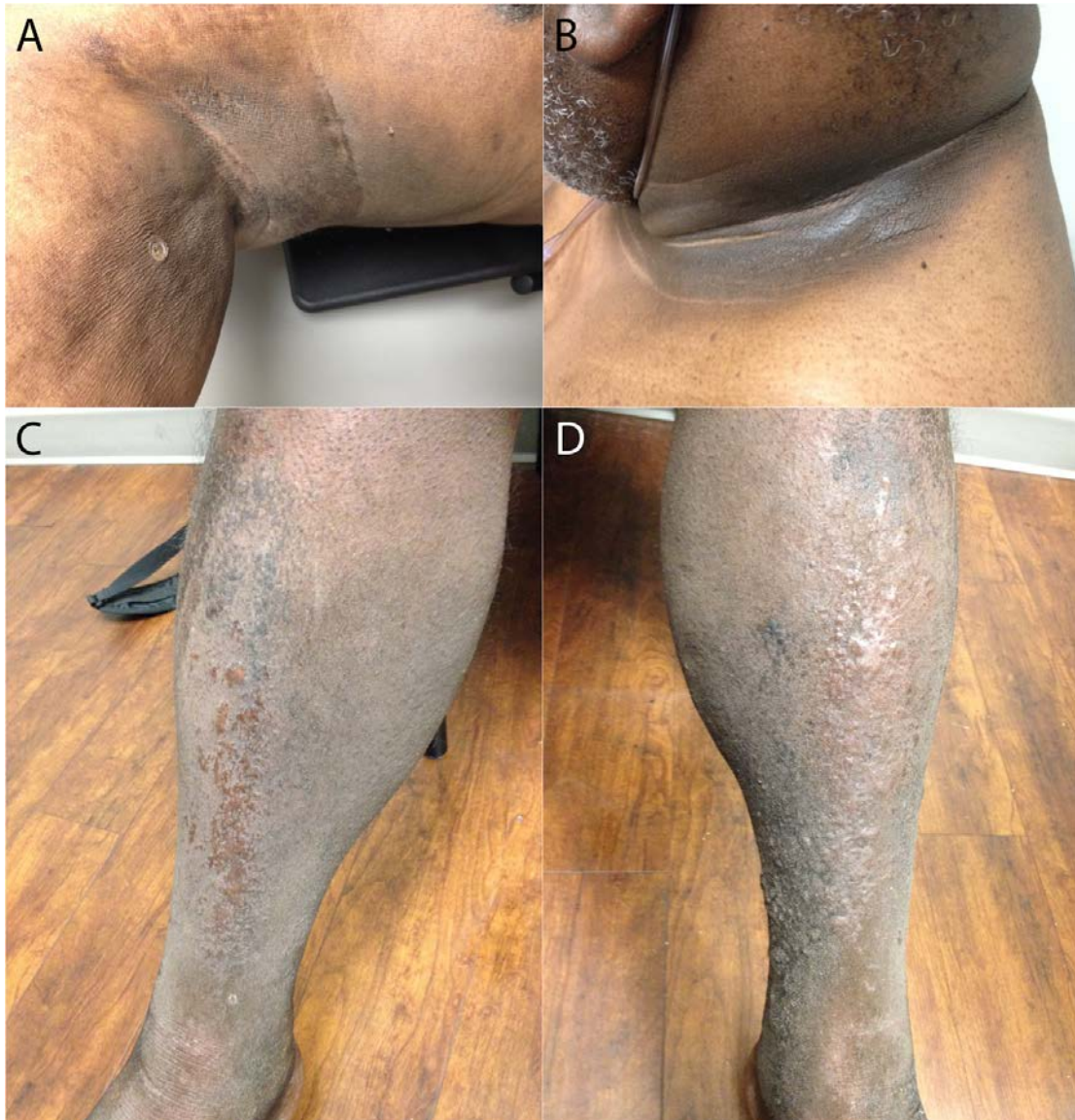Unlike the more common benign form of AN, the evolution of ANM is described as a rapidly progressive symmetrical skin thickening with hyperpigmentation of the intertriginous areas with peripheral acrochorda. Mucocutaneous involvement and generalized pruritus are features of ANM [2]. The development of other paraneoplastic cutaneous manifestations such as tripe palms and the sign of Leser-Trélat may also be evident [4].

ANM is most strongly correlated with visceral adenocarcinoma, with gastric adenocarcinoma being the most common [2]. Pertinent to this diagnosis is the paralleling course the neoplasm shares in conjunction with ANM. For example, if the neoplasm is treated with successful remission, ANM should also predictably remit.

ANM arises in equal incidence in men and women, globally affecting all patients of different ethnicities without a familial predisposition. ANM classically affects patients without metabolic dysfunction around the ages of 40 to 50. A literature search yields numerous cases linking visceral adenocarcinomas with ANM. The incidence of ANM and hematological diseases are uncommon. Of the hematological malignancies, mycosis fungoides comprises only a small subset with an incidence of 36 per 100,000 persons-year, from 1973 to 1992 [5]. Only five case reports describe a true association of mycosis fungoides with ANM.

## Case synopsis

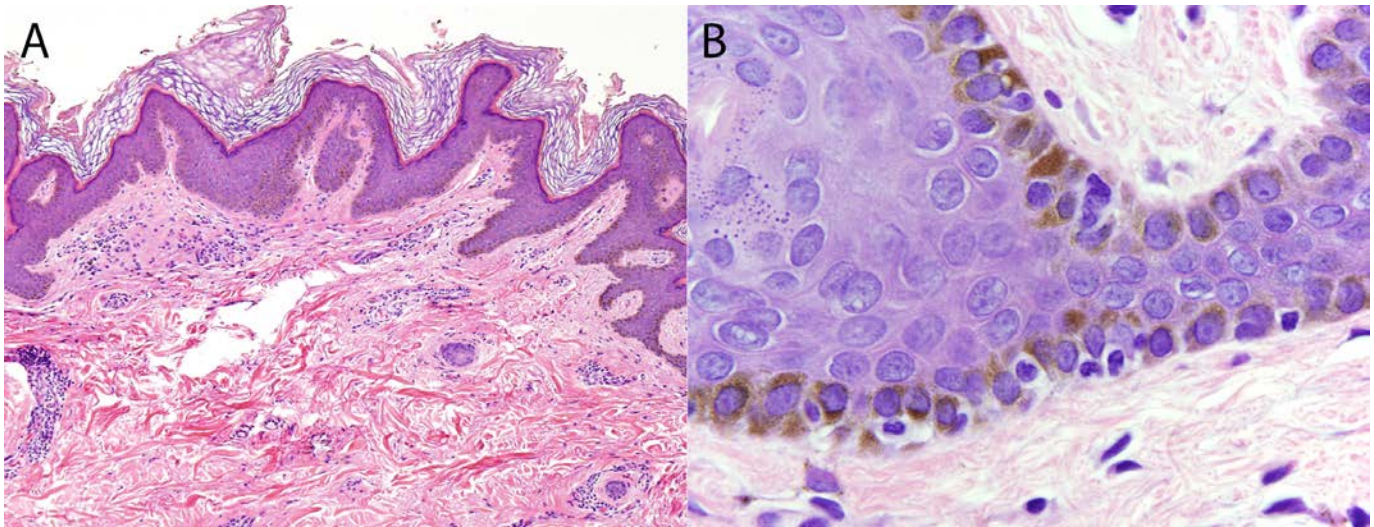
A 67-year-old man with uncontrolled type 2 diabetes mellitus presented with a one and half year history of extensive pruritic hyperpigmented velvety eruptions involving the bilateral lower legs, axilla, and neck. Early evolving lesions were seen on the chest, back, abdomen, and upper thighs (Figure 1 A, B, C, D). The patient complained of global pruritus that was recalcitrant to topical corticosteroids and oral antihistamines. Hepatosplenomegaly and lymphadenopathy were not evident.



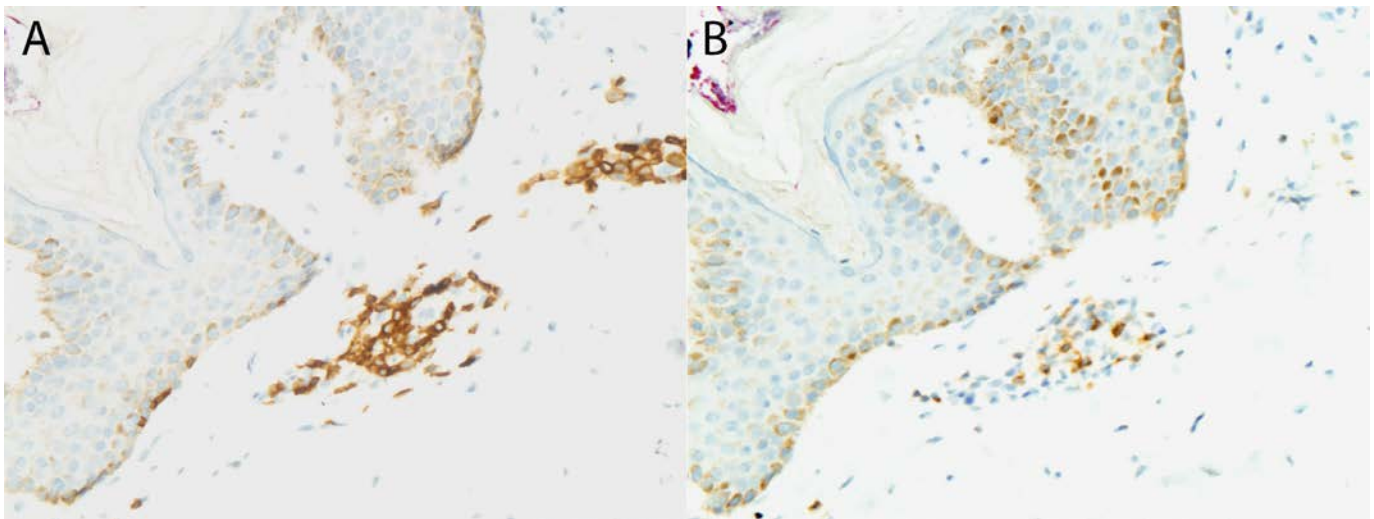
**Figure 1 A-D.** Clinical photographs showing bilateral axilla and lower leg hyperpigmented plaques. There are rare peripheral acrochorda around the axilla.



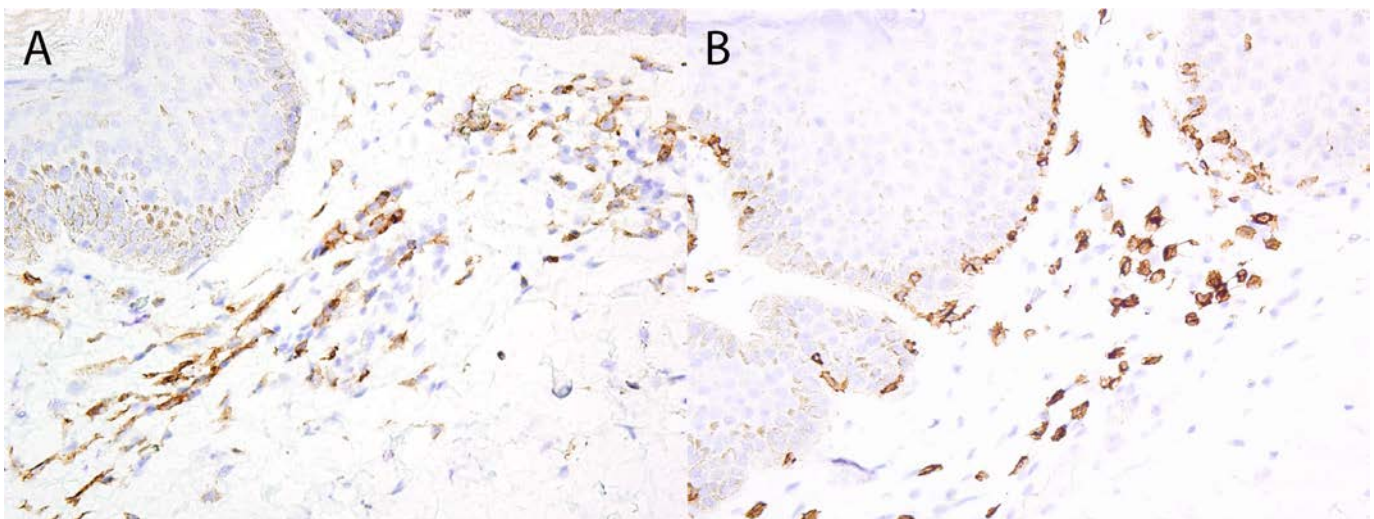
A shave biopsy of the patient's right upper arm revealed a papillomatous verrucoid epidermis with an atypical epitheliotropic lymphocytic infiltrate. The lymphocytes were small to intermediate in size with irregular nuclear contours (Figure 2A, 2B). The dermal papillae appeared vacuous, likely secondary to papillary dermal elastolysis.



**Figure 2 A, B.** A biopsy of the patient's lesion shows a verrucoid hyperkeratosis with basal layer hyperpigmentation with epitheliotropic infiltration of lymphocytes with irregular nuclear contours. A) hematoxylin & eosin, 100x magnification and B) hematoxylin & eosin, 1000x magnification.



**Figure 3A.** The lymphocytes are predominantly CD3 positive by immunohistochemical staining, 200x magnification. **Figure 3B.** Few lymphocytes are CD7 positive by immunohistochemical staining, 200x magnification.



**Figure 4A.** The lymphocytes are positive for CD4 by immunohistochemistry, 200x magnification. **Figure 4B.** The lymphocytes are positive for CD8 by immunohistochemistry, 200x magnification.

Several immunohistochemical stains were performed. Elastolysis was confirmed with an elastic stain. The atypical epitheliotropic lymphocytes were highlighted for BetaF1, CD2, CD3 (Figure 3A), CD4 (Figure 4A) and CD5. There was marked diminution in the expression of CD 7 (Figure 3B). The cerebriform lymphocytes that colonize the epidermis are of the CD8 subset (Figure 4B).

The patient was referred for a hematology-oncology consultation. The systemic work-up revealed no additional findings. The patient was recommended to undergo PUVA therapy, but was subsequently lost to follow-up.

## Discussion

Of the five previous case reports describing a true association of ANM and mycosis fungoides, the age ranged from 36 to 58 years old and was seen predominantly in males (four of five cases) [6-10]. Only a single case explicitly identified a non-diabetic patient. The ethnicities of the patients are as follows: one Caucasian, one Hispanic, one of African descent, and two of unknown background. Three cases had biopsies that had coinciding AN and mycosis fungoides. One case had both coinciding and isolated specimens, and one case had completely isolated specimens. Therapy included PUVA, topical nitrogen mustard, radiation, mechlorethamine, and brentuximab vedotin. Two cases showed significant improvement of AN with therapy, one case with a suboptimal response, and another case with no response. A single case did not state the patient's therapy or outcome. Biopsies of AN with an absence of malignant T-cell infiltration, that also exhibit a predictable resolution from treatment of mycosis fungoides, are thought to be authentic examples of ANM. Those biopsies with features of AN and coexisting atypical epitheliotropic lymphocytes in a single sample are better described as AN-like mycosis fungoides [10].

We present a case that illustrates the importance of obtaining a detailed medical work-up to rule out any occult malignancies in patients with AN. Our patient is known to be an uncontrolled type 2 diabetic with newly diagnosed mycosis fungoides. Although it would have been easy to dismiss this patient's AN as secondary to insulin resistance, failure to thoroughly investigate the cause could have resulted in a delay in the diagnosis of his malignancy. The inciting event causing ANM in our patient can be postulated to be secondary to cytokine release, the secondary colonization of atypical lymphocytes of AN, or the two entities incidentally coinciding with each other. The diagnosis of malignant AN requires long term screening for the development of additional neoplasms because it can precede the diagnosis of adenocarcinoma by several years [6].

## References

1. Piske MM. An approach to acanthosis nigricans. *Indian Dermatol Online J.* 2014 Jul;5(3):239-49. PMID: 25165638.
2. Silva JA, Mesquita KC, Igreja AC, Lucas IC, Freitas AF, Oliveira SM, Costa IM, Campbell IT. Paraneoplastic cutaneous manifestations: concepts and updates. *An Bras Dermatol.* 2013 Jan-Feb;88(1):9-22. PMID: 23538999.
3. Talsania N et al. Paraneoplastic Acanthosis Nigricans: The importance of exhaustive and repeated malignancy screening. *Dermatol Online J.* 2010 Aug 15;16(8):8. PMID: 20804685.
4. Amjad M et al. Malignant acanthosis nigricans: an early diagnostic clue. *J Coll Physicians Surg Pak.* 2010 Feb;20(2):127-9. PMID: 20378042.
5. Weinstock MA and Gardstein B. Twenty-year trends in the reported incidence of mycosis fungoides and associated mortality. *Am J Public Health.* 1999 Aug; 89(8):1240 – 1244. PMID: 10432915.
6. Neill SM, Monk BE, du Vivier A. Mycosis fungoides associated with acanthosis nigricans. *J R Soc Med.* 1985 Jan;78(1):79-81. PMID: 3968677.
7. Schweitzer WJ, Goldin HM, Bronson DM, Brody PE. Acanthosis nigricans associated with mycosis fungoides. *J Am Acad Dermatol.* 1988 Nov;19(5 Pt 2):951-3. PMID: 3192779.
8. Puig L, Musulen E, Fernandez-Figueras MT, Miralles J, Sitjas D, De Moragas JM. Mycosis fungoides associated with unusual epidermal hyperplasia. *Clin Exp Dermatol.* 1996 Jan;21(1):61-4. PMID: 8689775.
9. Willemze R, Scheffer E, Van Vloten WA. Mycosis fungoides simulating acanthosis nigricans. *Am J Dermatopathol.* 1985 Aug;7(4):367-71. PMID: 3842790.
10. Charli-Joseph Y, Chong K, Ai WZ, Leboit PE, Pincus LB. Paraneoplastic acanthosis nigricans paralleling disease course in a patient with mycosis fungoides. *Eur J Dermatol.* 2013 Nov-Dec;23(6):907-8. PMID: 24334263.