

**Case Presentation**

**Pyodermatitis vegetans of the vulva**

**Sandrina Carvalho, Madalena Sanches, Rosário Alves, Manuela Selores**

**Dermatology Online Journal 22 (6): 7**

**Department of Dermatology, Centro Hospitalar do Porto, Oporto, Portugal**

**Correspondence:**

Sandrina Carvalho  
Serviço de dermatologia  
Centro Hospitalar do Porto –  
Hospital Santo António, Porto, Portugal  
Tel. +351 22 207 7500  
Email: carvalhosandrine@gmail.com

---

**Abstract**

Pyodermatitis vegetans (PV) is a rare inflammatory dermatosis of unknown etiology and difficult diagnosis characterized by vesiculopustular, exudative, and vegetating plaques usually localized in the axillary, genital, and oral region. It bears similarities to pemphigus vegetans but clinical history, histology, and immunofluorescence help confirm the diagnosis. Pyodermatitis vegetans is often associated with an underlying gastrointestinal disorder, especially ulcerative colitis. No standardized treatment plan is available for PV. Its evolution tends to follow the progression of the underlying disorder. We report a patient with vulvar PV with good response to systemic antibiotics and corticosteroids.

**Keywords: corticosteroids, inflammatory bowel diseases, pyoderma, vulvar diseases**

**Introduction**

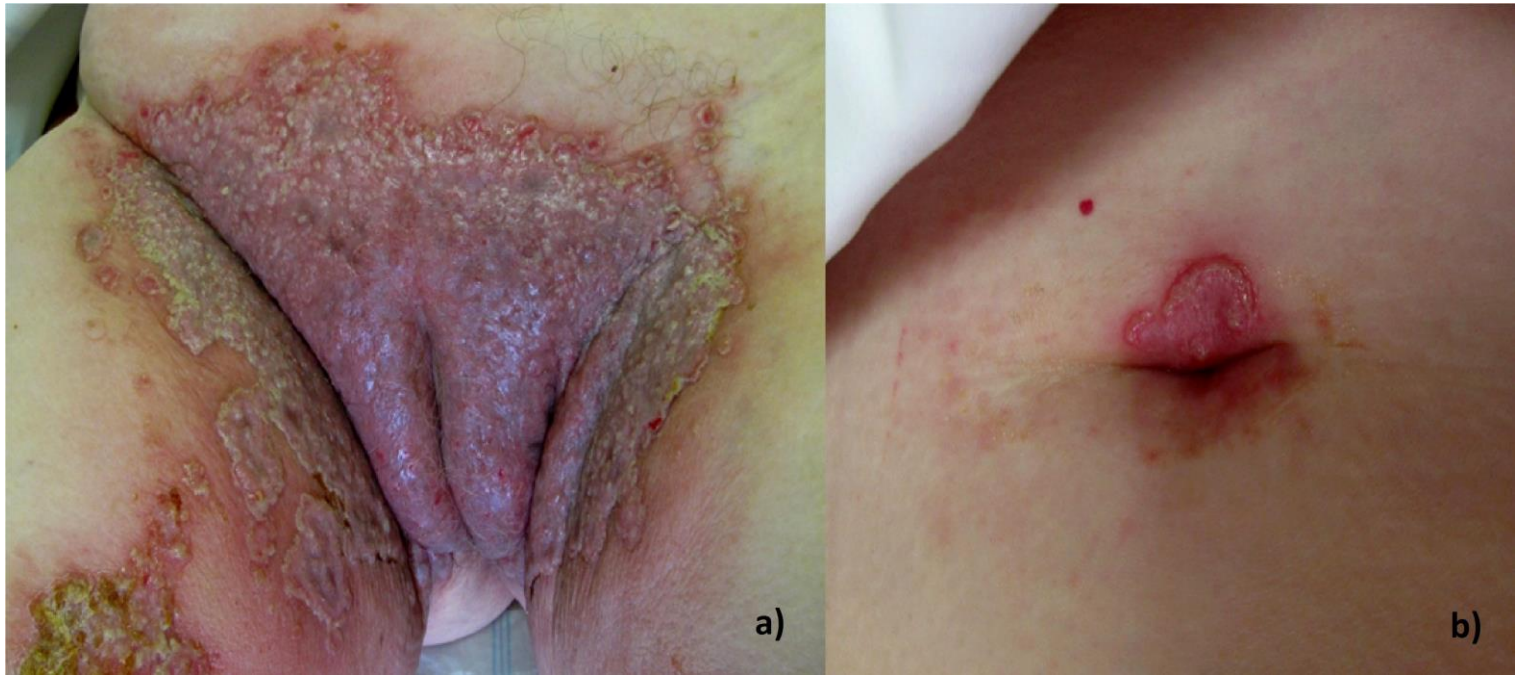Pyodermatitis vegetans (PV) is a rare inflammatory dermatosis of unknown etiology that may represent a variant of pyoderma gangrenosum. Most cases of PV are diagnosed in individuals of 20 to 60 years of age and men are affected more commonly than women [1]. It is often associated with an underlying gastrointestinal disorder such as ulcerative colitis in 53%, or less commonly, Crohn disease in 11% [1]. Other diseases that might be linked to PV include HIV infection, zinc deficiency, chronic myeloid leukemia, and liver dysfunction [3-4]. Predisposing factors can include bacterial infections in patients with compromised immune systems [3]. However, PV has also been reported in healthy patients [4].

Cutaneous involvement (pyodermatitis) with large vesiculopustular, exudative, vegetating plaques can affect the genital and the axillary region as well as the scalp. Less frequently it involves the face, chest, and extremities. The oral mucosa is also frequently affected (pyostomatitis), presenting as multiple tiny, creamy-yellow pustules set against a diffuse, intensely erythematous background. The pustules are easily ruptured, leading to shallow erosions and ulcerations. Vaginal, nasal, and ocular mucosae can also be affected [5].

We describe a patient with vulvar PV with a good response to systemic antibiotics and corticosteroids.

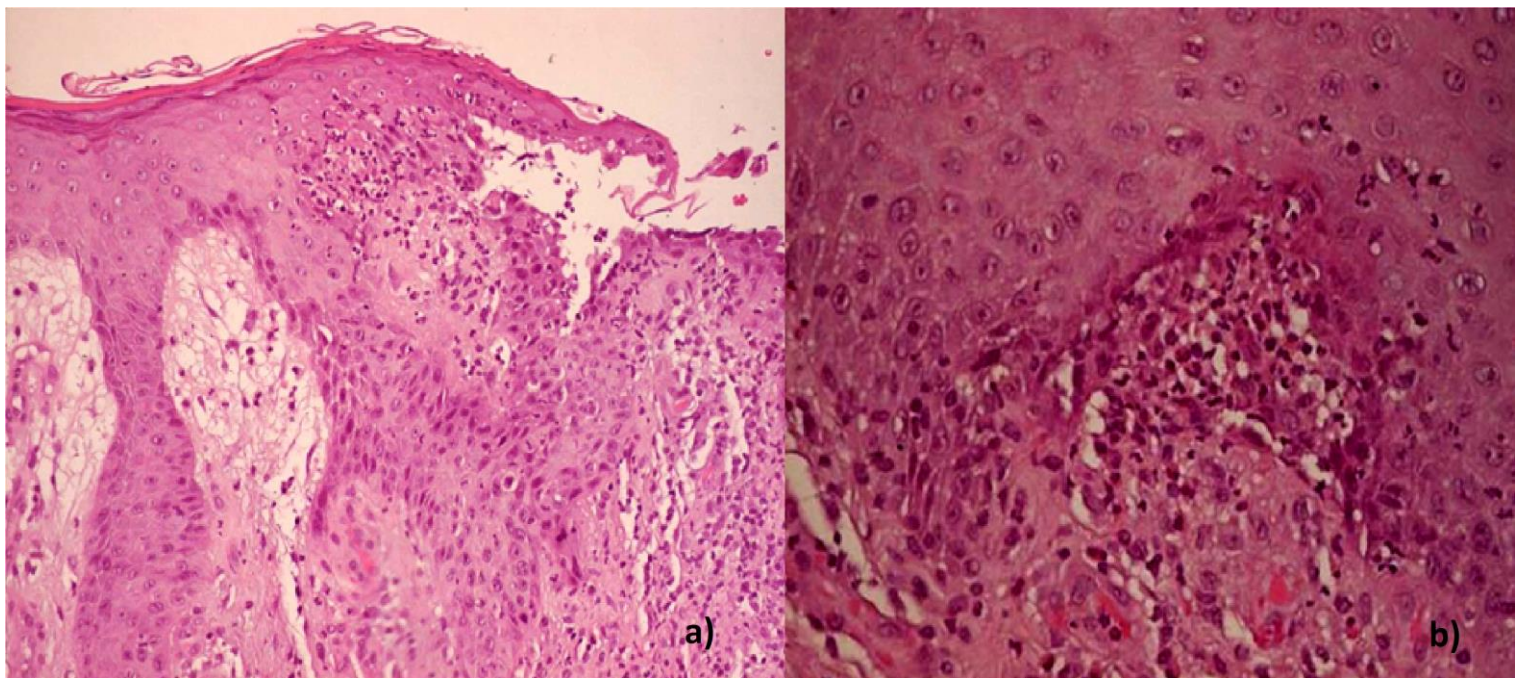
**Case synopsis**

A 79-year-old woman, previously healthy, was observed for a painful eruption of the vulva with 3 months of evolution. She completed multiple antibiotic courses without improvement. On physical examination, she presented with well defined vegetating pustular exudative plaques on the vulva with extension to the inner thighs and the periumbilical region (Figure 1). She had no lesions on oral or vaginal mucosae.



**Figure 1.** Vegetating pustular exudative plaques on the vulva with extension to the internal face of the thighs (a) and the periumbilical region (b).

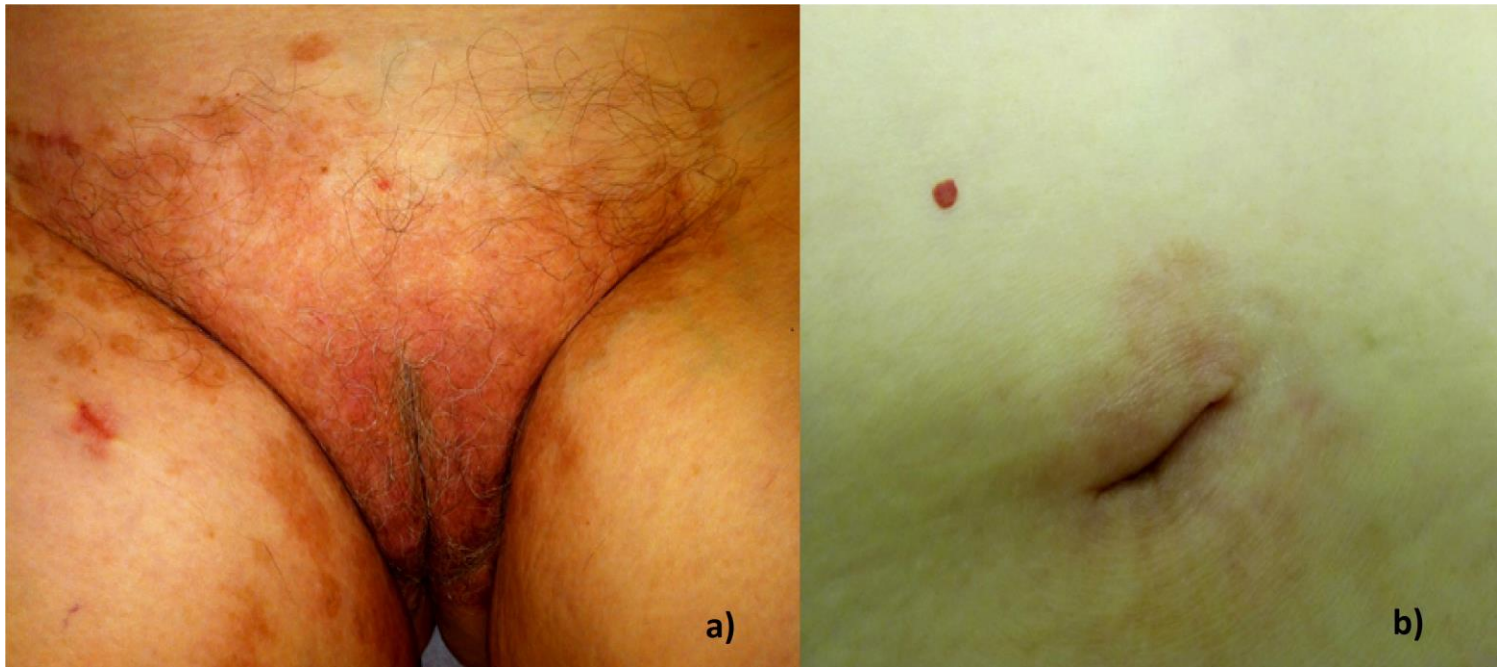Laboratory tests showed a peripheral eosinophilia (820/ $\mu$ L) and an increased rate of erythrocyte sedimentation (36s). Liver function was normal. Serology for syphilis and HIV were negative. Histopathological examination revealed a pseudoepitheliomatous hyperplasia with dense inflammatory infiltrate composed of neutrophils and eosinophils forming microabscesses in the upper dermis (Figure 2).



**Figure 2.** Pseudoepitheliomatous hyperplasia with a dense inflammatory infiltrate composed of neutrophils in the upper dermis - hematoxylin-eosin staining, x10 (a). Neutrophils aggregate forming microabscesses in the dermis - hematoxylin-eosin staining, x40 (b).

Direct and indirect immunofluorescence tests were negative. Wound culture was positive for *Staphylococcus aureus* and *Corynebacterium species*. Mycobacterial and fungal culture were negative. Colonoscopy was normal without signs of inflammatory bowel disease.

Based on these findings, the diagnosis of PV was made. The patient was treated with oral amoxicillin/ clavulanic acid 875/125mg twice daily during two weeks and oral prednisolone 40mg/day (0.5mg/kg/day), which was gradually withdrawn over 1 month. The skin lesions cleared to residual hyperchromic macules within the first week of treatment (Figure 3) and there was no recurrence of the disease after 12 months of follow-up.



**Figure 3.** Residual hyperchromic macules after one week of treatment on the vulva (a) and the periumbilical region (b).

## DISCUSSION

In 1979, Su *et al.* proposed several criteria for the diagnosis of PV: a) large vegetating plaques with multiple pustules and elevated border; b) pseudoepitheliomatous hyperplasia with intra and/or subepithelial neutrophilic or eosinophilic microabscesses on histological examination; c) growth of a least one pathogenic bacteria; d) negative culture for deep fungi, atypical mycobacteria or mycobacterium tuberculosis; e) and normal bromide levels [6].

The hematological and biochemical assessments are within the normal limits in most cases, except for peripheral eosinophilia and increased rate of erythrocyte sedimentation that can be found in 90% of the cases, having diagnostic value [1]. Approximately 26% of the patients with PV present with some kind of liver dysfunction such as sclerosing cholangitis, chronic hepatitis, and pericholangitis [1].

The differential diagnosis of PV comprises pemphigus vegetans, deep fungal infections, *tuberculosis cutis verrucosa*, halogenoderma, squamous cell carcinoma and Sweet syndrome [2]. Since pemphigus vegetans may show clinical and histopathological findings similar to PV, the two are difficult to distinguish from each other. Unlike PV, pemphigus reveals deposits of IgG and C3 by direct immunofluorescence and positivity of circulating antibodies by indirect immunofluorescence [7]. On PV, the immunofluorescence is mostly negative. However, PV may show weakly positive direct immunofluorescence, representing a response to epithelial damage [8].

Investigation of PV should include: hematological and biochemical assessments with liver function, tissue biopsy, direct and indirect immunofluorescence, bacterial, fungal, and mycobacterial culture, and complete gastrointestinal evaluation [2].

No standardized treatment plan is available for PV. The response to systemic steroids, at the dose of 0.5 - 1mg/kg/day, is usually good and rapid [9]. Despite the bacterial etiology of the lesions, systemic antibiotics alone are not an effective treatment [1, 6]. Many other treatment modalities, including dapsone, azathioprine, cyclosporine, and topical tacrolimus, have been reported in case reports and are generally accepted as second line therapies [4, 9-10].

In cases of PV with inflammatory bowel disease (IBD), the treatment of PV should focus on the control of the underlying disorder. There is report of the effectiveness of infliximab with methotrexate to control PV in Crohn disease [11]. Total remission has already been observed after total colectomy for treatment of subjacent IBD [10].

Skin lesions of PV may precede gastrointestinal symptoms of IBD in approximately 15% of the cases indicating the need of regular and careful gastrointestinal monitoring of these patients [12].

## REFERENCES

1. Nigen S, Poulin Y, Rochette L, Lévesque MH, Gagné E. Pyodermitis-pyostomatitis vegetans: two cases and review of the literature. *J cUtn Med Surg* 2003; 7: 250-5. [PMID: 12574902]
2. Canpolat F, Cemil BC, Yilmazer D, Yesilli O, Eskioglu F. Pyoderma vegetans associated with ulcerative colitis: a case with good response to steroids. *Case Rep Dermatol* 2011; 3: 80-4. [PMID: 21503165]
3. Bianchi L, Carrozzo AM, Orlandi A, Campione E, Hagman JH, Chimenti S. Pyoderma vegetans and ulcerative colitis. *Br J Dermatol* 2001;144: 1224-7. [PMID: 11422046]
4. Adisen E, Tezel F, Gurer MA. Pyoderma vegetans : a case for discussion. *Acta Derm Venereol* 2009 ; 89 : 186-188. [PMID: 19326010]
5. Matias FA, Carvalho MT, Rosa DJ, Castanon MC. Pyodermitis-pyostomatitis vegetans: case report and review of medical literature. *An Bras Dermatol* 2011; 86: S137-40. [PMID: 22068794]
6. Su WPD, Duncan S, Perry HO. Blastomycosis-like pyoderma. *Arch Dermatol* 1979; 115:170-3. [PMID: 426522]
7. Cunha PR, Barraviera SRCS. Dermatoses bolhosas auto-imunes. *An Bras Dermatol* 2009; 84: 111-24. [PMID: 19503978]
8. Mesquita KC, Costa IMC. Case for diagnosis. *An Bras Dermatol* 2012; 87:929-31. [PMID: 23197220]
9. Leibovitch I, Ooi C, Huilgol SC, Reid C, James CL, Selva D. Pyodermitis-pyostomatitis vegetans of the eyelids: case report and review of the literature. *Ophtalmology* 2005; 1809-13. [PMID: 16095701]
10. Yasuda M, Amano H, Nagai Y, Tamura A, Ishikawa O, Yamaguchi S. Pyodermitis-pyostomatitis vegetans associated with ulcerative colitis: successful treatment with total colectomy and topical tacrolimus. *Dermatology* 2008; 217: 146-8. [PMID: 18523389]
11. Bens G, Laharie D, Beylot-Barry M, Vergier B, Noblesse I, Beylot C, et al. Sucessful treatment with infliximab and methotrexate of pyostomatitis vegetans associated with Crohn's disease. *Br J Dermatol* 2003; 149: 181-4. [PMID: 12890215]
12. Storwick GS, Prihoda MB, Fulton RJ, Wood WS. Pyodermitis-pyostomatitis vegetans: a specific marker for inflammatory bowel disease. *J Am Dermatol* 1994; 31: 336-41. [PMID: 8034800]