

Case Presentation

Generalized acanthosis nigricans without systemic disease associated

Rafael Denadai¹, Luís Ricardo Martinhão Souto², Mariam Patrícia Auada-Souto³

Dermatology Online Journal 19 (9): 5

¹M.D., Fellow of Surgery, Division of Plastic and Reconstructive Surgery, Department of Surgery, School of Medical Sciences, Universidade de Marília (UNIMAR), Marília, São Paulo, Brazil and Fellow of Research, Institute of Plastic and Craniofacial Surgery, Brazilian Society of Research and Assistance to Craniofacial Rehabilitation Hospital (SOBRAPAR), Campinas, São Paulo, Brazil

²M.D., Ph.D., Associate Professor, Division of Plastic and Reconstructive Surgery, Department of Surgery, School of Medical Sciences, Universidade de Marília (UNIMAR), Marília, São Paulo, Brazil

³M.D., Ph.D., Associate Professor, Division of Dermatology, Department of Internal Medicine, School of Medical Sciences, Universidade de Marília (UNIMAR), Marília, São Paulo, Brazil

Correspondence:

Rafael Denadai, MD
Division of Plastic and Reconstructive Surgery, Department of Surgery, School of Medical Sciences,
University of Marília (UNIMAR)
Paula Fabiana Tudela, 161 – Esmeralda 17516-707, Marília, São Paulo, Brazil
Phone / Fax +55 14 3453-5456
E-mail: denadai.rafael@hotmail.com

Abstract

Acanthosis nigricans (OMIM ID % 100600) is a dermatosis characterized by velvety hyperpigmentation, skin thickening, and papillomatosis. It mainly affects flexural areas. In most cases, the generalized form is related to malignancy in adults; it is rarely reported in the absence of systemic disease in children and adolescents. The present report is aimed at describing an unusual case of generalized acanthosis nigricans in a 17 year-old patient, in which, after extensive investigation (clinical, laboratorial and by imaging methods) no association with systemic disease was found.

Keywords: Acanthosis nigricans.

Introduction

Acanthosis nigricans (AN; ID OMIM % 100600) is a dermatosis characterized by epidermal thickening, verrucous plaques, velvety hyperpigmentation, and papillomatosis [1-4], especially in flexural areas such as armpits, groin, and neck [4-6]. There seems to be no sex predilection [5] and although it can appear in all age groups, it is predominant in adults [6].

AN is mainly associated with endocrine disorders (obesity, diabetes mellitus, and polycystic ovary syndrome), drugs, and malignancy [1-3,7]. In rare cases, it can be unrelated to any systemic disease [2,3,7-10]. There are few reported cases of generalized AN unassociated with systemic diseases in children and adolescents [2,3,7-10]. The present report is aimed at describing an unusual case of generalized AN in a 17 year-old patient. After extensive investigation (clinical, laboratorial, and imaging) found no association with systemic disease was found.

Case synopsis

A 17 year-old female patient, skin type V Fitzpatrick [11], was referred for investigation of progressive darkening and thickening of the skin for nine years. The patient and her family reported that the skin lesions first appeared in the armpits.

Over the years, they gradually affected the cervical, scapular (bilateral), lumbar regions, as well as antecubital fossae and abdominal wall. She presented with itching and flaking sporadically and denied any prior therapeutic approach.

The patient denied an increase or loss of weight recently. She also denied polyuria, polydipsia, polyphagia, or motor/skeletal neurological deficits. The main complaint was the cosmetic appearance. According to information gathered, the patient was born at term, after an eventful pregnancy and she was the first child of three siblings. At birth, she exhibited no skin lesions. The weight/height and neuropsychomotor developments were normal. There was no history of previous use of drugs. The parents had no consanguinity and were healthy. No history suggestive of skin disorders was found in the family.

On physical examination, she appeared well. Her blood pressure was 120 over 80 mmHg. Body weight (50 kg), height (1.62 m) and body mass index (19.00 kg/m^2) were normal for the patient's sex and age. The hair and genital development were within normal limits. The rest of the examination was unremarkable.

Upon dermatological examination, velvety skin with hyperpigmentation and thickening were observed, especially involving the perilabial areas, armpits, abdominal wall, antecubital fossae, neck, scapulae, and lumbar regions (Figure 1). No changes were detected in hair, nails, teeth, mucous membranes, palms, and soles. Clinically, the diagnosis was AN in the generalized form.

Tests for assessment of biochemical, hormonal, and hematological parameters showed no abnormalities. Blood count, T3, T4, TSH, insulin, prolactin, cortisol, total/free testosterone levels, IGF-1, growth hormone, hemoglobin A1C, sedimentation rate, calcium, phosphorus, cholesterol, triglycerides, LDL, HDL, liver and kidney profiles, and oral glucose tolerance were all within normal limits. The measurement of tumor markers was negative. The computerized tomography scans of the skull, chest X-ray, and abdominal ultrasound detected nothing abnormal. Histopathology showed hyperkeratosis, acanthosis, and papillomatosis (Figure 2).

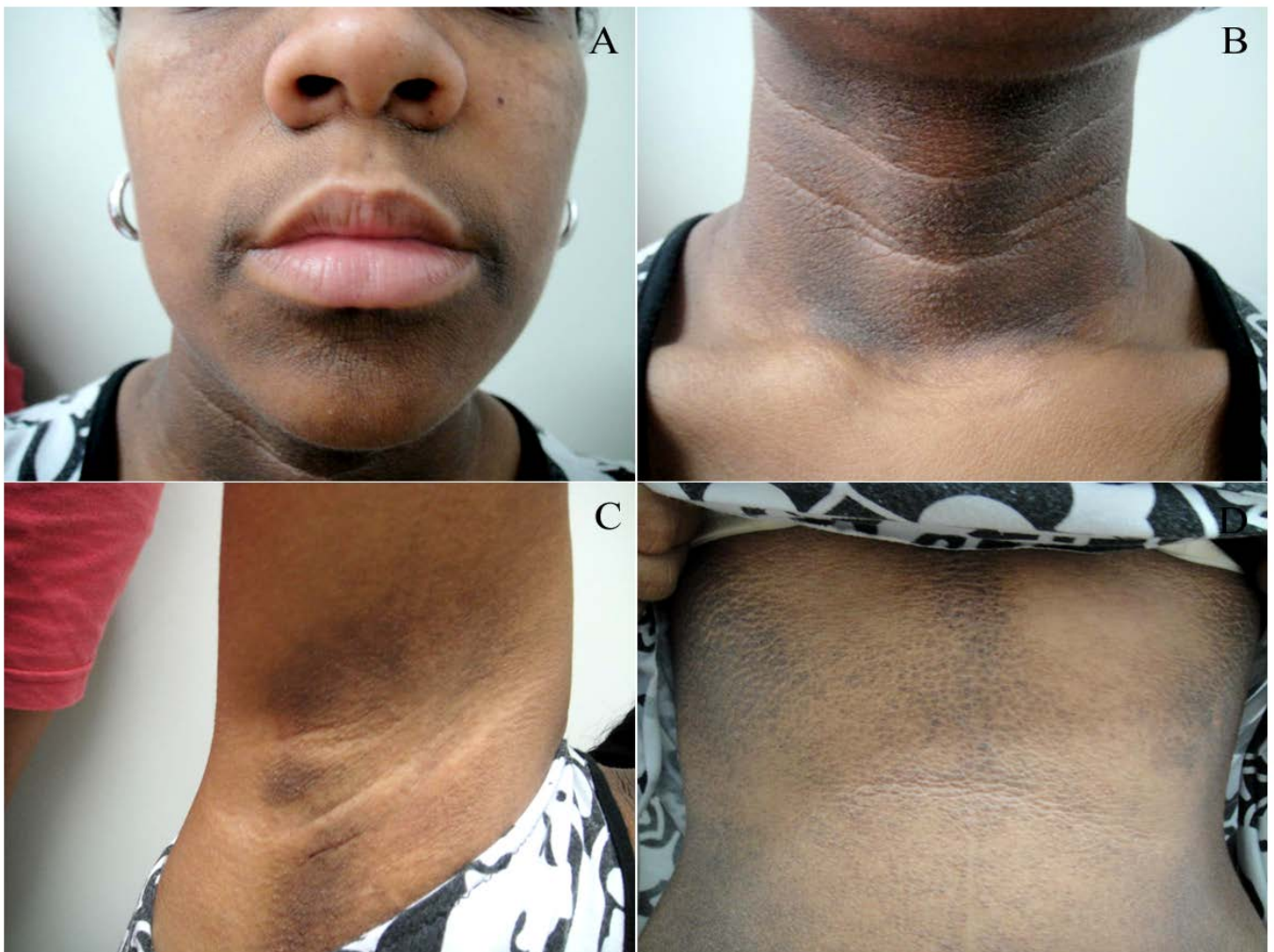

Figure 1. A. Symmetrical velvety hyperpigmentation of perilabial skin. B. Verrucous velvety hyperpigmentation in the anterior cervical region. C. Papillomatosis and hyperpigmentation in the right axillary region. D. Thickening and hyperpigmentation of the lumbar region skin.

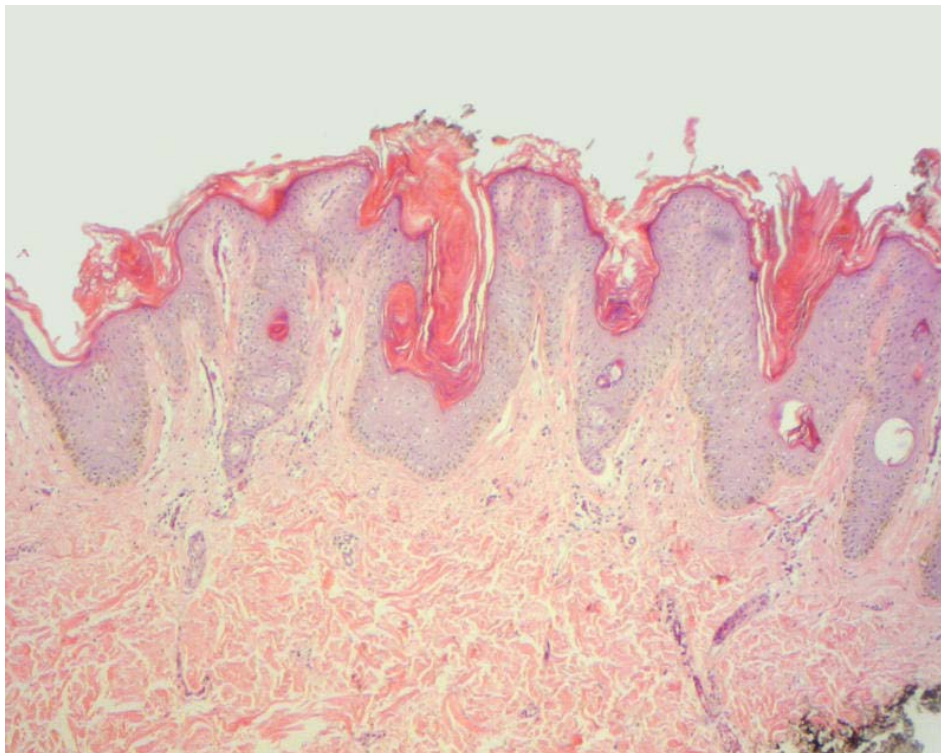


Figure 2. Photomicrograph of skin biopsy of the abdomen reveals orthokeratotic hyperkeratosis, irregular acanthosis, papillomatosis in the epidermis consistent with acanthosis nigricans (Hematoxylin-eosin, original magnification 40 X).

The patient was treated with a combination of 0.05 percent tretinoin cream and 12 percent ammonium lactate cream with partial improvement of the condition. She has been in follow-up for two years, showing no signs of endocrine or malignant diseases.

Discussion

Acanthosis nigricans can be classified into benign AN, AN related to obesity, AN related to genetic syndromes, malignant AN, unilateral AN, acral AN, AN induced by drugs (e.g., nicotinic acid, diethylstilbestrol, corticosteroid, and palifermin), and mixed AN (when two or more types are present) [2-5,8,12].

The diagnosis of AN is based on the clinical appearance of the affected area [3,5,6,8]. It is characterized by hyperpigmentation, ranging in color from brown to black, and epidermal papillomatosis [2,3,7,8], which gives the skin a velvety texture [2,5,7]. The clinical appearance of hyperpigmentation is usually the result of hyperkeratosis of the epidermis [5]. Microscopic changes include papillomatosis and mild acanthosis [1,5], such as described here. In most cases, the skin lesions affect armpits and neck. However, inguinal and infra-mammary areas, face, abdomen, and flexor surfaces of upper and lower limbs may also be affected [1,5,6].

In most cases AN is associated with systemic disorders (obesity, insulin resistance, and malignancy) [1,2,5,7]. Therefore, in cases similar to those described here, it is necessary to perform extensive clinical, radiological, and laboratorial investigations to exclude such conditions and to separate benign and malignant forms [3,10]. If the clinical history does not show the use of a drug that may be causing the problem and there are no signs suggestive of malignancy, appropriate testing must be carried out. In patients with rheumatological disease, the evaluation of auto-antibodies of the insulin receptor may also be included [5].

Generally, benign AN can be present at birth or develops during childhood/adolescence [5]. Initially, it can be unilateral, sparing the palms and soles [5]. These features, plus the absence of obesity, malignancy, and drug use fit the described patient into this type of AN.

The generalized form is not a specific type of AN and it can be viewed as a variant or a rare form of certain types of AN [3,8]. Cases of generalized AN have been rarely reported in adults with internal malignancy [13]. Based on clinical presentation, pathological examination, and the absence of underlying systemic diseases, benign generalized AN was diagnosed in our patient.

In the benign form of AN involvement is rarely generalized [5,9]. To the best of our knowledge, the case presented here is one of the very few reports on generalized AN unassociated with systemic disease in children/adolescents. According to a comprehensive English literature review (Medline and Embase databases) there are sporadic similar reports [1-4,7-10,14,15].

The differential diagnoses of AN include superficial fungal infections, tinea corporis, atopic dermatitis, giant melanocytic nevus, Becker nevus, Addison's disease, and hemochromatosis. Ichthyosis hystrix may also resemble AN, but it is associated with palmoplantar keratoderma and it shows improvement in the summer. The confluent and reticulated papillomatosis of Gougerot and Carteaud is clinically distinct from AN, but it is histologically similar [5].

The pathogenesis of AN is still unknown [3,7,8]. A proposed mechanism is insulin resistance with reactive hyperinsulinemia [2,3,8]. The excess insulin binds to receptors of keratinocytes leading to increased proliferation and growth of epidermal cells [3,8]. This insulin resistance may relate to genetic anomalies of the insulin receptor or of its function, obesity, or autoimmune diseases associated with antibodies to the insulin receptor [3,8]. Malignant AN can result from the secretion of tumoral products with insulin-like activity or from transforming growth factor (TGF- α), which can interact with the receptor of epidermal growth factor [3,8].

Treatment of AN should be directed to the underlying cause [1,3,5,8,13] and may involve weight loss, correction of endocrine abnormalities, withdrawal of the causing drug, or treatment of internal malignancy [8]. In AN patients without associated systemic disease, there are reports of treatment with emollients and keratolytics (topical and/or systemic retinoids), with variable success [3,8].

In the case reported here, the patient was treated with 0.05% topical tretinoin acid for 12 months, showing partial improvement of skin lesions. The use of retinoic acid (topical or oral) has shown variable success in other studies [4,7,9].

A recent study showed an effective treatment with a combination of 12% ammonium lactate cream and 0.05% tretinoin cream in cases of AN associated with obesity [16]. The improvement was probably owing to the reduction of the stratum corneum by the keratolytic action of lactate ammonium and the normalization of the epidermis by retinoic acid [1].

A child with generalized AN was treated with acitretin, initially with 0.6 mg/kg for 7 days and with 1 mg/kg for 14 more days, in association with emollient and keratolytic creams, but the final result was unsatisfactory [10]. In another study [7], a patient with generalized AN was treated with oral acitretin (0.8 mg/kg/day) and in 45 days using the medication the lesions disappeared completely. However, during the second month of the treatment (maintenance: 25 mg/day) there was the appearance of new lesions that were considered as early recurrence.

Some oral agents (etretinate, metformin, and fish oil) have shown some effectiveness in small series of AN cases [1]. Because the treatment in AN needs to be continuous, the use of systemic drugs such as acitretin [7,10] and topicals, such as a combination of tretinoin 0.05%, hydroquinone 4%, and fluocinolone acetonide 0.01% [1], becomes limiting. For continuous use, emollient creams with keratolytic action such as ammonium lactate, urea, and salicylic acid have been described as the best options [5]. The use of laser can be a treatment option for specific body areas such as the armpits [6].

Conclusion

Generalized acanthosis nigricans, in the absence of systemic disease in children and adolescents, is rare. It is extremely important to exclude underlying causes of AN. So far, there is no standard treatment; several therapeutic options have shown varying success.

References

1. Adigun CG, Pandya AG. Improvement of idiopathic acanthosis nigricans with a triple combination depigmenting cream. *J Eur Acad Dermatol Venereol*. 2009 Apr;23(4):486-7. [PMID: 18721216]
2. Gönül M, Kiliç A, Cakmak SK, Gül U, Ekiz OD, Ergül G. Juvenile generalized acanthosis nigricans without any systemic disease. *Pediatr Int*. 2009 Aug;51(4):595-7. [PMID: 19674375]
3. Rai VM, Balachandran C. Generalized acanthosis nigricans in childhood. *Dermatol Online J*. 2006 Oct 31;12(6):14. [PMID: 17083894]
4. Isken T, Sen C, Iscen D, Yildiz K. Acanthosis nigricans and an alternative for its surgical therapy. *J Plast Reconstr Aesthet Surg*. Jan;62(1):148-50. [PMID: 18706881]
5. Sinha S, Schwartz RA. Juvenile acanthosis nigricans. *J Am Acad Dermatol*. 2007 Sep;57(3):502-8. [PMID: 17592743]
6. Rosenbach A, Ram R. Treatment of acanthosis nigricans of the axillae using a long-pulsed (5-msec) alexandrite laser. *Dermatol Surg*. 2004 Aug;30(8):1158-60. [PMID: 15274711]
7. Ozdemir M, Toy H, Mevlitoğlu I, Demirkesen C. Generalized idiopathic acanthosis nigricans treated with acitretin. *J Dermatolog Treat*. 2006;17(1):54-6. [PMID: 16511962]

8. Uyttendaele H, Koss T, Bagheri B, Schneiderman P, Silfen ME, Gallagher MP, Garzon M, Engler D. Generalized acanthosis nigricans in an otherwise healthy young child. *Pediatr Dermatol*. 2003 May-Jun;20(3):254-6. [PMID: 12787277]
9. Inamadar AC, Palit A. Generalized acanthosis nigricans in childhood. *Pediatr Dermatol*. 2004 May-Jun;21(3):277-9. [PMID: 15165217]
10. Skiljevic DS, Nikolic MM, Jakovljevic A, Dobrosavljevic DD. Generalized acanthosis nigricans in early childhood. *Pediatr Dermatol*. 2001 May-Jun;18(3):213-6. [PMID: 11438001]
11. Fitzpatrick TB. The validity and practicality of sun-reactive skin types I through VI. *Arch Dermatol*. 1988 Jun;124(6):869-71. [PMID: 3377516]
12. Lee M, Grassi M. Acanthosis nigricans in a patient treated with palifermin. *Cutis*. 2010 Sep;86(3):136-7. [PMID: 21049730]
13. Anderson SH, Hudson-Peacock M, Muller AF. Malignant acanthosis nigricans: potential role of chemotherapy. *Br J Dermatol*. 1999 Oct;141(4):714-6. [PMID: 10583123]
14. Blume-Peytavi U, Speiker T, Reupke H, Orfanos CE. Generalised Acanthosis nigricans with vitiligo. *Acta Derm Venereol*. 1996 Sep;76(5):377-80. [PMID: 8891012]
15. Schwartz RA, Janniger CK. Childhood acanthosis nigricans. *Cutis*. 1995 Jun;55(6):337-41. [PMID: 7648884]
16. Blobstein SH. Topical therapy with tretinoin and ammonium lactate for acanthosis nigricans associated with obesity. 2003 Jan;71(1):33-4. [PMID: 12553628]