

Secondary cutaneous diffuse large B-cell lymphoma presenting with focal vesicular lesions

Sarah F Alsukait¹ MBBS, Leena Y Taher² MBBS, Mohammed I AlJasser^{3,4} MBBS FRCPC

Affiliations: ¹Department of Dermatology, College of Medicine, King Saud University, Riyadh, Saudi Arabia, ²Department of Pathology, King Abdulaziz Medical City, Riyadh, Saudi Arabia, ³Division of Dermatology, King Saud bin Abdulaziz University for Health Sciences, Riyadh, Saudi Arabia, ⁴King Abdullah International Medical Research Center, Riyadh, Saudi Arabia

Corresponding Author: Sara Alsukait MBBS, Department of Dermatology, College of Medicine, King Saud University, Riyadh, Saudi Arabia, Email: salsukait@gmail.com

Abstract

Blister formation as a presentation of B-cell lymphoma is extremely rare; only one case has been previously reported in the literature to our knowledge. We report a patient known to have refractory systemic diffuse large B-cell lymphoma who presented with nodules with overlying vesicular lesions, which was consistent with secondary cutaneous spread of diffuse large B-cell lymphoma.

Keywords: B cell, blister, bullous, cutaneous, lymphoma, vesicular

Introduction

Diffuse large B-cell lymphoma (DLBCL) may arise from a nodal or an extra-nodal origin. Cutaneous involvement in DLBCL can be divided into 1) primary cutaneous DLBCL "leg-type," which manifests initially in the skin in the absence of systemic involvement at the time of presentation, and 2) secondary cutaneous DLBCL, in which systemic involvement is followed by secondary spread to the skin. Cutaneous DLBCL may present as tumors, nodules, papules, or indurated plaques [1]. Blister formation as a presentation of B-cell lymphoma has been rarely described previously [2]. We report a rare case of refractory systemic DLBCL with secondary cutaneous spread presenting with tumor nodules with overlying focal vesiculation.

Case Synopsis

A 61-year-old woman presented to our clinic with refractory DLBCL diagnosed in 2015. It had initially

started in the peri-ampullary region (of the duodenum), then progressed to the retro-peritoneum in July 2018, and the breast in December 2018. She had 6 cycles of R-CHOP (rituximab, cyclophosphamide, adriamycin, vincristine, and prednisolone) chemotherapy but did not achieve clinical remission. She later received two cycles of bendamustine and obinutuzumab. In January 2019, she presented with a 2-week history of asymptomatic localized blisters over her right thigh. Her lesions started to appear two months following her last chemotherapy cycle. Those lesions had been treated by the primary oncology team with intravenous acyclovir for more than one week with no improvement. Physical examination demonstrated several scattered one cm indurated erythematous nodules, some with overlying vesicles, on her right thigh (**Figure 1**). Histopathological

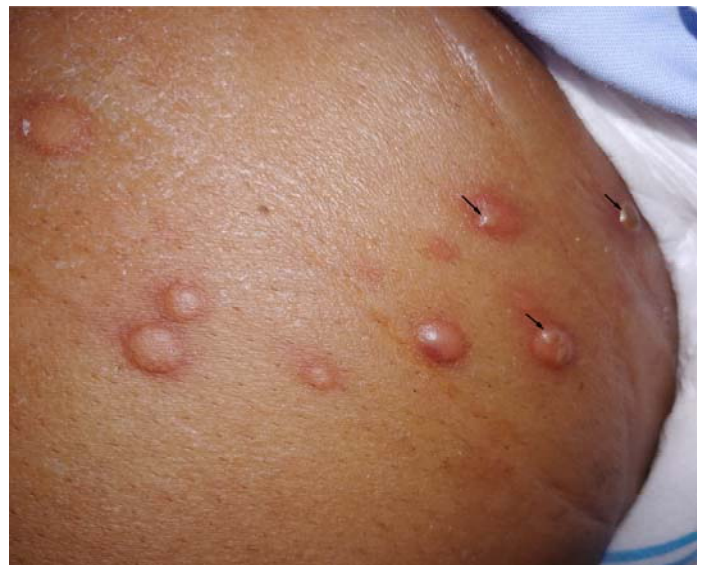

Figure 1. Scattered indurated erythematous nodules over the right thigh. Some nodules have overlying vesicles (arrows).

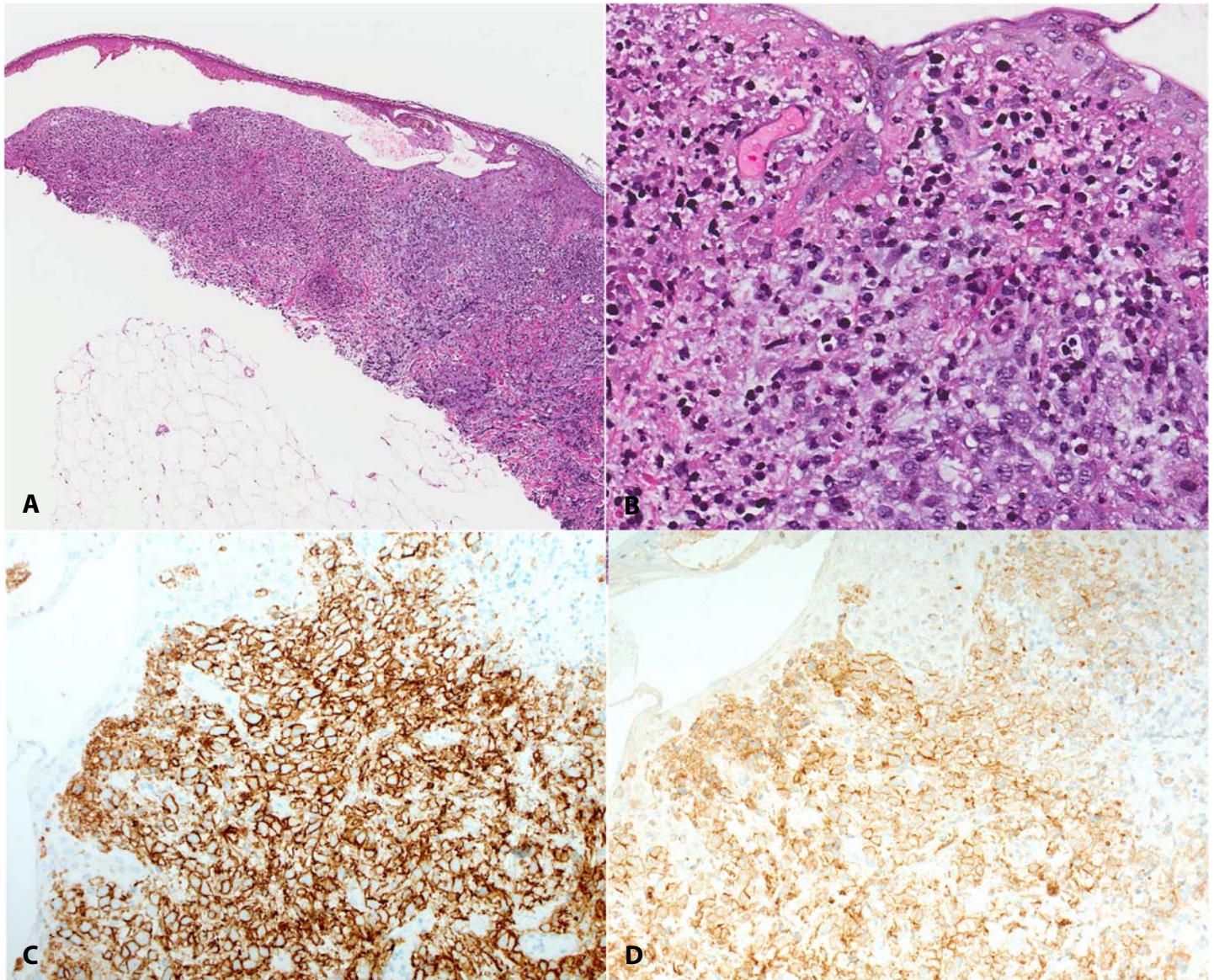


Figure 2. **A)** Diffuse infiltration of the superficial dermis by atypical large lymphoid cells with epidermal necrosis and intraepidermal bulla formation. H&E, 50 \times . **B)** High power view showing large lymphoid cells with irregular nuclei and visible nucleoli. H&E, 200 \times . **C)** The large cells are positive for CD20 immunostain, 200 \times . **D)** CD10 immunostain, 200 \times .

examination of a 4mm punch biopsy from a vesicle showed a dense diffuse dermal infiltrate composed of atypical large lymphoid cells with irregular nuclei and visible nucleoli with an overlying intraepidermal bulla formation (**Figure 2A, B**). Immunohistochemical staining of the atypical large lymphoid cells showed strong positivity for CD20 (**Figure 2C**), CD79a, BCL6, and CD10 (**Figure 2D**). Some tumor cells focally expressed CD30. Staining for CD3, MUM1, and EBV was negative. Ki67 proliferation index was approximately 60%. Based on the clinical, histological and immunohistochemical features, a diagnosis of secondary cutaneous relapsed DLBCL

was made. No specific treatment was provided for cutaneous involvement since lesions were asymptomatic.

Case Discussion

The association of bullous lesions with cutaneous lymphoma is rare. Most cases have been described in cutaneous T-cell lymphoma with more than 20 reported cases of bullous mycosis fungoides [3]. However, the occurrence of blisters in B-cell lymphomas is extremely rare and has only been reported once in the literature [2]. An association of

blistering diseases with DLBCL has been described with a paraneoplastic pemphigus-like eruption with negative autoantibodies [4]. Eosinophilic dermatosis of myeloproliferative disease presenting with edematous nodules with central vesicular eruption was reported once in a patient with stage IV systemic DLBCL [5]. Our patient had a history of systemic DLBCL that later spread to involve the skin in which the vesicles were located only on the indurated erythematous nodules involved by DLBCL. Histopathologically, there was a dense infiltrate of large atypical lymphoid cells beneath the bullae. Immunohistochemical staining of the skin biopsy revealed that the lymphoid cells were of B cell

lineage with the same immunohistochemical expression profile as her systemic DLBCL.

Conclusion

This is a rare, unique morphological presentation of secondary cutaneous B-cell lymphoma. Although the mechanism and significance of blister formation in DLBCL is unclear, patients with systemic DLBCL can develop secondary cutaneous involvement in the form of focal vesicles and a relapse should be considered.

Potential conflicts of interest

The authors declare no conflicts of interest.

References

1. Lee WJ, Won KH, Won CH, et al. Secondary Cutaneous Diffuse Large B-cell Lymphoma has a Higher International Prognostic Index Score and Worse Prognosis Than Diffuse Large B-cell Lymphoma, Leg Type. *Acta Derm Venereol.* 2016;96:245-50. [PMID: 26014205].
2. Okano M, Nakajima C, Uehara H, Tsujimoto T. Bullous lymphoma of the skin. *Br J Dermatol.* 1994;131: 709–712. [PMID: 7999606]
3. Korekawa A, Kaneko T, Nakajima K, et al. Mycosis fungoides bullosa associated with bullous pemphigoid. *Int J Dermatol.* 2015;54:e366-8. [PMID: 26204791].
4. Yamate T, Shono T, Shimada H, et al. Blistering disease associated with diffuse large B-cell lymphoma but without autoantibodies. *J Dermatol.* 2016;43:341-3. [PMID: 26660912].
5. Jencks A, Kiavash K, Daveluy S, et al. Eosinophilic Dermatitis of Myeloproliferative Disease in a Young Adult With Diffuse Large B-Cell Lymphoma. *Am J Dermatopathol.* 2019;41:303-308. [PMID: 30252694].