

# UC Davis

## Dermatology Online Journal

### Title

Trichophyllum rubrum endonyx onychomycosis resistant to standard oral and topical therapies

### Permalink

<https://escholarship.org/uc/item/3jb3t80q>

### Journal

Dermatology Online Journal, 21(9)

### Authors

Mulvaney, Patrick M  
Telang, Gladys H  
Jellinek, Nat

### Publication Date

2015

### DOI

10.5070/D3219028693

### Copyright Information

Copyright 2015 by the author(s). This work is made available under the terms of a Creative Commons Attribution-NonCommercial-NoDerivatives License, available at <https://creativecommons.org/licenses/by-nc-nd/4.0/>

Peer reviewed

## Case presentation

### **Trichophyllum rubrum endonyx onychomycosis resistant to standard oral and topical therapies**

Patrick M Mulvaney<sup>1</sup>, Gladys H Telang<sup>2</sup>, Nat Jellinek<sup>2</sup>

Dermatology Online Journal 21 (9): 8

<sup>1</sup>The Warren Alpert Medical School of Brown University, <sup>2</sup>Department of Dermatology

## Correspondence:

Patrick M Mulvaney  
The Warren Alpert Medical School of Brown University  
pat.mulvaney@gmail.com

---

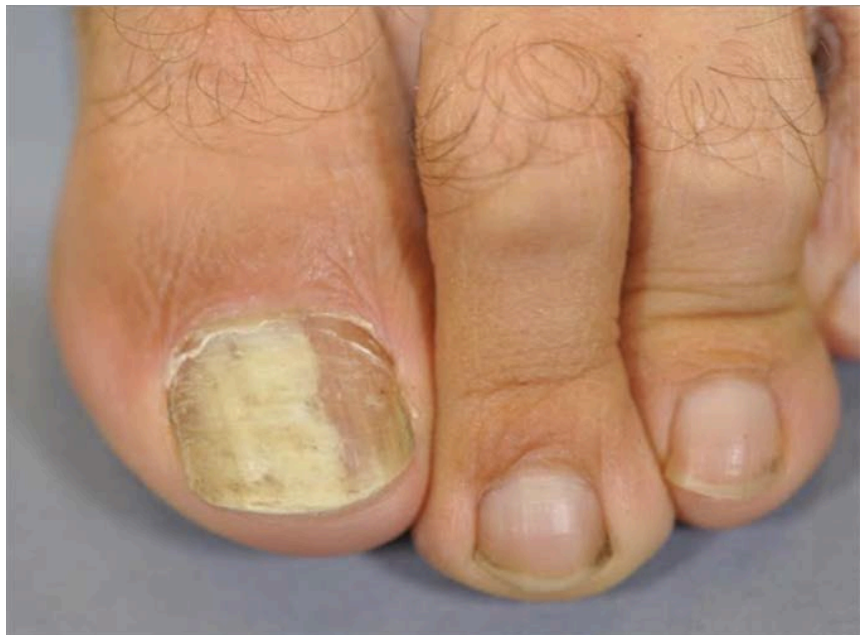## Abstract

We present a 45 year-old man with an eight-year history of discoloration of the nail plate on his left hallux. He had been treated with two courses of oral terbinafine and topical 8% ciclopirox for presumed onychomycosis. On exam, his left great toenail contained a wide yellow-white longitudinal band involving a majority of the nail plate. No subungual debris, hyperkeratosis, or paronychia inflammation was present in the affected nail. Histopathology of the nail plate revealed numerous fungal elements arranged transversely and longitudinally, solely within the keratin layers of the nail plate; these were highlighted with periodic acid-Schiff (PAS) stain confirming endonyx onychomycosis. Cultures grew *Trichophyton rubrum*. All types of onychomycosis under the new classification system proposed by Hay et al. have now been associated with *T. rubrum*. Endonyx related to *T. rubrum* may be a particularly difficult infection to treat with oral or topical agents owing to the absence of robust local immune response and limited drug penetration to the interior nail plate. Physicians should be aware that this type of infection may require treatment with dual-agent therapy or alternative modalities including chemical or surgical plate avulsion or photodynamic therapy.

## Case synopsis

**History:** A 45 year-old otherwise healthy, immunocompetent man was referred with an eight-year history of discoloration of the nail plate on his left hallux. He had been treated by his primary dermatologist with two courses of oral terbinafine, as well as topical 8% ciclopirox lacquer without improvement. He denied prior history of tinea pedis and reported that the nail discoloration “migrated” from one section of the nail to its current position.

**Physical Examination:** The left great toenail revealed a seven millimeter-wide milky, white-yellow longitudinal band, extending from the cuticle to the free margin, without distal onycholysis or subungual hyperkeratosis (Figure 1). Distally, the plate showed lamellar splitting only. There was no nail fold scaling



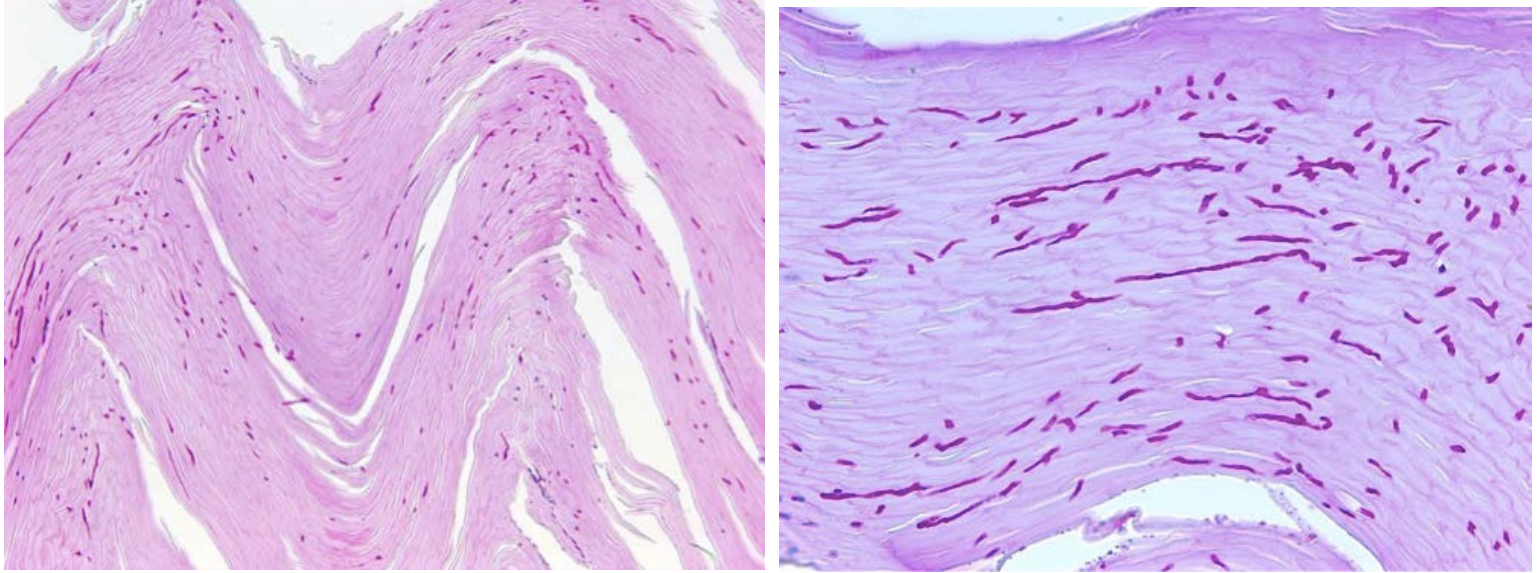
**Figure 1.** Left great toenail with wide yellow-white longitudinal band involving a majority of the nail plate. No subungual debris, hyperkeratosis or paronychia inflammation is present in the affected nail.

---

or inflammation.

**Laboratory:** The superficial plate was normal and a potassium hydroxide preparation of a scraping was negative for fungus. Culture of the nail clippings grew *Trichophyton rubrum*.

**Histopathology:** Clippings from the distal plate were obtained, fixed in formalin, and stained. Numerous fungal elements arranged transversely and longitudinally were present solely within the keratin layers of the nail plate and highlighted with periodic acid-Schiff (PAS) stain (Figures 2 and 3). There was no fungal invasion of the subungual keratin or inflammatory response.



**Figures 2.** Medium (10x) power, PAS stain of nail clipping showing fungal elements arranged longitudinally and transversely throughout the layers of the nail plate. **Figure 3.** High (40x) power, PAS stain of nail clipping again showing fungal elements distributed throughout the layers of the nail plate.

## Discussion

**Diagnosis:** *Trichophyton rubrum*-induced endonyx onychomycosis

**Comment:** Endonyx onychomycosis is a rare fungal infection of the nail plate that presents without corresponding subungual change or superficial infection. Despite infection of the interior plate, features commonly found in other types of onychomycosis, such as nail bed hyperkeratosis and onycholysis, are by definition absent [1]. Reported causal organisms include *Trichophyton violaceum*, *T. soudanense*, and recently *T. rubrum* [1-4]. Herein, we present a case of *T. rubrum* endonyx onychomycosis that was resistant to standard antifungal therapy.

Endonyx onychomycosis is characterized by a combination of the following features: lamellar splitting of the nail, discoloration of the nail plate, fungal hyphae in the interior of the nail plate, and notable absence of superficial plate involvement, nail bed invasion, or inflammation [1-2]. The mode of infection is purportedly direct penetration of fungal hyphae into the distal nail plate [1]. Reports of this infection pattern are rare, with causative organisms including *T. violaceum*, *T. soudanense*, and, recently, *T. rubrum*, for which Souza et al. reported successful treatment with photodynamic therapy (PDT) of 4 patients [3]. Isolated nail plate infection by *T. soudanense* has been explained by its affinity for hard keratins, as it also commonly causes endothrix infections on the scalp [2,4]. *T. rubrum* is believed to possess a unique biochemical armamentarium that allows it to produce widespread superficial infection without eliciting an aggressive host defense response [5]. This theory is consistent with the absence of inflammatory subungual reaction seen with *T. rubrum* endonyx and this may represent a second mechanism, in addition to hard keratin preference, to explain endonyx infections.

Of note, the infection in our patient did not respond to oral terbinafine, a reliable treatment for *T. rubrum* onychomycosis. Treatment failure of dermatophytes is rarely attributed to drug resistance [6]. In this case, it may represent undetected co-infection or a consequence of the inherent difficulty of treating endonyx with conventional methods owing to the absence of robust local immune response and limited penetration of drug to the interior nail plate. Our patient was offered a chemical plate avulsion followed by topical terbinafine cream to be applied daily under occlusion until clinical resolution. However, he declined to pursue any additional therapy or follow-up. When treating endonyx, a reasonable approach would start with standard systemic antifungal

agents and progress to local treatments such as nail avulsion or PDT, if necessary. A summary of all treated cases of endonyx onychomycosis can be found in Table 1.

**Table 1. Reported cases of treated endonyx onychomycosis**

	Patient	Sex/Age	Organism	Type of Treatment	Duration of Treatment	Response
Souza et al., 2013	1	F/43	<i>T. rubrum</i>	PDT + 2% methylene blue	6 months at 2 week intervals	Complete
-	2	F/28	-	-	-	Complete
-	3	M/65	-	-	-	Complete
-	4	M/39	-	-	-	Complete
Fletcher et al., 2001	5	F/9	<i>T. soudanense</i>	Griseofulvin (10 mg/kg)	Unknown	Lost to follow-up
-	6	M/7	-	-	-	Lost to follow-up
Present report*	7	M/45	<i>T. rubrum</i>	Terbinafine (x2), topical ciclopirox	Unknown	Lost to follow-up

## Conclusion

To date, all forms of onychomycosis categorized in the revised classification system by Hay et al., have been linked to *T. rubrum*. Although endonyx is a rare pattern of infection, its unique presentation provides insight into the virulence mechanisms of the pathogenic organisms. Our report suggests that it poses a difficult entity to treat with standard agents and may require dual-agent therapy or alternative modalities including chemical or surgical plate avulsion or PDT.

## References

1. Hay RJ, Baran R. Onychomycosis: a proposed revision of the clinical classification. *J Am Acad Dermatol* 2011;65:1219–27. [PMID: 21501889]
2. Tosti A, Baran R, Piraccini BM, Fanti PA. "Endonyx" onychomycosis: a new modality of nail invasion by dermatophytes. *Acta Derm Venereol.* 1999 Jan;79(1):52-3. [PMID: 10086860]
3. Souza LW, Souza SV, Botelho AC. Endonyx toenail onychomycosis caused by *Trichophyton rubrum*: treatment with photodynamic therapy based on methylene blue dye. *An Bras Dermatol.* 2013 Nov-Dec;88(6):1019-21. [PMID: 24474123]
4. Fletcher CL, Moore MK, Hay RJ. Endonyx onychomycosis due to *Trichophyton soudanense* in two Somalian siblings. *Br J Dermatol.* 2001 Oct;145(4):687-8. [PMID: 11703313]
5. Dahl MV, Grando SA. Chronic dermatophytosis: what is special about *Trichophyton rubrum*? *Adv Dermatol.* 1994;9:97-109; discussion 110-1. [PMID: 8060745]
6. Gupta AK, Kohli Y. Evaluation of in vitro resistance in patients with onychomycosis who fail antifungal therapy. *Dermatology.* 2003;207(4):375-80. [PMID: 14657630]