

UC Irvine

Western Journal of Emergency Medicine: Integrating Emergency Care with Population Health

Title

Cephalohematoma in a Patient with Ehlers-Danlos Syndrome

Permalink

<https://escholarship.org/uc/item/3dd8z9x7>

Journal

Western Journal of Emergency Medicine: Integrating Emergency Care with Population Health, 14(5)

ISSN

1936-900X

Authors

Felton, Brent M.
White, Josh M.
Jones, Ryan A.

Publication Date

2013

DOI

10.5811/westjem.2013.1.13409

Copyright Information

Copyright 2013 by the author(s). This work is made available under the terms of a Creative Commons Attribution-NonCommercial License, available at <https://creativecommons.org/licenses/by-nc/4.0/>

Peer reviewed

Cephalohematoma in a Patient with Ehlers-Danlos Syndrome

Brent M. Felton, DO**
Josh M. White, MD*†
Ryan A. Jones, MD**

* McLaren Greater Lansing Hospital, Department of Emergency Medicine, Lansing, Michigan
 † Michigan State University, Department of Emergency Medicine, East Lansing, Michigan

Supervising Section Editor: Rick McPheeters, DO

Submission history: Submitted September 11, 2012; Revision received November 21, 2012; Accepted January 22, 2013

Full text available through open access at http://escholarship.org/uc/uciem_westjem

DOI: 10.5811/westjem.2013.1.13409

Ehlers-Danlos syndrome is a rarely encountered connective tissue disorder characterized by skin hyper-elasticity, joint hyper-flexibility, and vasculature fragility. We report a 41-year-old female presenting with scalp swelling following minor head trauma. The patient presented with a large cephalohematoma that despite compressive measures and Factor IX administration continued to progress, necessitating transfer for definitive surgical intervention. The patient underwent surgical evacuation of approximately 1 liter of blood, followed by drain placement and compression dressing. This case underscores the importance for emergency physicians to recognize the potential vascular catastrophes these patients may present with following even minor injury. [West J Emerg Med. 2013;14(5):419–420.]

A 41-year-old female presented to the emergency department (ED) following a minor head injury 3 hours prior to arrival. She stated she was struck on the head by a falling broom handle and presented to the ED with a chief complaint of scalp swelling. She denied any loss of consciousness, but did report a past medical history significant for easy bruising and hematoma formation resulting from Ehlers-Danlos syndrome. The patient's past surgical history included numerous surgeries to remove hematomas from the chest wall and extremities resulting from her Ehlers-Danlos syndrome. Her family history was unknown as she was adopted. On initial presentation, the patient's vitals were within normal limits. Physical exam revealed a large scalp hematoma to the right side of the head extending down to the occipital region without evidence of focal neurological deficit. A stat computed tomography (CT) of the brain with angiographic study was ordered and is shown below (Figures 1 and 2). Upon returning from radiology, the patient's hematoma continued to progress into the facial tissues extending down to the level of the zygomatic arch, despite direct compressive measures. Laboratory results revealed a hemoglobin level of 9.3 g/dL, platelet count of 291,000, and an international normalized ratio (INR) of 1.39 sec. Factor IX complex was administered in the ED with a dosage of 1731 units given at 120 mL/hour, while direct pressure was continuously applied to the scalp and facial structures to prevent further progression of the hematoma. The case was discussed

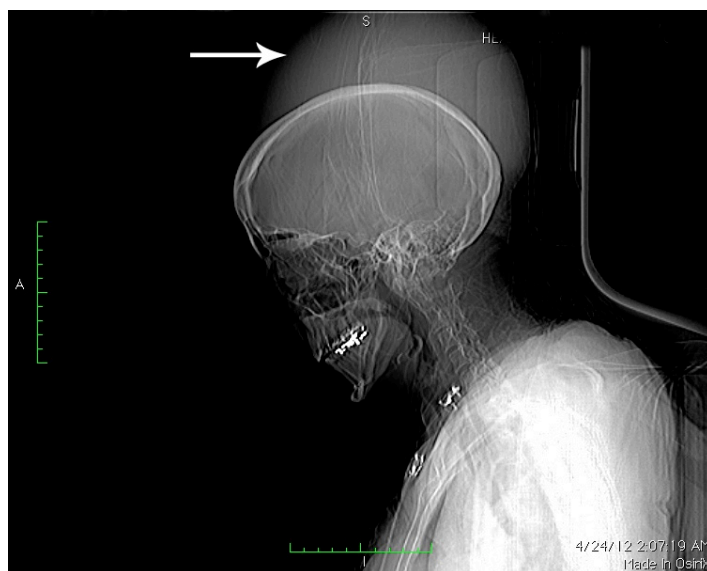

Figure 1. Computed tomography scout film demonstrating cephalohematoma.

with the on-call neurosurgeon and subsequent transfer to a nearby trauma center was initiated. Prior to transfer, the patient's blood pressure had deteriorated to 90/60 mmHg with a pulse of 128 beats-per-minute, and the hematoma had progressed below the level of the chin into the cervical soft tissues. The patient was transferred 2 hours and 20 minutes after arrival.

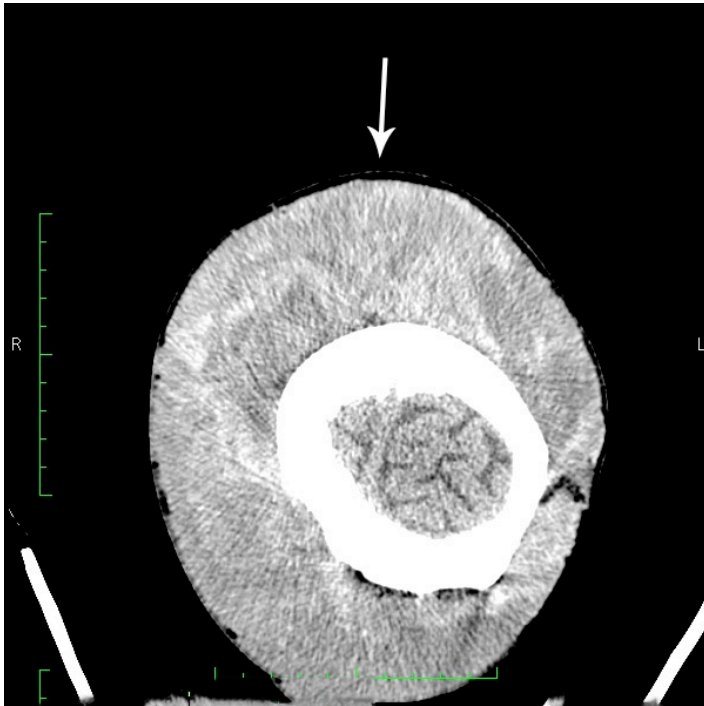


Figure 2. Computed tomography demonstrating extensive cephalohematoma in the soft tissues of the scalp.

Hospital Course

Upon arrival to the tertiary trauma center, the patient was taken emergently to the operating suite for evacuation of the cephalohematoma. Approximately 1 liter of blood was evacuated from the subgaleal space into a cell saver and subsequently returned to the patient intra-operatively. In addition, 4 units of packed red blood cells and 2 units of fresh frozen plasma were administered intra-operatively following a repeat hemoglobin level of 6.8 g/dL. Two Jackson Pratt drains were placed in combination with a pressure dressing after evacuation of the hematoma was completed. Following surgery the patient was left intubated until post-operative day number 7, but re-intubated shortly thereafter secondary to respiratory distress and subsequent development of pneumonia. The patient's hospital course was further complicated by necrosis of the overlying scalp necessitating a 14 x 13 cm abdominal wall skin graft. Thirty-one days following admission, the patient was discharged to a sub-acute rehabilitation facility.

DISCUSSION

First described by Job van Meekeren in 1682, Ehlers-Danlos is a rare connective tissue disease process resulting from abnormal collagen production.¹ Patients afflicted with the disorder suffer from a "classic" triad of hyperelasticity of the skin, hyperflexibility of the joints, and fragility of the skin and vessels.² Traditionally, the focus of emergency physicians has centered on the identification of life-threatening manifestations of the disease related to the great vessels (aneurysm, great vessel rupture, and dissection). The systemic nature of the disease, however, can lead to aneurysm formation and vessel

wall fragility in areas outside of the great vessels, resulting in ecchymosis and hematoma formation following even minor trauma.

A review of the literature revealed only 1 prior reported case of cephalohematoma in a patient with Ehlers-Danlos syndrome published in the *British Journal of Neurosurgery*.³ The patient, a 17-year-old male, presented with an occipital hematoma resulting from a minor trauma 3 days prior. The patient underwent needle aspiration, resulting in further expansion of the hematoma to encompass the scalp in its entirety. Subsequently, the patient was treated conservatively with pressure dressings, receiving 3 units of blood during his hospital course. Six weeks after the initial trauma, the patient had complete resolution of his symptoms. Unlike this case report, our patient's symptoms rapidly progressed from the onset of the initial trauma, and conservative treatment with compression dressings was unable to halt further progression of the hematoma. In both this prior case report and our patient's case, angiogram (CT in our patient's case) was unable to identify a culprit vessel responsible for the bleeding. Given our patient's hemodynamic instability, immediate transfer for definitive surgical treatment was deemed necessary. To date, there have been no published case reports evaluating the surgical management for cephalohematoma in patients with Ehlers-Danlos syndrome.

Our patient's initial presentation resulting from an otherwise benign trauma highlights the importance of rapidly initiating aggressive treatment modalities when conservative measures fail. Although Ehlers-Danlos is a rarely encountered connective tissue syndrome, this case underscores the importance for emergency physicians to recognize the potential vascular catastrophes these patients may present with following even minor injury.

Address for Correspondence: Brent Felton, DO. McLaren Greater Lansing Emergency Department, 401 W Greenlawn Ave., Lansing, MI 48910. Email: feltonbr@gmail.com.

Conflicts of Interest: By the WestJEM article submission agreement, all authors are required to disclose all affiliations, funding sources and financial or management relationships that could be perceived as potential sources of bias. The authors disclosed none.

REFERENCES

1. McKusick VA. Heritable disorders of connective tissue (4th ed). St. Louis, MO, CV Mosby; 1972:293-371.
2. Ronchese F. Dermatorrhaxis with dermatochalasis and arthrochalasis (the so-called Ehlers-Danlos syndrome). *Am J Dis Child*. 1936;51:1403-1414.
3. Morel C, Rizk T, Fischer G: Giant cephalhaematoma in a 17-year-old with Ehlers-Danlos Syndrome. *Br J Neurosurg*. 1998;2:54-55.