

## Case Presentation

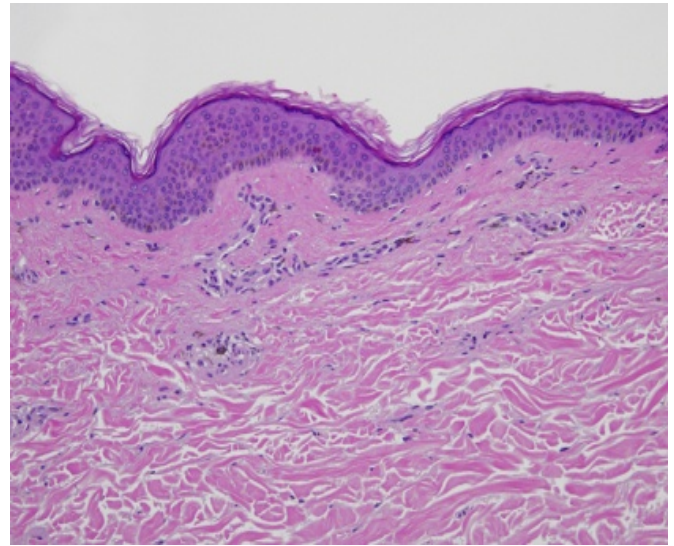
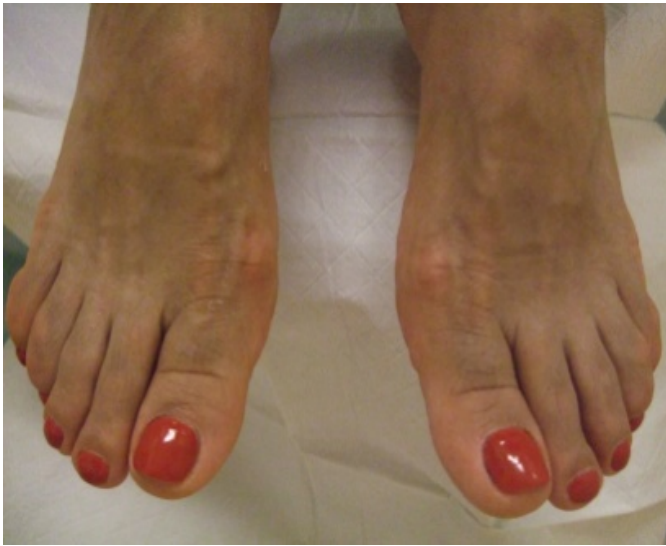Adnan Mir, MD, PhD, Kevin P. Boyd, MD, Shane A. Meehan, MD, and Beth McLellan, MD

Dermatology Online Journal 19 (12): 19

New York University School of Medicine

## Abstract

A 57-year-old woman with systemic lupus erythematosus and Sjögren syndrome presented with blue-grey hyperpigmentation of the face, upper back, and dorsal aspects of the feet after seven years of therapy with hydroxychloroquine. We present an unusual case of drug-induced hyperpigmentation.



## Case synopsis

A 57-year-old woman presented to the Dermatology Faculty Group Practice at the Joan H. Tisch Center for Women's Health with an acute eruption of cutaneous lupus erythematosus. She noticed incidentally that the skin on the dorsal aspects of her feet was darker than usual, but she could not tell how long this had been going on. Her feet had never been symptomatic.

Past medical history included systemic lupus erythematosus, Sjögren syndrome, hypothyroidism, and hyperglobulinemia. Medications included hydroxychloroquine for the past seven years, levothyroxine, cevimeline, fish oil, calcium carbonate, and vitamin D3.

**Physical Examination:** There was diffuse blue-grey discoloration, which was most noticeable on the face, upper back, and dorsal aspects of the feet.

**Histopathology:** A punch biopsy specimen was obtained from the upper back. Within the superficial dermis, there are yellow-brown, non-refractile and coarsely granular pigment deposits present within histiocytes and extracellularly. The pigment granules are highlighted by a Fontana-Masson stain.

**Diagnosis:** Hydroxychloroquine-induced hyperpigmentation

**Discussion:** We present the case of a patient presenting with diffuse blue-grey hyperpigmentation after long-term therapy with an antimalarial for systemic lupus erythematosus. Antimalarial-associated hyperpigmentation is a well-described phenomenon, which occurs in about 25% of patients on chloroquine, quinacrine, hydroxychloroquine, and mefloquine [1, 2]. Most of these cases result from chloroquine use. In a study of 209 patients that were treated with chloroquine and hydroxychloroquine, which are the two most commonly used antimalarials for rheumatologic and dermatologic conditions, 35% of patients on chloroquine and 13% of

patients on hydroxychloroquine developed hyperpigmentation [2]. The results of this study suggest that gender and race are not relevant. Overall, only 12 cases of hydroxychloroquine-induced hyperpigmentation have been reported [2-11].

The lesions of hydroxychloroquin-induced hyperpigmentation are typically blue-grey macules that enlarge and become confluent over the affected body parts. The distribution of hyperpigmentation varies widely (Table). The head, neck, trunk, upper extremities, and lower extremities are each reportedly involved in roughly one-half of the cases. It is typically bilateral, although one case reports unilateral involvement of the temple [9]. There is no apparent predilection for sun-exposed sites. The hyperpigmentation begins in most patients after about four months of treatment with hydroxychloroquine. After discontinuation of the drug, there is a reduction in the level of hyperpigmentation, but it does not resolve completely.

The pathophysiology of this process is unclear. There are dermal melanin deposits in biopsy specimens, but unlike a fixed drug eruption, these are not preceded by an inflammatory phase and damage to the dermoepidermal junction. *In vitro* and *in vivo* studies have shown that antimalarial drugs can bind to melanin [12], but the importance of this binding and its role in eye toxicity and skin hyperpigmentation has not been thoroughly investigated.

**Table.** Distribution of hyperpigmentation in reported cases of hydroxychloroquine-induced hyperpigmentation

	Distribution of hyperpigmentation
Current report	Face, upper back, dorsal feet
Cho 2012	Neck, upper trunk, upper extremities
Skare 2011	Not reported
Jallouli 2010	Anterior legs
Morrison 2009	Shins, forearms, hands
Melikoglu 2008	Dorsal hands
Puri 2008	Upper back, shoulders
Puri 2008	Right temple
Rood 2008	Forearms
Amichai 2007	Lower extremities
Millard 2004	Face, neck, trunk, axillae, posterior thighs
True 2002	All extremities, torso, hairline

## References

1. S. Kalia, J. P. Dutz. New concepts in antimalarial use and mode of action in dermatology. *Dermatol Ther* 2007;20:160
2. T. Skare, *et al.* Antimalarial cutaneous side effects: a study in 209 users. *Cutan Ocul Toxicol* 2011;30:45
3. B. Amichai, *et al.* Cutaneous hyperpigmentation during therapy with hydroxychloroquine. *J Clin Rheumatol* 2007;13:113
4. E. B. Cho, *et al.* Hydroxychloroquine-induced hyperpigmentation. *J Dermatol* 2012;39: 859
5. M. Jallouli, *et al.* Une pigmentation cutanee chez une patiente lupique. *Rev Med Interne*
6. M. A. Melikoglu, *et al.* Hydroxychloroquine-induced hyperpigmentation: a case report. *J Clin Pharm Ther* 2008;33:699
7. T. P. Millard, *et al.* Cutaneous hyperpigmentation during therapy with hydroxychloroquine. *Clin Exp Dermatol* 2004;29:92
8. L. K. Morrison, *et al.* Persistent cutaneous hyperpigmentation due to hydroxychloroquinone one year after therapy discontinuation. *Dermatol Online J* 2009;15:15
9. P. K. Puri, *et al.* Hydroxychloroquine-induced hyperpigmentation: the staining pattern. *J Cutan Pathol* 2008;35:1134
10. M. J. Rood, *et al.* Hyperpigmentation of the skin due to hydroxychloroquine. *Scand J Rheumatol* 2008;37:158
11. D. G. True, *et al.* Clinical images: Hydroxychloroquine-associated mucocutaneous hyperpigmentation. *Arthritis Rheum* 2002;46:1698
12. R. M. Ings. The melanin binding of drugs and its implications. *Drug Metab Rev* 1984;15:1183