

**UC Davis**  
**Dermatology Online Journal**

**Title**

Recurrent paraneoplastic wells syndrome in a patient with metastatic renal cell cancer

**Permalink**

<https://escholarship.org/uc/item/35w8r1q3>

**Journal**

Dermatology Online Journal, 20(6)

**Authors**

Rajpara, Anand  
Liolios, Ana  
Fraga, Garth  
[et al.](#)

**Publication Date**

2014

**DOI**

10.5070/D3206022875

**Copyright Information**

Copyright 2014 by the author(s). This work is made available under the terms of a Creative Commons Attribution-NonCommercial-NoDerivatives License, available at <https://creativecommons.org/licenses/by-nc-nd/4.0/>

Peer reviewed

## Case Presentation

### Recurrent paraneoplastic wells syndrome in a patient with metastatic renal cell cancer

Anand Rajpara MD<sup>1</sup>, Ana Liolios MD<sup>1</sup>, Garth Fraga MD<sup>2</sup>, Joseph Blackmon MD<sup>1</sup>

Dermatology Online Journal 20 (6): 14

<sup>1</sup>University of Kansas Medical Center, Department of Medicine, Division of Dermatology, Kansas City, KS

<sup>2</sup>University of Kansas Medical Center, Department of Pathology and Laboratory Medicine, Kansas City, KS

## Correspondence:

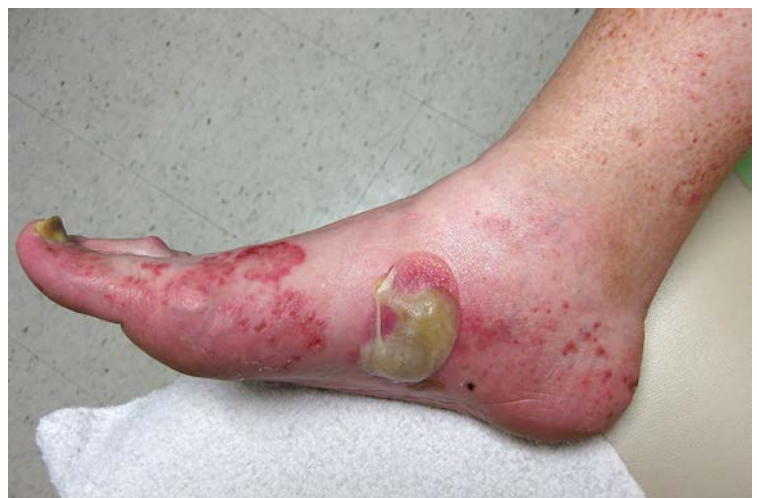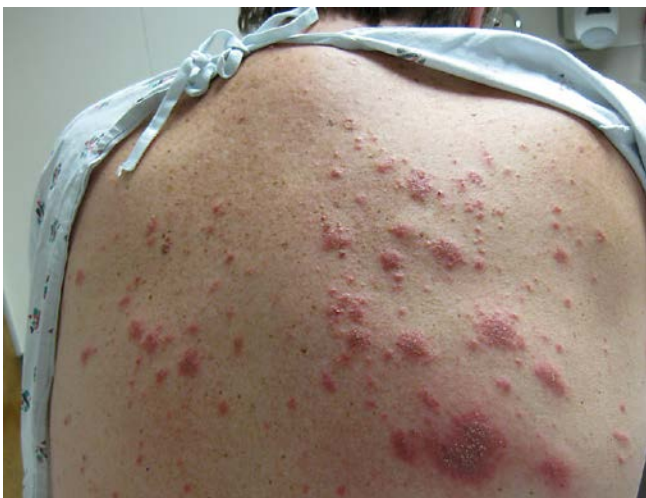Joseph Blackmon, MD  
PGY4 Dermatology Resident  
Department of Dermatology  
3901 Rainbow Boulevard  
Kansas City, Kansas 66160  
Tel: (913) 588-5000  
Email: jblackmon@kumc.edu

## Abstract

A 58-year-old man with a history of hyperlipidemia and hypertension presented to the dermatology clinic with a 3-month history of a sudden onset, progressively worsening pruritic eruption involving the torso and extremities. Prior treatment included azithromycin and oral and intramuscular steroids, without improvement. Laboratory results demonstrated a serum eosinophil count of  $7 \times 10^3/\mu\text{L}$  (normal 0-4). A 4-mm punch biopsy of the plaque on the patient's left thigh revealed a diffuse dermatitis with innumerable eosinophils with formation of "flame figures." Histologically, these findings are consistent with a diagnosis of Wells syndrome (WS). A work up for possible underlying malignancy found that the patient had underlying clear cell renal carcinoma. The eruption largely resolved following right laparoscopic nephrectomy with negative surgical margins, thus confirming the diagnosis of paraneoplastic WS. However, 2 years later the patient developed metastasis to his liver, lungs, and ribs. The patient's cancer has continued to progress despite treatment with high-dose interleukin-2, oral sunitinib, afinitor, avastin, azacytidine, and currently axitinib. Our case is the first to describe eosinophilic cellulitis arising in a patient with underlying renal cell carcinoma.

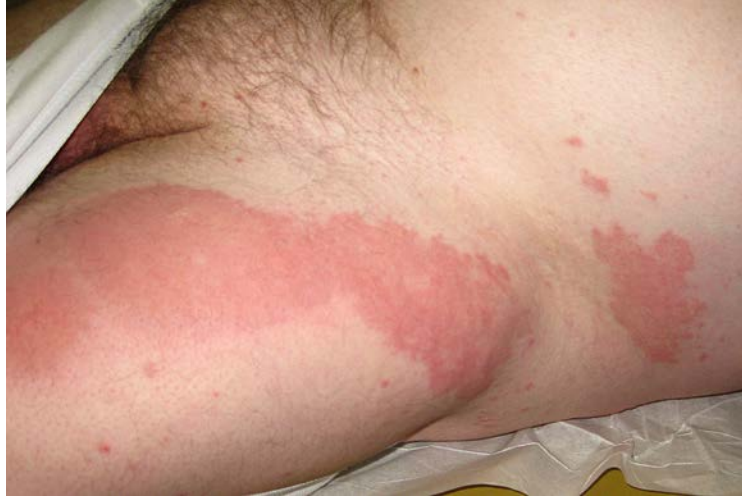**Keywords:** Wells syndrome, flame figures, renal cell carcinoma, eosinophilic cellulitis

## Case synopsis



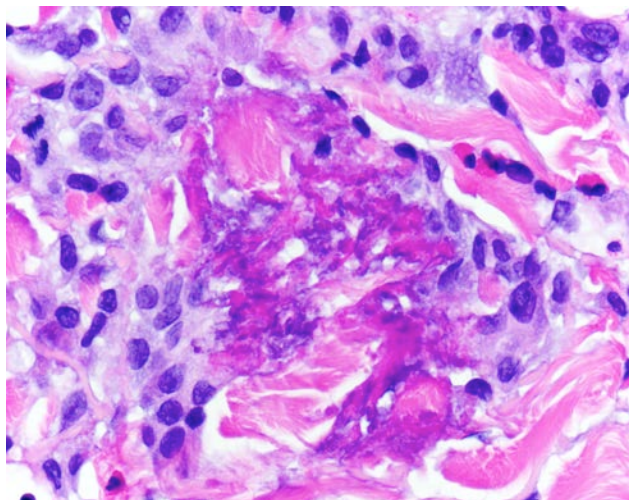
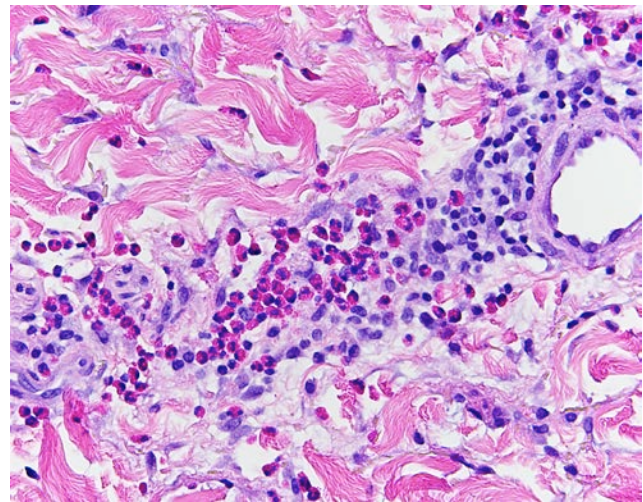
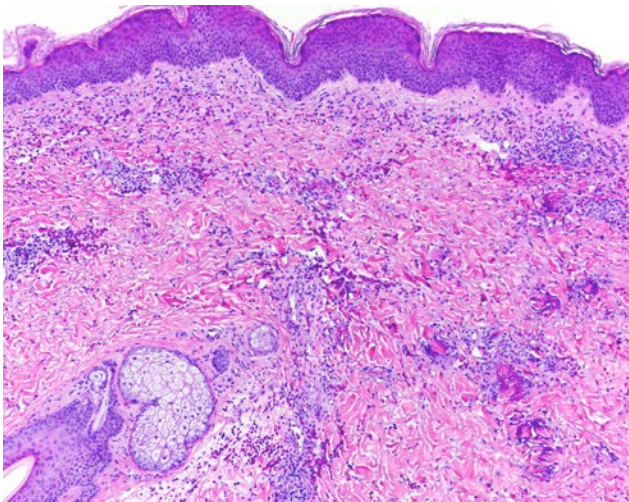
**Figure 1.** Wells Syndrome, upper back: scattered red, excoriated papules and edematous plaques

**Figure 2.** Wells Syndrome, right medial foot: tense bulla on an erythematous base: Scattered red papules, petechiae and vesicles along with a well-demarcated polycyclic red plaque are exhibited on the right medial dorsal foot.



**Figure 3.** Wells Syndrome, left anterior thigh and flank: red, thin, predominantly well-demarcated plaques with a few scattered red papules

A 58-year-old man with a history of hyperlipidemia and hypertension presented to the dermatology clinic in 2008 with a 3-month history of a sudden onset, progressively worsening pruritic eruption involving the torso and extremities. Prior treatment included azithromycin and oral and intramuscular steroids, without improvement. Physical examination revealed diffuse excoriated erythematous to violaceous polymorphic edematous plaques and papules located on his torso and extremities (Figure 1). He subsequently developed lower extremity edema, a firm bulla on the right foot (Figure 2), and a 12.5cm x 36cm well-demarcated edematous erythematous plaque on the left hip and thigh (Figure 3).



**Figure 4.** Wells Syndrome, Hematoxylin & Eosin, 40x: moderately dense superficial and deep perivascular infiltrate consisting of numerous eosinophils and lymphocytes.

**Figure 5.** Wells Syndrome, Hematoxylin & Eosin, 200x: Flame figure consisting of an aggregate of eosinophil major basic protein surrounded by a palisade of histiocytes

**Figure 6.** Wells Syndrome, Hematoxylin & Eosin, 200x: Flame figure consisting of an aggregate of eosinophil major basic protein surrounded by a palisade of histiocytes.

Laboratory results demonstrated a serum eosinophil count of  $7 \times 10^3/\mu\text{L}$  (normal 0-4). A 4-mm punch biopsy of the plaque on the patient's left thigh was obtained for histologic analysis. The biopsy specimen reveals a diffuse dermatitis with innumerable eosinophils with formation of so-called "flame figures," consisting of degranulated eosinophilic major basic protein surrounded by a palisade of histiocytes. Histologically, these findings are consistent with a diagnosis of Wells syndrome (WS) (Figures 4,5,6).

As the patient failed numerous attempted therapies including high potency topical steroids, high dose oral prednisone, intramuscular steroids, as well as oral antibiotics and oral terbinafine, a work up for possible underlying malignancy was initiated. A CT scan revealed a 5.8 cm mass in the right kidney suggestive of renal cell carcinoma. Nephrectomy confirmed the renal mass was clear cell renal carcinoma. The eruption largely resolved and was able to be controlled with topical steroids following right laparoscopic nephrectomy with negative surgical margins, thus confirming the diagnosis of paraneoplastic WS.

In 2010, shortly after being diagnosed with metastatic renal cell cancer, the patient again developed pruritic, erythematous, and edematous papules and plaques on his torso and extremities. A clinical diagnosis of WS was made and the patient's rash responded well to topical clobetasol ointment. However, the patient's metastatic disease continued to progress despite treatment with high-dose interleukin-2, oral sunitinib, everolimus, bevacizumab, azacitidine, axitinib, and pazopanib. In June of 2013 the patient presented to the dermatology clinic with a slightly different eruption consisting of large beefy red erythematous plaques with overlying vesicles and bullae on bilateral medial lower extremities, dorsal feet, and toes. A punch biopsy from the left medial lower leg revealed a perivascular and interstitial dermatitis with copious eosinophils and massive papillary edema consistent with WS. Currently the patient's eruption is controlled with clobetasol ointment and he is on capecitabine and gemcitabine for the treatment of his metastatic renal cell cancer.

## Discussion

In 1971, Wells described a clinical syndrome that he called "granulomatous dermatitis with eosinophilia," later renaming the histological and clinical picture "eosinophilic cellulitis" [1], or Wells syndrome (WS). Wells syndrome is characterized by the sudden onset of pruritic, erythematous papules and plaques, typically on the extremities. Associated edema can cause bullae. WS is often confused with acute infectious cellulitis. However, the Wells eruption is typically cool to the touch and is unresponsive to antimicrobial therapy [1,2]. Initial lesions often show central involution over a 2-3 day period, then turn from a red-brown color to a grey-blue color and become indurated, lasting weeks to months. Eventually the skin clears without scarring [1,2]. Patients often have peripheral blood eosinophilia and some have been reported to have bone marrow eosinophilia [1,2,3].

On histologic exam, acute lesions show dense dermal eosinophilic infiltrates and dermal edema. Subacute lesions show giant cells, histiocytes, and flame figures in the dermis [1,2,4]. Flame figures result when histiocytes organize around collagen bundles and become coated with eosinophilic major basic protein [1,2,3,4,5,8]. Flame figures are found in eosinophilic cellulitis, but are not pathognomonic because they may also be seen in bullous pemphigoid, herpes gestationis, arthropod bites, and tinea pedis [1].

Treatment includes systemic corticosteroids, but many cases resolve spontaneously without therapy [1,2]. Other treatments include minocycline, nicotinamide, griseofulvin, azathioprine, and low-dose cyclosporine [1,3,9,10]. In one case of WS associated with colon adenocarcinoma, curative hemicolectomy was associated with remission of the eosinophilic cellulitis [8].

Known associations with eosinophilic cellulitis include fungal infections, hematologic malignancies, myelofibrosis, medications, and surgeries [1,3,5,6]. There have been reports of non-hematologic malignancies associated with eosinophilic cellulitis: two reports of squamous cell carcinoma (bronchial and anal), one report of nasopharyngeal carcinoma, and a recent case report of colon adenocarcinoma associated with eosinophilic cellulitis [5,7,8]. Our case is the first to describe eosinophilic cellulitis arising in a patient with underlying renal cell carcinoma. Renal cell carcinoma accounts for approximately two percent of adult malignancies, is more common in men than women (3:2), and has the highest incidence in the 6<sup>th</sup> decade of life [11].

## References

1. Wells GC, Smith NP. Eosinophilic cellulitis. *Br J Dermatol.* 1979;100: 101-108. [PMID: 427009]
2. Spigel GT, Winkelmann RK. Wells' Syndrome: Recurrent Granulomatous Dermatitis With Eosinophilia. *Arch Dermatol.* 1979;115: 611-613. [PMID: 443839]
3. Moossavi M, Mehregan DR. Wells' syndrome: a clinical and histopathologic review of seven cases. *Int J Dermatol.* 2003;42: 62-67. [PMID: 12581147]
4. Mitchell AJ, Anderson TF, Headington JT, Rasmussen JE. . Recurrent Granulomatous Dermatitis with Eosinophilia: Wells' Syndrome. *Int J Dermatol.* 1984;3: 198-202. [PMID: 6724778]
5. Brehmer-Andersson E, Kaaman T, Skog E, Frithz A. The Histopathogenesis of the Flame Figure in Wells' Syndrome Based on Five Cases. *Acta Derm Venereol.* 1986;66: 213-219. [PMID: 2426897]
6. Weiss G, Shemer A, Confino Y, Kaplan B, Trau H. Wells' Syndrome: reports of a case and review of the literature. *Int J Dermatol.* 2001;40: 148-152. [PMID: 11328401]
7. Farrar CW, Guerin DM, Wilson NJ. Eosinophilic cellulitis associated with squamous cell carcinoma of the bronchus. *Br J Dermatol.* 2001;45(4): 678-679. [PMID: 11703307]
8. Hirsch K, Ludwig RJ, Wolter M, Zollner TM, Hardt K, Kaufmann R, Boehncke W. Eosinophilic cellulitis (Wells' syndrome) associated with colon carcinoma. *J German Dermatol Soc.* 2005;3: 530-531. [PMID: 15967014]
9. Stam-Westerveld EB, Daenen S, Van der Meer JB, Jonkman MF. Eosinophilic cellulitis (Wells' syndrome): treatment with minocycline. *Acta Derm Venereol.* 1998;78(2):157. [PMID: 9534905]
10. Herr H, Koh JK. Eosinophilic cellulitis (Wells' syndrome) successfully treated with low-dose cyclosporine. *J of Korean Med Science.* 2001; 16(5): 664-668. [PMID: 11641541]
11. Pascual DD, Borque A. Epidemiology of Kidney Cancer. *Adv Urol.* 2008; 2008: 782381. [PMID: 19009036]