

UC Davis

Dermatology Online Journal

Title

Eruptive nodules of the head and neck: a case report of metastatic prostate cancer

Permalink

<https://escholarship.org/uc/item/2sd696sc>

Journal

Dermatology Online Journal, 20(2)

Authors

Brown, Gabrielle
Kurtzman, Drew
Lian, Fangru
[et al.](#)

Publication Date

2014

DOI

10.5070/D3202021544

Copyright Information

Copyright 2014 by the author(s). This work is made available under the terms of a Creative Commons Attribution-NonCommercial-NoDerivatives License, available at <https://creativecommons.org/licenses/by-nc-nd/4.0/>

Peer reviewed

Case Presentation

Eruptive nodules of the head and neck: a case report of metastatic prostate cancer

Gabrielle Brown MS*¹, Drew Kurtzman MD*², Fangru Lian MD³, James Sligh MD PhD²

Dermatology Online Journal 20 (2): 11

*First Co-authors.

University of Arizona, Tucson, Arizona, ¹College of Medicine, ²Division of Dermatology, ³Department of Pathology

Correspondence:

Gabrielle Brown, M.S.
gebrown@email.arizona.edu
131 Judah Street
San Francisco, CA 94122
Phone: (602) 321-7767
Fax: (520) 626-6033

Abstract

Cutaneous metastasis is an uncommon but well recognized phenomenon occurring as a result of internal malignancy. Cancers most often associated with cutaneous metastasis are melanoma and primary malignancies of the breast and head and neck. Cutaneous metastatic prostate cancer is rare, representing only 1% of cases. Herein we report a case of advanced prostate cancer with multiple cutaneous metastases and briefly review the literature highlighting the clinical and histopathological features as well as a management approach to the patient with metastatic prostate cancer involving the skin.

Key Words: cutaneous metastasis, prostate carcinoma, cutaneous manifestation of systemic disease

Introduction

Cutaneous metastasis is an uncommon occurrence in patients with cancer. With an estimated prevalence of 0.6%-10%, recognition nonetheless remains paramount because skin metastases may represent the initial sign of visceral malignancy [1,2]. Melanoma, breast cancer, and cancers of the head and neck are the most common primary malignancies with metastases to the skin [1,2,3]. Despite being the most common internal malignancy and the second leading cause of cancer-related mortality in men in the United States, prostate cancer represents approximately only 1% of cutaneous metastases. More common metastatic sites include bone, lymph nodes, liver, and adrenal glands [2,4,5]. Adenocarcinoma is the most common primary tumor of the prostate with metastatic potential for the skin [1]. Metastases are typically observed late in the clinical course. We report a case of metastatic prostate carcinoma presenting as eruptive nodules of the head and neck in an elderly man with advanced disease.

Case synopsis

An 81-year-old South African man with a history of prostate cancer presented to our clinic for the evaluation of new onset papules and nodules involving his head and neck. He reported that these lesions developed abruptly over a six-week period. The nodules were asymptomatic and had not been previously treated. His dermatologic history was remarkable for a basal cell carcinoma of the nasal dorsum that had been surgically excised four years prior. His medical history was notable for a provisional diagnosis of advanced adenocarcinoma of the prostate, which was rendered four years earlier after a screening serum PSA revealed a level of 422 ng/ml. At that time, he refused a diagnostic prostate biopsy and declined therapy. Two years subsequent to this initial

evaluation, he was hospitalized with acute urinary retention secondary to a large pelvic mass. A CT scan of the chest, abdomen and pelvis also revealed widespread bony lesions consistent with disseminated metastases. His serum PSA was approximately 1900 ng/ml. He again refused a diagnostic biopsy but initiated androgen deprivation therapy that he prematurely terminated. He was lost to follow up for a year before presenting to our clinic.

On examination, numerous discrete pink and skin-colored fleshy papules and nodules with prominent telangiectasia were present on his scalp, forehead, pre-auricular cheeks, and neck (Figure 1). He had a well-healed linear scar on his nasal dorsum and chronic actinic damage.

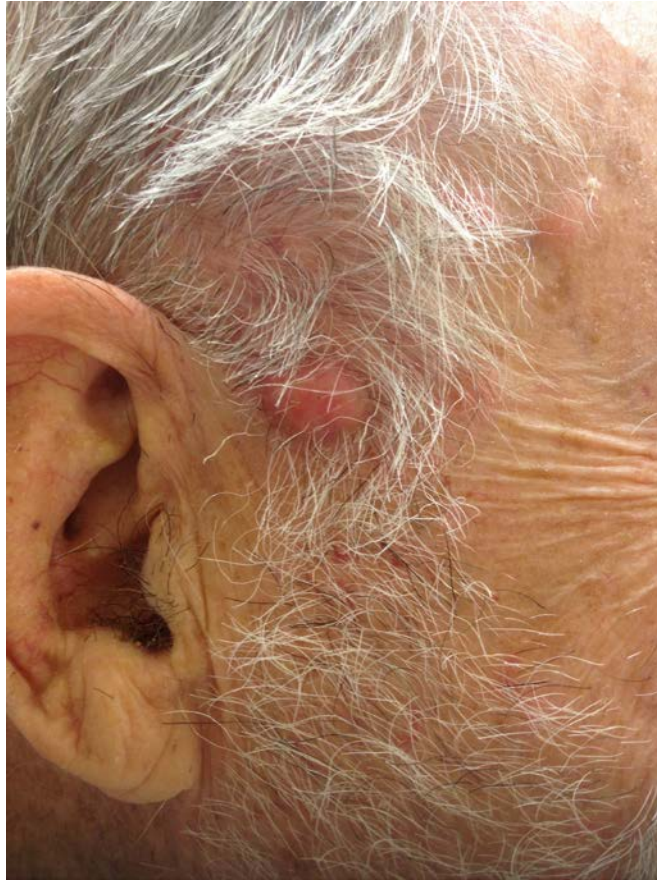

Figure 1. Discrete pink nodules with prominent telangiectasia involving the head and neck

Lesional biopsies from the right occipital scalp and lateral neck were obtained for microscopic examination.

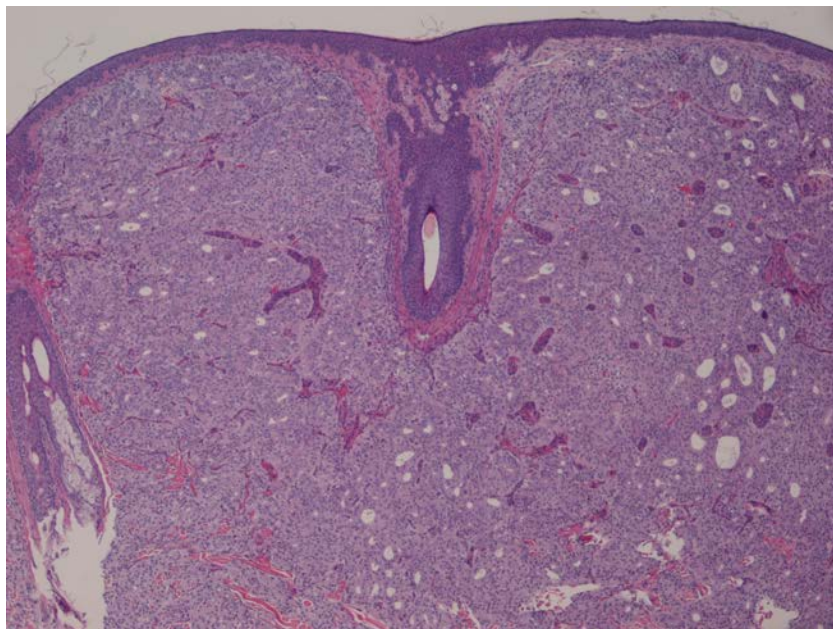


Figure 2. Low magnification reveals sheets of malignant cells diffusely infiltrating the entire dermis. Focal gland formation is prominent.

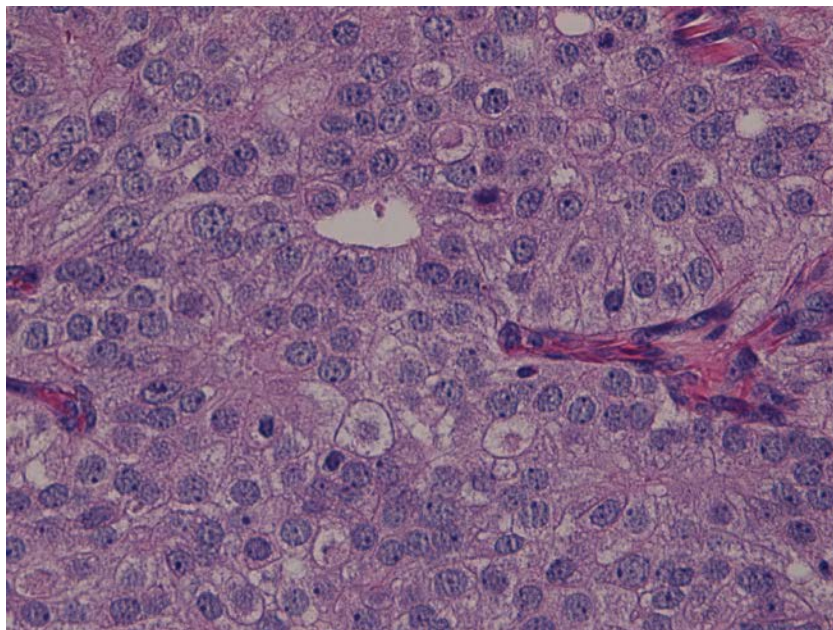


Figure 3. On higher magnification, sheets of monomorphic malignant cells with prominent nucleoli are evident.

Histopathologic evaluation revealed diffuse sheets of large, pleomorphic cells infiltrating the superficial and deep dermis with a conspicuous Grenz zone and focal areas of gland formation (Figure 2). On higher magnification, prominent nucleoli and cytologic atypia were readily identified (Figure 3). Prostate origin was confirmed with PSA and ERG immunohistochemical stains establishing the diagnosis of metastatic prostate adenocarcinoma.

The patient was restarted on hormonal therapy by his medical oncologist with modest regression of his cutaneous nodules after two months. Despite treatment, his PSA levels increased from 877 ng/ml to over 1300 ng/ml over the course of three months, necessitating an intensified regimen with additional anti-androgen therapies.

Discussion

Numerous presentations of cutaneous metastases occurring as a result of an internal malignancy have been described posing a diagnostic challenge for the clinician. Cutaneous metastases of prostate cancer are most frequently characterized by multiple pink and flesh colored indurated nodules occurring near the primary site such as the genitalia, lower abdomen, and anterior thighs [1,6]. Less common anatomic sites include the chest wall, umbilicus (Sister Mary Joseph nodule), and scalp. Additional presentations have been described including lymphedema, isolated macular telangiectasia, and non-specific morbilliform and zosteriform eruptions [1,2,5,7]. The diagnosis may be rendered after fine needle aspiration or lesional biopsy, though it may be unnecessary in a patient with known disseminated disease [5,6].

The histopathologic features of cutaneous metastatic prostate carcinoma recapitulate those of the primary tumor. Sheets of undifferentiated cells diffusely infiltrate the dermis often with a conspicuous Grenz zone. Gland-like structures may form if the primary tumor is of the adenocarcinoma type. Although cellular pleomorphism may be subtle, nuclear atypia characterized by hyperchromasia and prominent eosinophilic nucleoli is usually present [1]. Adnexal structures may likewise be infiltrated by malignant cells [4].

Immunohistochemistry can be a useful adjunct for confirming the primary tumor in equivocal cases. Prostate-specific antigen (PSA) is the most commonly employed stain [1,3]. Although rather specific for prostate tissue, PSA may rarely be expressed in small cell carcinoma of the lung and poorly differentiated neuroendocrine carcinomas [3]. Notably the absence of PSA positivity does not exclude prostate carcinoma because highly undifferentiated tumors may lack PSA expression [4]. In such cases, prostate acid phosphatase (PAP) is a useful ancillary marker [1,3]. ERG, a transcription factor normally expressed by endothelial cells, has recently been identified as a useful immunohistochemical marker for prostate carcinoma and vascular tumors. Although not typically expressed in normal prostate tissue, ERG is selectively expressed in approximately 50% of primary and metastatic prostatic adenocarcinomas [1,8].

The appearance of skin metastases is associated with widespread disease and a poor prognosis. The average survival is approximately seven months after the onset of skin involvement [2,6]. Therapeutic options for cutaneous metastasis are primarily palliative and include excision, radiation therapy, and intralesional chemotherapy [2]. Such therapies must be carefully selected

and approached on a case-by-case basis. It is notable that treatment of the primary malignancy may result in regression of cutaneous metastases.

Although cutaneous metastasis is an uncommon presentation of prostate cancer, it nonetheless remains an important diagnostic consideration in patients with advanced disease. The implications are primarily prognostic; cutaneous metastasis represents a harbinger of a poor overall outcome.

References

1. Alcaraz I, Cerroni L, Rutten A, Kutzner H, Requena L. Cutaneous metastases from internal malignancies: a clinicopathologic and immunohistochemical review. *Am J Dermatopathol*. 2012 Jun;34(4):347-93. [PMID:22617133]
2. Wang SQ, Mecca PS, Myskowski PL, Slovin SF. Scrotal and penile papules and plaques as the initial manifestation of a cutaneous metastasis of adenocarcinoma of the prostate: case report and review of the literature. *J Cutan Pathol*. 2008 Jul;35(7):681-84. [PMID:18201228]
3. Rattanasirivilai A, Kurban A, Lenzy YM, Yaar R. Cutaneous metastasis of prostatic adenocarcinoma: a cautionary tale. *J Cutan Pathol*. 2011 Jun;38(6):521-24. [PMID:21306410]
4. Duran E, Paradela A, Farina M, et al. Cutaneous Metastases from Prostatic Carcinoma. *J Surg Oncol*. 1996 Jun;62(2):144-47. [PMID:8649042]
5. Wu J, Huang D, Pang K, et al. Cutaneous metastasis to the chest wall from prostate cancer. *Int J Dermatol*. 2006 Aug;45(8):946-48. [PMID:16911381]
6. Bailey C, Broadbent A. Cutaneous metastases of prostate cancer. *J Palliat Med*. 2007 Aug;10(4):980-82. [PMID:17803422]
7. Stanko C, Grandinetti L, Baldassano M, et al. Epidermotropic metastatic prostate carcinoma presenting as an umbilical nodule-Sister Mary Joseph nodule. *Am J Dermatopathol*. 2007 Jun;29(3):290-92. [PMID:17519629]
8. Miettinen M, Wang ZF, Paetau A, Tan SH, Dobi A, Srivastava S, Sesterhenn I. ERG transcription factor as an immunohistochemical marker for vascular endothelial tumors and prostatic carcinoma. *Am J Surg Pathol*. 2011 Mar;35(3):432-41. [PMID:21317715]