

# UC Davis

## Dermatology Online Journal

### Title

Multiple pilomatricomas in the setting of myotonic dystrophy

### Permalink

<https://escholarship.org/uc/item/2q9081v5>

### Journal

Dermatology Online Journal, 22(12)

### Authors

Park, Joyce H  
Terushkin, Vitaly  
Brinster, Nooshin  
et al.

### Publication Date

2016

### DOI

10.5070/D32212033380

### Copyright Information

Copyright 2016 by the author(s). This work is made available under the terms of a Creative Commons Attribution-NonCommercial-NoDerivatives License, available at <https://creativecommons.org/licenses/by-nc-nd/4.0/>

Peer reviewed

# Multiple pilomatricomas in the setting of myotonic dystrophy

Joyce H. Park, MD, Vitaly Terushkin, MD, Nooshin Brinster, MD, Marie Leger, MD PhD, Nicholas A. Soter, MD

Ronald O. Perelman Department of Dermatology, NYU School of Medicine, NYU Langone Medical Center

## Abstract

The association between multiple pilomatricomas and the autosomal dominant neurodegenerative disorder myotonic dystrophy has been described in the literature. Although the mechanism is unknown, it is hypothesized that the dystrophin protein kinase mutation in myotonic dystrophy affects intracellular calcium levels, which alter proliferation and terminal differentiation that leads to cells that are observed in pilomatricomas. We present a patient with multiple, symptomatic pilomatricomas and myotonic dystrophy, with a strong family history of both of these rare disorders.

## Case Presentation

**PATIENT:** 30-year-old-man

**DURATION:** Over ten years

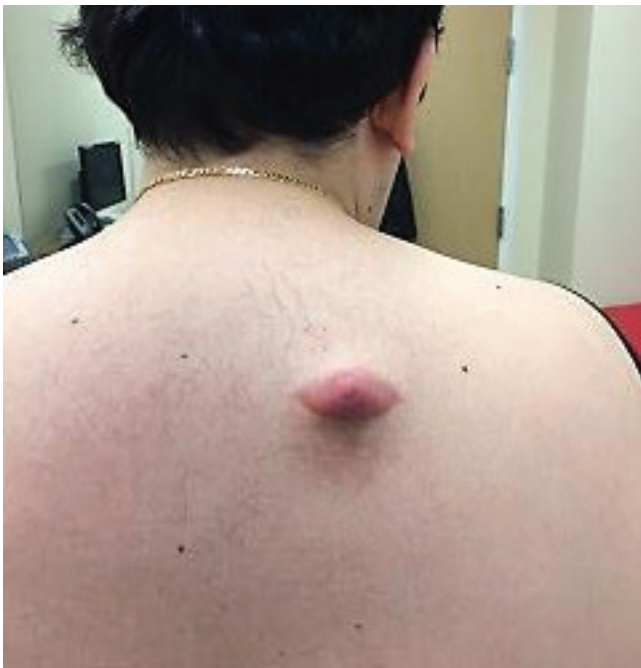**DISTRIBUTION:** Left forearm and back

**HISTORY:** A 30-year-old-man presented to the Skin and Cancer Unit for evaluation of several, tender, firm, subcutaneous nodules that have been present for over ten years. The nodules were initially asymptomatic, but the lesions on his right upper back and left forearm have grown in size in the past three months and have become tender to palpation. The patient and his father do not recall ever having the lesions biopsied in the past, and the patient had never tried any treatments for the nodules.

On the day of presentation, one nodule on the left forearm underwent an excisional biopsy, and two weeks later, the nodule on his right upper back also was excised.

Medical history included myotonic dystrophy that was diagnosed at the age of 14 when he developed acute shoulder pain and weakness. His two sisters and his mother also have a diagnosis of myotonic dystrophy, and both of his sisters have multiple, similar skin lesions throughout their bodies as well. Other medical problems include obstructive sleep apnea. He does not have diabetes mellitus, cataracts, or heart failure although he has had a loop recorder implanted for the last 18 months to monitor for arrhythmias.

**PHYSICAL EXAMINATION:** Four subcutaneous, firm, mobile nodules were present on the left forearm and on the right upper, left upper, and

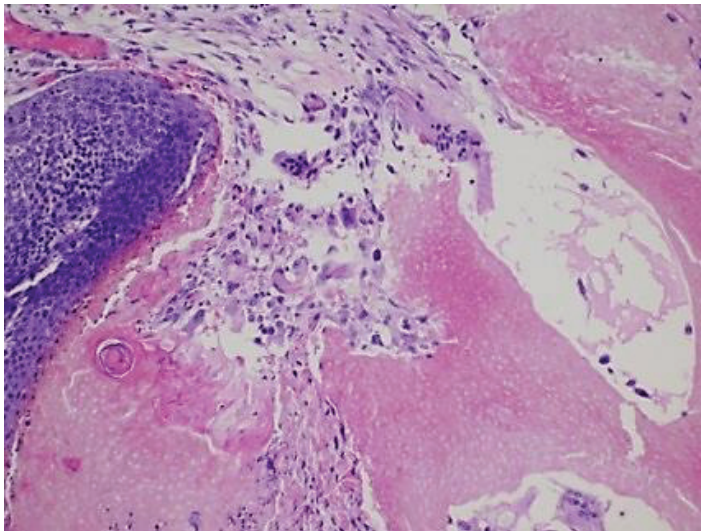


**Figure 1.** Four subcutaneous, firm, mobile nodules were present on the left forearm and on the right upper, left upper, and left mid back. The largest nodule on the right upper back measured 4-cm x 2-cm with a linear hyperpigmentation that was consistent with a scar from a prior procedure.

left mid back. The largest nodule on the right upper back measured 4-cm x 2-cm with a linear hyperpigmentation that was consistent with a scar from a prior procedure (**Figure 1**). The other three nodules had no erythema, scale, or surface changes in the overlying skin. All of the lesions, in particular the largest nodule on the right upper back, were tender to palpation. The patient also has ptosis of the eyelids and dysarthria.

**LABORATORY DATA:** None

**HISTOPATHOLOGY:** There are aggregates of shadow cells in addition to nodules of basaloid cells. There is an admixed infiltrate of histiocytes, many of which are multinucleated (**Figure 2**).



**Figure 2.** Aggregates of shadow cells in addition to nodules of basaloid cells. There is an admixed infiltrate of histiocytes, many of which are multinucleated.

**DIAGNOSIS:** Multiple pilomatricomas in the setting of myotonic dystrophy

## Discussion

Pilomatricomas, which also are known as calcifying epitheliomas of Malherbe, are benign, cutaneous tumors that arise from the hair matrix and often occur as solitary, firm, mobile tumors on the head and neck of young women [1]. Multiple pilomatricomas in one patient are a rare finding. They have been associated with many disorders, such as Turner syndrome, Gardner syndrome, sarcoidosis, and the neuromuscular disorder myotonic dystrophy [2]. Myotonic dystrophy, which

also is called Steinert Disease, is an autosomal-dominant disease with variable penetrance, and manifests as myotonia, lens opacities, mild mental retardation, frontal baldness, heart failure, and testicular atrophy. The association between myotonic dystrophy and multiple pilomatricomas was first described in 1965 [3]. Since then, there have been many reports of multiple pilomatricomas in several members of the same family, who also have myotonic dystrophy, which is similar to our patient [4-17].

The mechanism underlying the association between multiple pilomatricomas and myotonic dystrophy is unknown. Myotonic dystrophy is caused by a mutation in the dystrophin myotonia protein kinase (DMPK) gene that is located on chromosome 19. It is hypothesized that a mutation in the DMPK gene causes altered intracellular calcium levels, which play a role in cellular differentiation. In myotonic dystrophy, the mutated DMPK gene results in lower calcium levels, which causes high cell proliferation but lower terminal differentiation, and possibly leads to the shadow or ghost cells that are observed as a histopathologic feature in pilomatricomas [18]. Additionally, activating mutations in beta-catenin have been found in 75% of pilomatricomas, which may be implicated in myotonic dystrophy [19].

On histopathologic examination, pilomatricomas show sheets of epithelial cells of basophilic and eosinophilic types. Early pilomatricomas exhibit basophilic epithelial cells that cluster around the tumor periphery. As maturation occurs, these cells become more eosinophilic and lose their central nuclei and thus gain the appearance of characteristic shadow cells. Pilomatricomas also may exhibit central calcification that over time appears to resemble bony tissue [18]. The multiple pilomatricomas observed in myotonic dystrophy patients do not have distinct histopathologic features that vary from the solitary ones found in other patients.

Pilomatricomas rarely undergo malignant degeneration and are usually asymptomatic. Treatment typically is not warranted unless the lesions become symptomatic, often in the case

of large pilomatricomas that cause pain due to ulceration or inflammation in the over-stretched overlying skin. Currently, the accepted treatment for pilomatricomas is complete surgical excision with clear margins, but for patients with several skin lesions, multiple excisions may leave many scars. The risk of recurrence after complete excision ranges from 0% to 6% [20]. Spontaneous regression has not been described.

Multiple pilomatricomas are a cutaneous finding in myotonic dystrophy, especially in patients with several family members, who exhibit both of these rare disorders. This association may be particularly helpful in patients who do not yet exhibit neurologic symptoms of myotonic dystrophy, as clinicians may then carry out the appropriate screening for this neurodegenerative condition.

## References

1. Moehlenbeck FW. Pilomatricoma (calcifying epithelioma): a statistical study. *Arch Dermatol* 1973; 108: 532
2. Cecen E, et al. Pilomatricoma in children: a frequently misdiagnosed superficial tumor. *Pediatr Hematol Oncol* 2008; 25: 522
3. Cantwell AR, Reed WB. Myotonia atrophica and multiple calcifying epithelioma of Malherbe. *Acta Derm Venereol Stockh* 1965; 45: 387
4. Hassanein A, Glanz S.  $\beta$ -catenin expression in benign and malignant pilomatricomas. *Br J Dermatol* 2004; 150: 511
5. Farrier S, Morgan M. bcl-2 expression in pilomatricoma. *Am J Dermatopathol* 1997; 19: 254
6. Harper PS. Calcifying epithelioma of Malherbe: association with myotonic muscular dystrophy. *Arch Dermatol* 1972; 106: 41
7. Chiaramonti A, Gilgor RS. Pilomatricomas associated with myotonic dystrophy. *Arch Dermatol* 1978; 114: 1363
8. Graells J, et al. Multiple familial pilomatricomas associated with myotonic dystrophy. *Int J Dermatol* 1996; 35: 732
9. Aso M, et al. Pilomatricomas: association with myotonic dystrophy. *Dermatologica* 1981; 162: 197
10. Bennett K, et al. Pilomatricomas associated with myotonic dystrophy. *J Am Acad Dermatol* 1987; 16: 887
11. Salerni E, et al. Multiple pilomatricomas and myotonic dystrophy: a case report. *Riv Neurol* 1988; 58: 124
12. Street ML, Rogers RS III. Multiple pilomatricomas and myotonic dystrophy. *J Dermatol Surg Oncol* 1991; 17: 728
13. Kopeloff I, et al. Multiple pilomatricomas: report of two cases and review of the association with myotonic dystrophy. *Cutis* 1992; 50: 290
14. White GM. Multiple pilomatricomas of the scalp. *Int J Dermatol* 1992; 31: 348
15. Farrell AM, et al. Multiple pilomatricomas and myotonic dystrophy in a patient with AIDS. *Clin Exp Dermatol* 1995; 20: 423
16. Berberian BJ, et al. Multiple pilomatricomas in association with myotonic dystrophy and a family history of melanoma. *J Am Acad Dermatol* 1997; 37: 268
17. Delfino M, et al. Multiple familial pilomatricomas: a cutaneous marker for myotonic dystrophy. *Dermatologica* 1985; 170: 128
18. Cigliano B, et al. Pilomatricoma in childhood: a retrospective study from three European paediatric centres. *Eur J Pediatr* 2005; 164:673
19. Hassanein A, Glanz S. Beta-catenin expression in benign and malignant pilomatricomas. *Br J Dermatol* 2004; 150: 511
20. Danielson-Cohen A, et al. Head and neck pilomatricoma in children. *Arch Otolaryngol Head Neck Surg* 127:1481