

**Case presentation**

**Concomitant pemphigus vulgaris and pemphigoid gestationis: a case report and review of the literature**

**Dermatology Online Journal 22 (1): 6**

**Harina Vin<sup>1</sup>, Sarah J Seyfer<sup>1</sup>, Colt M McClain<sup>2</sup>, and Sylvia Hsu<sup>1</sup>**

**Baylor College of Medicine, <sup>1</sup>Department of Dermatology, <sup>2</sup>Department of Pathology**

**Correspondence:**

Harina Vin  
Baylor College of Medicine  
harina.vin@gmail.com

---

**Abstract**

Pemphigus and pemphigoid are two unique acquired immunobullous diseases with distinct clinical presentations, histological findings, and characteristic serology; they are rarely reported to coexist in the same patient. Herein we present a 29-year-old woman with a history of pemphigus vulgaris, diagnosed by histology and positive desmoglein-3 antibodies on ELISA. She presented to our clinic shortly after the delivery of her first child with tense vesicles and bullae on an erythematous base on her abdomen. Biopsy was consistent with pemphigoid gestationis and direct immunofluorescence confirmed the diagnosis. To our knowledge, there are no other reported cases of pemphigoid gestationis occurring in a patient with pemphigus vulgaris.

**Introduction**

Pemphigus vulgaris (PV) is an acquired, autoimmune blistering disease of the skin and mucous membranes occurring in men and women equally, with a mean age of onset between 50-60 years. Pemphigus vulgaris is characterized by IgG autoantibodies targeting the desmosomal proteins: desmoglein 1 and 3, which result in the loss of cellular adherence between keratinocytes. This leads to intraepidermal acantholysis and blister formation [1]. Nearly all patients with PV develop painful oral erosions, thought to be related to anti-desmoglein 3 expression and over half develop flaccid, thin-walled blisters and cutaneous erosions thought to be related to the expression of both anti-desmoglein 1 and 3 [2].

Pemphigoid gestationis (PG) is an uncommon disease of the pemphigoid family that develops in late pregnancy or the immediate post-partum period. The pathogenesis is characterized by autoantibodies targeting a transmembrane hemidesmosomal protein, BP180 (BPAG2). These complement-fixing autoantibodies were historically known as “herpes gestationis” factor or HG factor. On histology, subepidermal vesicles may be seen as well as a nonspecific mixed cellular infiltrate with eosinophils. Linear deposition of C3 along the basement membrane on direct immunofluorescence (DIF) is required for diagnosis. Pemphigoid gestationis classically begins as pruritic papules and plaques on the abdomen, which then evolve into vesicles or tense bullae on an erythematous base. The disease is typically self-limiting and treatment is supportive. There is an increased risk of prematurity and small-for-gestational age neonates and approximately 10% of newborns have transient skin lesions [3].

**Case synopsis**

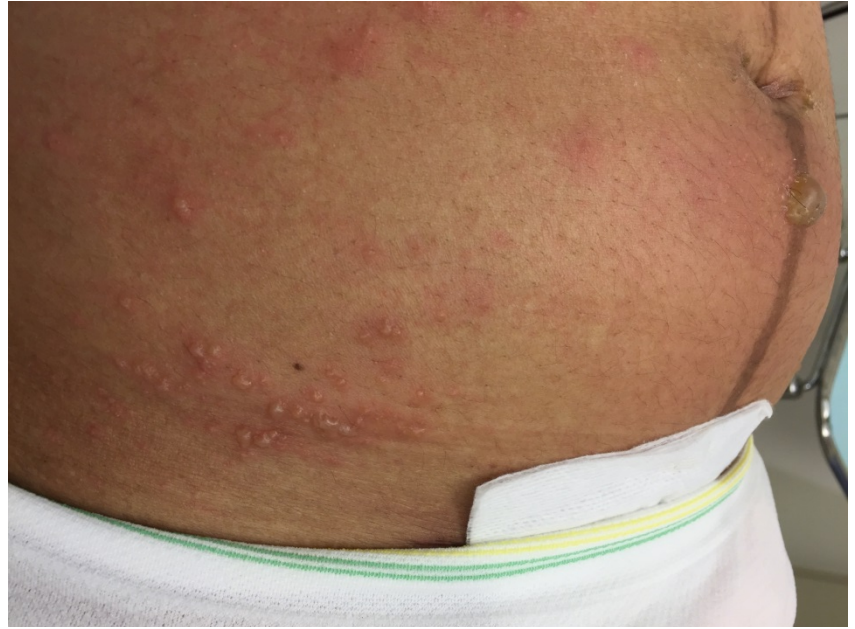A previously healthy 29-year-old woman initially presented to an oral surgeon for several months of painful oral erosions. After failing to improve with nutritional supplementation and topical steroids, a punch biopsy was performed. The biopsy was consistent with pemphigus vulgaris, showing a suprabasilar cleft with acantholysis. She was initially prescribed prednisone and

mycophenolic acid and the appearance of new lesions slowed. The mycophenolic acid was then discontinued and she took azathioprine with greater improvement in control of the pain and frequency of the lesions.

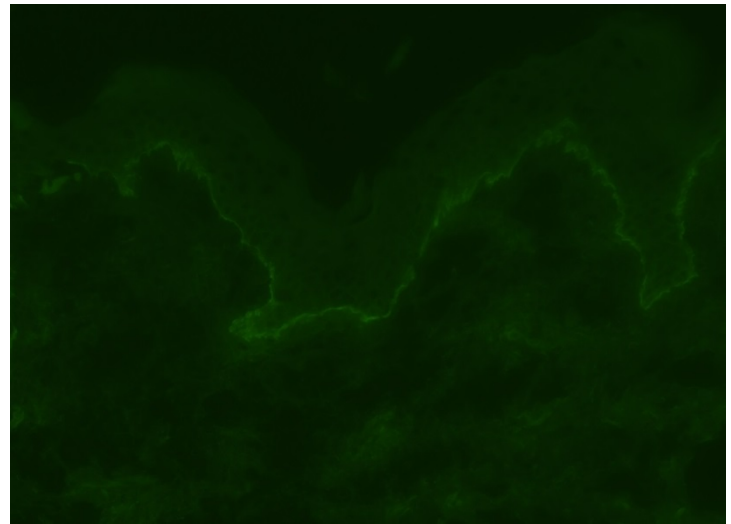
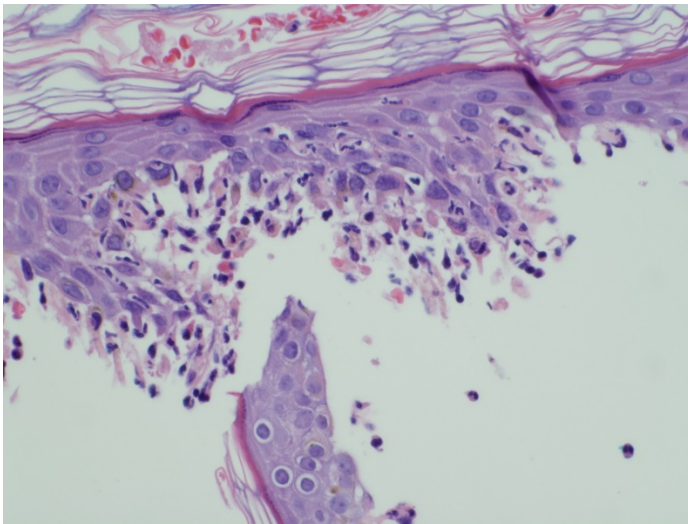
A year later, the patient presented to our institution when she was approximately 7 weeks pregnant. At that time, she had no oral or cutaneous lesions and was taking only azathioprine. She was advised to stop the azathioprine and see a high-risk obstetrician who specialized in teratogenic effects of medications. At that visit, enzyme-linked immunosorbent assay (ELISA) determined the patient's serum IgG to desmoglein 1 level to be 1 (reference range <14 = negative, 14-20=equivocal) and serum IgG to desmoglein 3 level to be 67 (reference range <9 = negative, 9-20 = equivocal).

During the rest of her pregnancy, she was off all immunosuppressive medications. She had a minor relapse of oral erosions, which were treated supportively, but she continued to have no cutaneous involvement. She underwent a C-section at 37 weeks owing to concerns of intrauterine growth restriction and the infant was born small for gestational age.

Two weeks prior to delivery she reported intense pruritus around her umbilicus, inner thighs, and hands. Initially, there were no skin lesions present, but shortly after delivery she developed blisters on her abdomen. Approximately 5 days after the initial blisters developed, she presented to us again. On exam, she had multiple tense vesicles and bullae on an erythematous base on her abdomen (Figure 1) and medial thighs. Additionally, there were several tense vesicles on her upper and lower extremities.



**Figure 1.** Tense bullae on abdomen in postpartum patient.



**Figure 2.** The biopsy showed epidermal detachment with a subepidermal inflammatory infiltrate of neutrophils and eosinophils. (40x) **Figure 3.** Direct immunofluorescence was positive for linear C3 along the dermal-epidermal junction. (20x)

A 4-mm punch biopsy was obtained of a blister on the abdomen. Histopathology showed epidermal detachment with eosinophils and neutrophils (Figure 2). Direct immunofluorescence showed linear subepidermal C3 along the dermal-epidermal junction (Figure 3). ELISA test for antibodies to bullous pemphigoid antigen (BPA) 180 was 76 (reference range: negative <9). ELISA test for antibodies to bullous pemphigoid antigen 230 was negative. These findings were compatible with gestational pemphigoid. Additionally, the patient maintained her positive anti-desmoglein IgG. ELISA test for antibodies to desmoglein 1 was 45 units (reference range <14 = negative, 14-20=equivocal) and for desmoglein 3 was 114 (reference range <9 = negative, 9-20 = equivocal).

## Discussion

We present here a unique case of a patient with pemphigus vulgaris who later went on to develop gestational pemphigoid. To our knowledge this is the first case of pemphigoid gestationis occurring in a patient with pemphigus vulgaris.

There are multiple cases reported which describe the simultaneous coexistence of histologic and immunopathologic features of both pemphigus vulgaris and bullous pemphigoid. In a review by Sami and Ahmed, there were 17 such “overlap” cases discussed. These cases were largely comprised of patients presenting with clinical features of both pemphigoid and pemphigus at the time of their diagnosis. The majority of these cases showed features of BP on histology and DIF with serology demonstrating antibodies typical of pemphigus vulgaris. Serology of 10 of these 17 patients had antibodies to both PV and BP antigens. As these cases were both clinically and histologically a mixed picture, these patients were labeled as having a “dual diagnosis” at the time of their presentation [4].

Panko et al. reported a case of a 36-year-old woman with known pemphigus vulgaris who later developed a vesicular eruption 2 weeks after delivery [5]. Histology and DIF of the vesicular lesions were consistent with PV and an ELISA confirmed both desmoglein 1 and 3 antibody positivity. Her serum was also tested for complement fixing IgG antibodies (HG factor) and this too was found to be positive, although there was no histologic evidence of basement membrane zone antibody deposition making her new lesions more consistent with her underlying PV.

Several studies have documented significant associations with specific MHC II genes in both the pemphigus and pemphigoid populations. These associations include DRB1\*0402 and DQB1\*0503 within the pemphigus population and DQB1\*0301 in the pemphigoid group. Zakka et al. postulated that there may be an immunogenetic basis for the unique group of patients with simultaneous diagnoses of PV and PG. They proposed that these patients may carry haplotypes or alleles for both PV and PG or that there may be a phenomenon known as “epitope spreading” within one allele allowing for the simultaneous production of two autoantibodies [6].

There have been several reports of pemphigus-like antibodies in patients with BP, with other connective tissue diseases, with use of thiol group containing medications, and even in healthy relatives of patients with pemphigus. As these antibodies are present in patients with no clinical evidence of pemphigus, they are considered to be nonpathogenic antibodies.

Our case prompts an interesting discussion regarding this unique population of “mixed” immunobullous patients. Are there truly cases of patients, like ours, who are unlucky enough to demonstrate histologic evidence of two independent blistering disorders in their lifetime? Is there a genetic predisposition to developing these disorders that makes having one disease a sort of ‘risk factor’ for developing another? With improvements in our diagnostic modalities for immunobullous diseases, hopefully these questions will be further elucidated in the future.

## Conclusion

Herein we present a case of pemphigoid gestationis occurring in a patient with pemphigus vulgaris; both diseases manifested independently as two distinct clinical and histologic diagnoses. Dual diagnosis of pemphigus and pemphigoid disease is exceedingly rare, and to our knowledge, this is the only reported case of pemphigus vulgaris and gestational pemphigoid occurring in the same patient.

## References

1. Beutner EH, Jordon RE. Demonstration of skin antibodies in sera of pemphigus vulgaris patients by indirect immunofluorescent staining. *Proc Soc Exp Biol Med.* 1964;117:505– 10. 4. [PMID: 14233481]
2. Amagai M, Tsunoda K, Zillikens D, et al. The clinical phenotype of pemphigus is defined by the antidesmoglein autoantibody profile. *J Am Acad Dermatol.* 1999;40:167– 70. [PMID: 10025740]
3. Lin MS, Arteaga LA, Diaz LA. Herpes gestationis. *Clin Dermatol* 2001;19:697-702. [PMID: 11705678]
4. Sami N, Ahmed AR. Dual diagnosis of pemphigus and pemphigoid. Retrospective review of thirty cases in the literature. *Dermatology* 2001;202:293-301. [PMID: 11455140]
5. Panko J1, Florell SR, Hadley J, Zone J, Leiferman K, Vanderhoof S. Neonatal pemphigus in an infant born to a mother with serologic evidence of both pemphigus vulgaris and gestational pemphigoid. *J Am Acad Dermatol.* 2009 Jun;60(6):1057-62. [PMID: 19467379]
6. Zakka LR, Keskin DB, Reche P, Ahmed AR. Relationship between target antigens and major histocompatibility complex (MHC) class II genes in producing two pathogenic antibodies simultaneously. *Clin Exp Immunol.* 2010 Nov;162(2):224-36. [PMID: 21069937]