

Successful treatment of psoriasis and lichen planus with tildrakizumab

Belén Romero-Jiménez MD, Fernando Gruber-Velasco MD, Catalina Axpe-Gil MD, María Jesús Barros-Eyzaguirre MD, Jorge Román-Sainz MD, Adrián Imbernón-Moya MD PhD

Affiliations: Department of Dermatology, Hospital Universitario Severo Ochoa, Leganés, Madrid, Spain

Corresponding Author: Belén Romero-Jiménez MD, Department of Dermatology, Hospital Universitario Severo Ochoa, Leganés, Avenida de Orellana sin número, Madrid 914818000, Spain, Email: belenromjim96@yahoo.es

Keywords: interleukin-23, lichen-planus, psoriasis, tildrakizumab

To the Editor:

We report a patient with psoriasis and lichen planus that was treated successfully with tildrakizumab, a humanized monoclonal antibody to IL23.

A 62-year-old woman with medical history of dyslipidemia and diabetes mellitus presented to our department with moderate-severe psoriasis since the age of 40. She had undergone treatment with topical corticosteroids, UVA phototherapy, and methotrexate without clinical improvement. She achieved complete resolution with adalimumab but after two years she presented with secondary failure and the new appearance of highly pruritic skin lesions on the extensor surface of the upper and lower limbs.

Dermatological examination revealed psoriasiform, erythematodesquamative plaques on her elbows, pretibial region, and dorsum of her feet with onychopathy (**Figure 1A**). In addition, she had polygonal, violaceous papules and plaques on her forearms, the distal part of her legs, and dorsum of her feet (**Figure 1B**). A skin biopsy was performed of a pretibial erythematodesquamative plaque with histological diagnosis of psoriasis. The skin biopsy of a violaceous papule on her forearm revealed histological findings of lichen planus.

Secukinumab was started, with primary failure after 9 months of treatment. At this time, she exhibited psoriasis area severity index (PASI) 9, body surface area (BSA) 5, and dermatologic life quality index (DLQI) 21. She initiated treatment with tildrakizumab

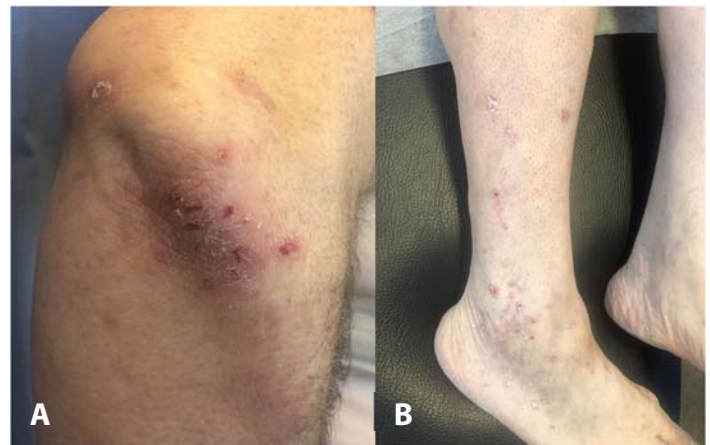


Figure 1. A) Erythematodesquamative plaques on the elbows prior to treatment with tildrakizumab. B) Violaceous polygonal papules with white streaks on the surface of the external malleolus and dorsum of the foot prior to treatment with tildrakizumab.

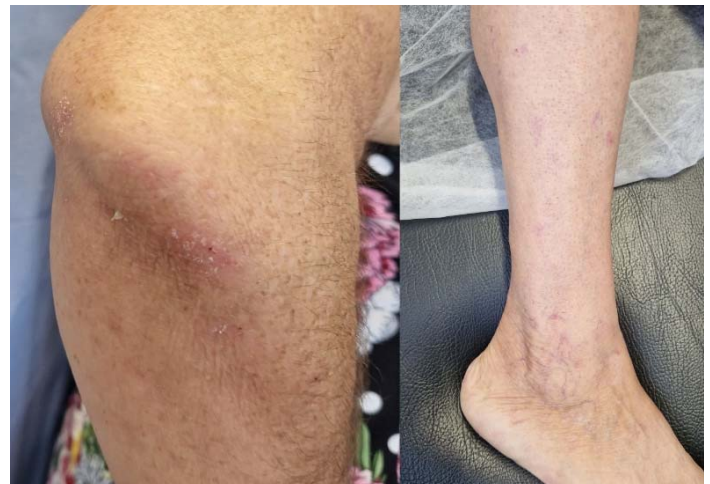

Figure 2. Resolution of lesions after 12 weeks of treatment with tildrakizumab.

100mg in weeks 0, 4, and 12. At 12 weeks of treatment she had complete resolution of the lichen and psoriasis lesions with PASI0, BSA0, and DLQI0 and improvement of the onychopathy (**Figure 2**). After one year of treatment, she continued without skin lesions and had no adverse effects.

Tildrakizumab is a humanized monoclonal antibody that inhibits the p19 subunit of IL23 that is approved for the treatment of moderate to severe psoriasis [1-3]. Although the pathogenesis of lichen planus is not exactly known, it appears that the IL23/IL17 axis plays a role as it has been observed that IL23 is overexpressed in lichen planus-affected skin and mucosal tissues compared to controls [1,2,4,5].

Some clinical cases have described the efficacy of tildrakizumab in patients with vulvovaginal lichen

planus [3,5,6], oral erosive lichen planus [2], lichen planus pemphigoid [4], lichen planus pilaris, and frontal fibrosing alopecia [1]. All these lesions were resistant to conventional treatments for these pathologies but had a satisfactory response to tildrakizumab after three months of therapy, with no adverse effects [1-5].

In conclusion, tildrakizumab can be an effective and safe alternative treatment for patients with moderate-severe psoriasis and concomitant lichen planus.

Potential conflicts of interest

The authors declare no conflicts of interest.

References

1. Trindade de Carvalho L, Meah N, Wall D, Sinclair R. Recalcitrant lichen planopilaris and frontal fibrosing alopecia responding to tildrakizumab. *Dermatol Ther*. 2020;33:e13694. [PMID: 32458516].
2. Ismail FF, Sinclair R. Clinical healing of erosive oral lichen planus with tildrakizumab implicates the interleukin-23/interleukin-17 pathway in the pathogenesis of lichen planus. *Australas J Dermatol*. 2020;61:e244-5. [PMID: 31651043].
3. Kherlopian A, Fischer G. Comparing quality of life in women with vulvovaginal lichen planus treated with topical and systemic treatments using the vulvar quality of life index. *Australas J Dermatol*. 2023;64:e125-34. [PMID: 37036241].
4. Kerkemeyer KL, Pinczewski J, Sinclair R. Successful treatment of recalcitrant lichen planus pemphigoides with tildrakizumab. *Australas J Dermatol*. 2020;61:e366-8. [PMID: 32141608].
5. Kherlopian A, Fischer G. Successful treatment of vulvovaginal lichen planus with tildrakizumab: A case series of 24 patients. *Australas J Dermatol*. 2022;63:251-5. [PMID: 35099060].
6. Kherlopian A, Fischer G. Disease remission of refractory vulvovaginal and gingival lichen planus with tildrakizumab. *Australas J Dermatol*. 2021;62:246-7. [PMID: 33742446].