

Familial multiple basaloid follicular hamartoma

A Cerejeira¹, N Gomes¹, J Pacheco², A Pedrosa^{1,3}, T Baudrier¹, F Azevedo¹

Affiliations: ¹Department of Dermatology and Venereology, Centro Hospitalar São João, EPE Porto, Portugal, ²Department of Anatomic Pathology, Centro Hospitalar São João, EPE Porto, Portugal, ³Department of Medicine, Service of Dermatology and Venereology, Faculdade de Medicina da Universidade do Porto, Porto, Portugal

Corresponding Author: André Cerejeira, Department of Dermatology and Venereology, Centro Hospitalar São João, Alameda Prof Hernâni Monteiro, 4200-319 Porto, Portugal, Tel: 351-915280289, Email: andrecerejeira@hotmail.com

Abstract

Basaloid follicular hamartoma (BFH) is a rare follicular hamartoma of benign nature, which should be part of the differential diagnoses of basal cell carcinoma. Familial multiple BFH (FMBFH) is a hereditary subtype which typically presents early in life with multiple small, skin-colored papules primarily on the central face. Although these lesions are usually asymptomatic, they can be cosmetically disfiguring. Treatment options include surgery, cryotherapy, CO₂ laser and imiquimod; no standard of care has been determined. We present a case of FMBFH presenting in adulthood, which was treated with CO₂ laser with satisfactory results.

Keywords: basal cell carcinoma, basaloid follicular hamartoma, sonic hedgehog pathway, vismodegib

Introduction

Basaloid follicular hamartoma (BFH) is an uncommon, benign, follicular hamartoma, which may be acquired or hereditary [1]. Hereditary types can be localized or generalized. Generalized forms are usually associated with systemic manifestations, which vary according to the subtype [2]. Familial multiple BFH (FMBFH) is an autosomal dominant subtype presenting early in life with numerous millimetric, skin-colored papules predominantly over the central face [3]. Associated hypotrichosis, hypohidrosis, or palmoplantar pitting might be found [4-5].

Case Synopsis

A 38-year-old woman presented with a 5-year history of multiple small, asymptomatic, follicular, skin-colored papules over the face, particularly in the peri-orbital region and the upper cutaneous lip (**Figure 1**). Medical history and physical examination were otherwise unremarkable. Her father had similar lesions but had never been biopsied or diagnosed. Remaining family history was negative. Histopathology of an upper lip lesion showed an irregular proliferation of basaloid cells in

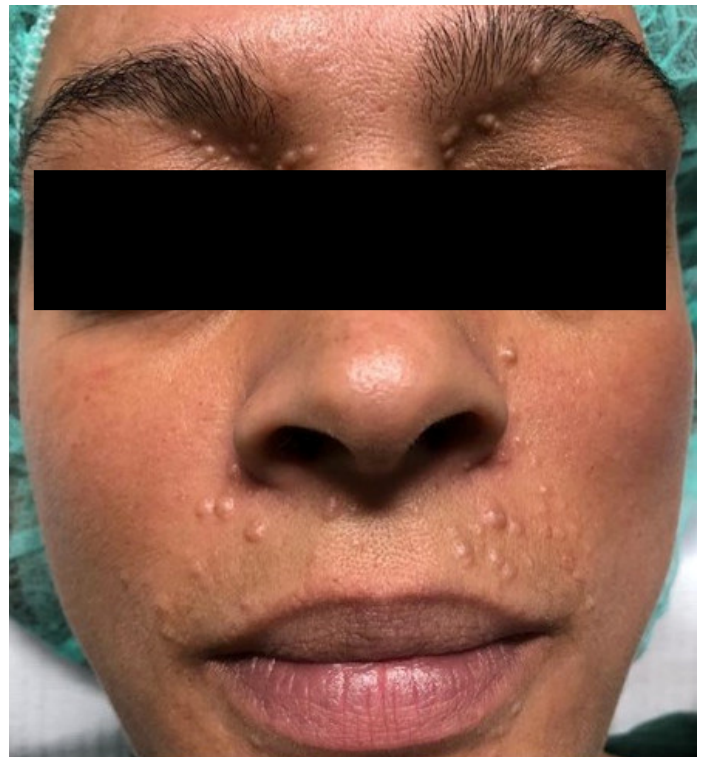


Figure 1. Multiple small, asymptomatic, follicular, skin-colored papules over the face.

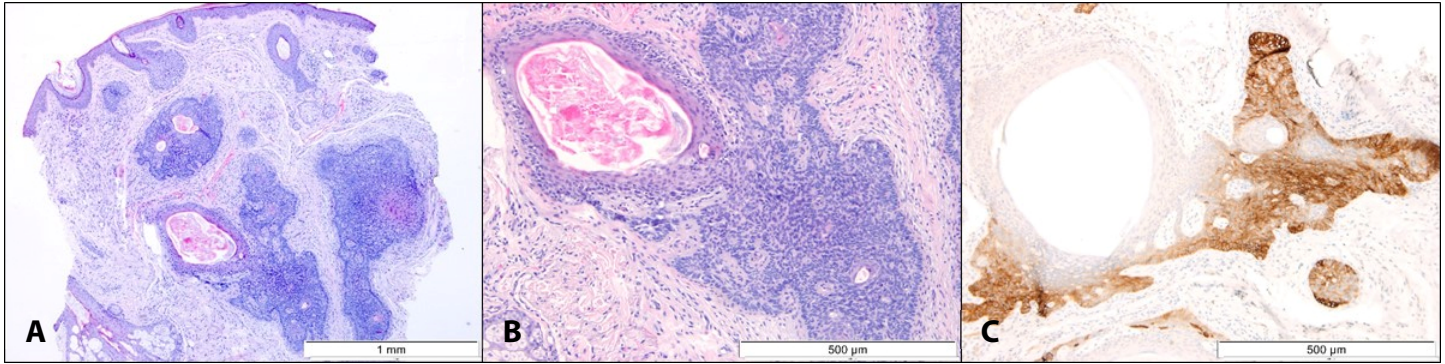


Figure 2. **A)** Biopsy of an upper lip lesion showing irregular proliferation of basaloid cells with peripheral palisading surrounding central cysts with trichilemmal keratinization. H&E, 4 \times . **B)** The basaloid cells were bland, lacking atypia. H&E, 10 \times . **C)** Immunostaining for BerEP4 was observed in the basaloid cells, 10 \times .

anastomosing strands and cords with peripheral palisading and cysts with trichilemmal keratinization (**Figure 2A, B**). Immunohistochemistry was positive for BerEP4 (**Figure 2C**). The diagnosis of BFH was made. The extensive number of lesions, positive family history, and absence of systemic manifestations supported the diagnosis of FMBFH. As the lesions were cosmetically disfiguring, the patient was treated with CO₂ laser with satisfactory results (**Figure 3**).

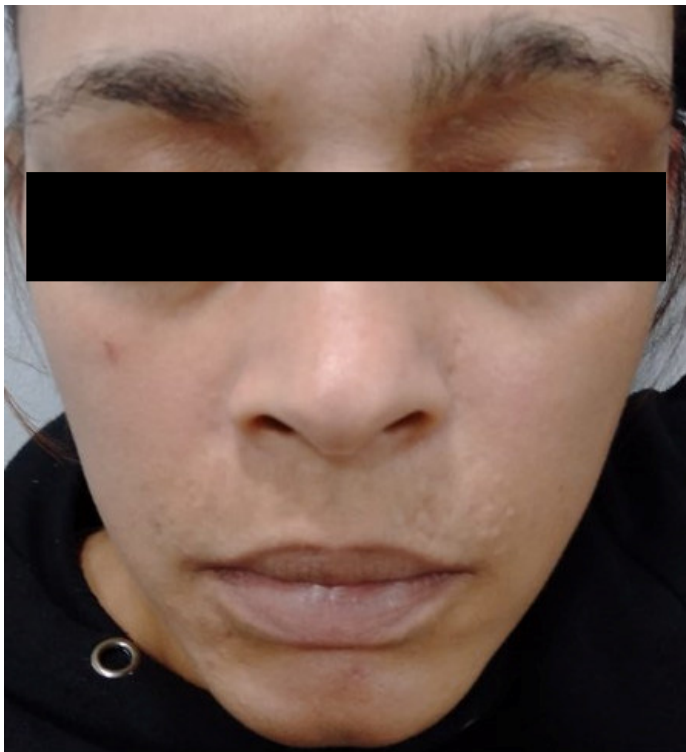

Figure 3. The patient was treated with CO₂ laser, with satisfactory results.

Case Discussion

Although FMBFH generally presents at birth or in early childhood, milder variants may be recognized later in life [6,7]. Generalized forms of BFH are usually associated with systemic manifestations, which vary according to the subtype and can include cystic fibrosis, diffuse alopecia, and various autoimmune diseases (such as myasthenia gravis or systemic lupus erythematosus), [2,8,9]. Other systemic diseases, such as hypertension, diabetes mellitus, or breast cancer, have also been reported in these patients, although it is unclear if this association exceeds that found in the general population. In FMBFH, hypotrichosis, hypohidrosis, or palmoplantar pitting may occur [10,12]. Less common and possibly unrelated cutaneous findings include atopic dermatitis, keratosis pilaris, lichen striatus, acrochordons, acanthosis nigricans-like changes, dermatosis papulosa nigra, acne vulgaris, café au lait spots, punctate palmar keratosis, and steatocystoma multiplex [13]. However, none of these manifestations were present in the patient described.

Basaloid follicular hamartoma displays an increased risk of basal cell carcinoma (BCC), [5]. Therefore, rapid changes in size or appearance should prompt biopsy. Histopathology revealing proliferation of basaloid cells in anastomosing strands and cords is a key marker in the diagnosis of BFH [14]. Ber-EP4 can be positive in both BFH and BCC. It is typically negative in tumors of follicular infundibulum [15]. In the case described, only one skin biopsy was

performed, which is a limitation. We presume that a second biopsy of the patient's lesions (and a biopsy of her father's lesions) would reveal similar findings but, ideally, additional biopsies would have been helpful to confirm the diagnosis of FMBFH.

Basaloid follicular hamartoma and infundibulocystic BCC might actually represent the same disease [4]. Apart from the clinical and histopathological similarity, both entities have positive CK20 staining [4,16]. Furthermore, dysregulation of the sonic hedgehog pathway has been implicated in the pathophysiology of both diseases [4,17]. The gene aberration in BFH is a mutation in the *patched* (*PTCH*) gene on chromosome 9q23, which is the same gene implicated in nevoid basal cell carcinoma syndrome (Gorlin–Goltz syndrome), [18]. However, the expression of the mutation in BFH is not as severe [18,19]. This gene regulates pattern development in the embryo, with mutations resulting in aberrant cell division and growth [18,19].

There are no standardized treatments for BFH [12]. Treatment options include surgery, cryotherapy, CO₂

laser, and imiquimod. Vismodegib, an inhibitor of the hedgehog signaling pathway, might play a role in the treatment of severe disease in the future [12]. The prognosis is usually excellent, unless associated systemic disorders and/or BCC develop [8,9].

Conclusion

Basaloid follicular hamartoma is a rare, benign, follicular hamartoma, which should be part of the differential diagnoses of BCC. Its diagnosis requires clinicopathological correlation. Despite its benign and stable nature, patients with BFH often pursue treatment for cosmetic reasons. No standard of care has been determined, but CO₂ laser can achieve good results. This disease is associated with a good prognosis, but patients with BFH should be monitored given the increased risk of BCC.

Potential conflicts of interest

The authors declare no conflicts of interest.

References

1. Brownstein MH. Basaloid follicular hamartoma: solitary and multiple types. *J Am Acad Dermatol.* 1992;27:237-40. [PMID: 1430363].
2. Jih DM, Shapiro M, James WD, Levin M, et al. Familial basaloid follicular hamartoma: lesional characterization and review of the literature. *Am J Dermatopathol.* 2003;25:130-7. [PMID: 12652194].
3. Wheeler CE Jr, Carroll MA, Groben PA, et al. Autosomal dominantly inherited generalized basaloid follicular hamartoma syndrome: report of a new disease in a North Carolina family. *J Am Acad Dermatol.* 2000; 43(Part 1):189-206. [PMID: 10906638].
4. Huang SH, Hsiao TF, Lee CC. Basaloid follicular hamartoma: a case report and review of the literature. *Kaohsiung J Med Sci.* 2012;28:57-60. [PMID: 22226063].
5. Yoshida Y, Urabe K, Mashino T, Duan H, Kiryu H, Masuda T, Koga T, Furue M. Basal cell carcinomas in association with basaloid follicular hamartoma. *Dermatology.* 2003;207:57-60. [PMID: 12835551].
6. Verkouteren BJA, Mosterd K. Treatment of basal cell carcinomas and basaloid follicular hamartomas in basal cell nevus syndrome children and adolescents. *J Dermatolog Treat.* 2020;1:1-2. [PMID: 33081541].
7. Jedrzynski N, Plum W, et al. Basaloid follicular hamartoma of the eyelid in a pediatric patient. *Am J Ophthalmol Case Rep.* 2020;19:100855. [PMID: 32803019].
8. Flordelis JO, Shen YC, Wu YH. Basaloid tumors arising from seborrheic keratosis: malignant basal cell carcinoma or benign basaloid follicular hamartomatous proliferation? *J Cutan Pathol.* 2020;47:207-218. [PMID: 31682281].
9. Muhammed N, Dongre AM, Khopkar US. Clinicopathological and dermoscopic features in a case of linear and unilateral basaloid follicular hamartoma. *Indian Dermatol Online J.* 2019;10:710-713. [PMID: 31807455].
10. Adya KA, Inamadhar AC, Palit A, Janagond AB. Dermoscopy of linear basaloid follicular hamartoma. *Indian Dermatol Online J.* 2019;10:610-612. [PMID: 31544094].
11. Shevchenko A, Durkin JR, Moon AT. Generalized basaloid follicular hamartoma syndrome versus Gorlin syndrome: a diagnostic challenge. *Pediatr Dermatol.* 2018;35:e396-e397. [PMID: 30152544].
12. Segars K, Cooper H, et al. Basaloid follicular hamartoma: a case report and a novel cosmetic treatment. *J Clin Aesthet Dermatol.* 2018;11:39-41. [PMID: 29607000].
13. Gumaste P, Ortiz AE, Patel A, Baron J, Harris R, Barr R. Generalized basaloid follicular hamartoma syndrome: a case report and review of the literature. *Am J Dermatopathol.* 2015;37:e37-40. [PMID: 24698936].
14. Stanoszek LM, Wang GY, Harms PW. Histologic mimics of basal cell carcinoma. *Arch Pathol Lab Med.* 2017;141:1490-1502. [PMID: 29072946].
15. Alomari A, Subtil A, Owen CE, McNiff JM. Solitary and multiple tumors of follicular infundibulum: a review of 168 cases with emphasis on staining patterns and clinical variants. *J Cutan Pathol.* 2013;40:532-7. [PMID: 23531053].
16. Honarpisheh H, Glusac EJ, Ko CJ. Cytokeratin 20 expression in basaloid follicular hamartoma and infundibulocystic basal cell carcinoma. *J Cutan Pathol.* 2014;41:916-21. [PMID: 25353070].

17. Choi E, Liao M, Huang J, Tan KB, Aw D. Basaloid follicular hamartoma: clinical, dermoscopic, and histopathological characteristics of case. *Dermatol Online J.* 2017;23(5). [PMID: 28537867].
18. Ponti G, Manfredini M, Pastorino L, Maccaferri M, Tomasi A, Pellacani G. PTCH1 germline mutations and the Basaloid Follicular Hamartoma values in the tumor spectrum of Basal Cell Carcinoma Syndrome (NBCCS). *Anticancer Res.* 2018;38:471-476. [PMID: 29277811].
19. Shevchenko A, Durkin JR, Moon AT. Generalized basaloid follicular hamartoma syndrome versus Gorlin syndrome: A diagnostic challenge. *Pediatr Dermatol.* 2018;35:e396-e397. [PMID: 30152544].