

UC Davis

Dermatology Online Journal

Title

Pediatric cutaneous mucormycosis

Permalink

<https://escholarship.org/uc/item/2fn9d2tr>

Journal

Dermatology Online Journal, 29(6)

Authors

Matei, Mariana Claudia

Ramirez, Sandra Castejon

Sanz, Sara Sanz

et al.

Publication Date

2023

DOI

10.5070/D329662994

Copyright Information

Copyright 2023 by the author(s). This work is made available under the terms of a Creative Commons Attribution-NonCommercial-NoDerivatives License, available at

<https://creativecommons.org/licenses/by-nc-nd/4.0/>

Peer reviewed

# Pediatric cutaneous mucormycosis

Mariana Claudia Matei<sup>1</sup> MD, Sandra Castejón Ramírez<sup>2</sup> MD, Sara Sanz Sanz<sup>3</sup> MD, Tamara Gracia Cazaña<sup>1</sup> MD, Concepción López Gómez<sup>3</sup> MD, Neus Martínez Arnau<sup>4</sup> MD, Matilde Bustillo Alonso<sup>2</sup> MD, Isabel Bernad Alonso<sup>1</sup> MD

Affiliations: <sup>1</sup>Department of Dermatology, Hospital Miguel Servet, Zaragoza, Spain, <sup>2</sup>Department of Pediatrics, Hospital Miguel Servet, Zaragoza, Spain, <sup>3</sup>Department of Microbiology, Hospital Miguel Servet, Zaragoza, Spain, <sup>4</sup>Department of Anatomic Pathology, Hospital Miguel Servet, Zaragoza, Spain

Corresponding Author: Mariana Claudia Matei MD, Department of Dermatology, Hospital Miguel Servet, Street Isabel la Católica, 1-3, 50009, Zaragoza, Spain, Tel: 34-671256996, Email: [marimatei.96@gmail.com](mailto:marimatei.96@gmail.com)

## Abstract

A 9-year-old boy diagnosed with acute myeloblastic leukemia and undergoing chemotherapy, was admitted with febrile neutropenia. During his admission, several violaceous plaques appeared on the upper extremities and anterior left hemithorax, which worsened and acquired a necrotic center. We performed a biopsy and histology showed a cutaneous infarction at the dermoepidermal and subcutaneous level. We observed abundant wide hyphae with right-angled branching and a culture isolated *Rhizopus oryzae*. A plastic surgery consultant performed a surgical debridement of the lesions and treatment was started with intravenous amphotericin B. The patient did well on treatment and after almost a month of hospitalization, he was discharged with oral posaconazole. Mucormycosis is an opportunistic fungal infection associated with immunosuppression, particularly involving prematurity and hematological diseases in the pediatric age group. Multiple lesions, as in our case, are infrequent. The clinical presentation is variable. Direct smear or histological observation is the quickest diagnostic technique whereas culture is the most definitive. The combination of surgical debridement and amphotericin B is the treatment with the highest survival rates.

**Keywords:** amphotericin B, mucormycosis, necrotic plaques, *Rhizopus oryzae*

## Introduction

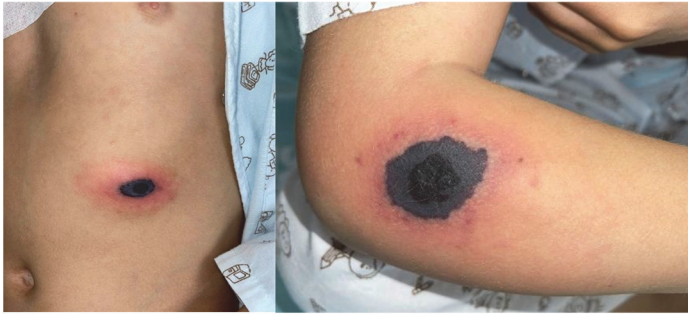Mucormycosis is the third most frequent cause of invasive fungal infection after candidiasis and

aspergillosis [1]. Most cases are associated with decompensated diabetes mellitus and severe or prolonged neutropenia. The most common form of presentation in both children and adults is rhinocerebral mucormycosis, followed by pulmonary, intestinal, cutaneous, and disseminated forms [1-3]. Secondary cutaneous manifestations are frequent. On the contrary, primary cutaneous manifestations are unusual, especially in multiple form [1].

## Case Synopsis

A 9-year-old boy diagnosed with acute myeloblastic leukemia, a history of pulmonary aspergillosis under prophylactic treatment with voriconazole, and persistent SARS-CoV-2 infection was admitted to the infectious disease unit of the pediatrics department presenting with febrile neutropenia. Three days after admission, several skin lesions appeared, two on the upper extremities and one on the anterior part of the left hemithorax. Physical examination revealed erythematous-violaceous plaques with necrotic center and perilesional erythema. Induration on palpation extended beyond what was apparently visible, with the largest measuring 3.5cm×2cm in size in the regions described above (**Figure 1**).

Initially, within the clinical context and in the absence of other symptoms, ecthyma gangrenosum was suspected, so treatment with cefepime was initiated. However, persistent fever and progressive increase of inflammatory biomarkers was observed. Blood culture isolated *Capnocytophaga sputigena*, a gram-negative bacillus constituent of the oral

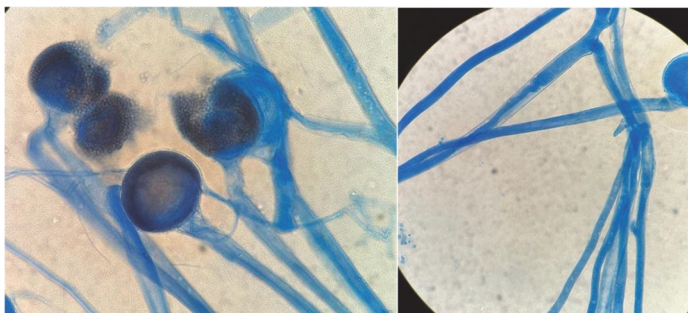


**Figure 1.** Violaceous plaques with necrotic center and perilesional erythema on the left hemithorax and right arm.

microbiota. Treatment was modified and piperacillin-tazobactam was administered, also without improvement of the skin lesions or remission of the fever. Finally, owing to the lack of clinical and analytical response to intravenous antibiotics, meropenem 120mg/kg/day in extended perfusion and liposomal amphotericin B, 5mg/kg/day was started as antifungal therapy, complementary to the voriconazole with which the patient was already being treated at the time of admission. In addition, treatment with lenograstim (granulocyte colony-stimulating factor) was added at a dose of 150µg every 24 hours.

Two 6mm punch biopsies of the right arm were performed for pathology evaluation and tissue cultures for organisms. Direct visualization with calcofluorine white stain showed abundant wide, branched hyphae at right angles, not septate, compatible with fungi of the genus *Mucor* (**Figure 2**).

Among the imaging tests, imaging was performed by means of a cranial and paranasal sinus CT and a thoraco-abdominal CT, without observing visceral involvement and, in addition, a soft tissue MRI ruled out the involvement of deep planes, confirming the



**Figure 2.** Lactophenol blue staining. Sporangia containing infective spores and sporangiophores are observed.

diagnosis of a primary cutaneous mucormycosis. It was decided to increase the dose of liposomal amphotericin B to 7mg/kg/day and to add intravenous posaconazole 300mg/12hours due to the impossibility of swallowing the tablets. Surgical debridement of all lesions was performed.

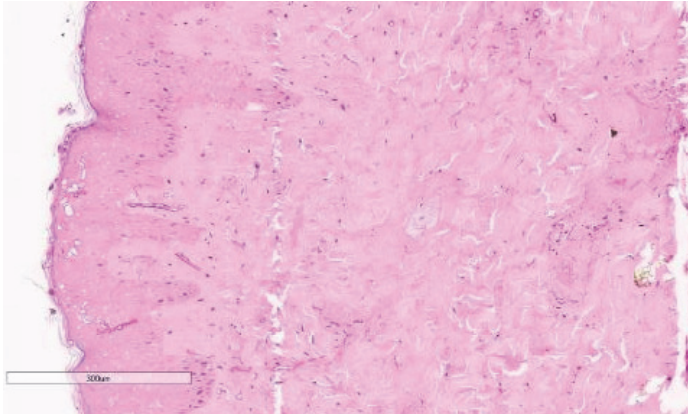
In the histopathological study, a cutaneous infarction was observed at dermoepidermal and subcutaneous level as a consequence of angioinvasive fungi (**Figure 3**). Culture identified the pathogen as *Rhizopus oryzae* by mass spectrometry technique (MALDI-TOF). An antifungal sensitivity study was performed using two different techniques: Sensititre YeastOne panel (Thermo Fisher Scientific) and E-test (BioMérieux), which showed good correlation with each other. The organism was sensitive based on the epidemiological cut-off point to amphotericin B (MIC: 0.5µg/mL), posaconazole (MIC: 0.5µg/mL), and isavuconazole (MIC: 1µg/mL) and resistant to voriconazole (MIC: ≥8 µg/mL).

The patient had a favorable response to treatment, although he suffered severe hypokalemia as a consequence of amphotericin B treatment that resolved with potassium supplementation. Finally, liposomal amphotericin B was discontinued after 21 days of treatment and intravenous posaconazole was maintained. The patient was discharged after one month of hospitalization with oral posaconazole at a dose adjusted by blood levels of 300mg/day and remained free of lesions six months later.

## Case Discussion

Primary cutaneous mucormycosis is an opportunistic fungal infection associated with immunosuppression, especially prematurity and hematological diseases in children [2]. COVID-19 infection is another risk factor, and an increase in the incidence of mucormycosis has been observed during the pandemic. However, the rhino-orbito-cerebral form has been the most frequently associated, with cutaneous involvement being rarely reported [1,6].

It is generally acquired by contiguous spread as a consequence of trauma [1,2]. However, some cases have been initiated by direct contact with



**Figure 3.** H&E histopathology of biopsy from the right arm. Necrosis of the entire dermoepidermal thickness together with numerous fungal hyphae and spores, 8x.

contaminated in-hospital material such as bandages, patches, catheters, and tongue depressors [1,4,5]. Our patient did not remember any type of trauma in the affected regions. He had reported intense pruritus since the last chemotherapy cycle and had numerous excoriations on the arms, legs, and trunk. Therefore, a possible explanation could be autoinoculation by scratching. The lesions are usually single, most frequently located on the upper and lower extremities [1]. Cases with multifocal involvement have rarely been described and have been related, above all, to major trauma such as traffic accidents or natural disasters [4,7,8]. This case is unusual not only because it represents primary cutaneous mucormycosis, but because it shows multifocal involvement without obvious trauma. The clinical presentation can be highly variable, most commonly initial lesions progress to a necrotic eschar [1]. It is necessary to have a high degree of suspicion, especially when dealing with patients with any risk factor or with interruption of the cutaneous barrier [1].

Diagnosis is complex and, given the need for a rapid response, direct smear observation of the hyphae with calcofluor white stain is very useful, allowing the implementation of early targeted therapy [9,10]. Definitive diagnosis is made by culture, although isolation of mucormycosis is positive in only 15-25% of cases [11]. Identification by mass spectrometry (MALDI-TOF) is an important factor in the speed of definitive diagnosis [12]. On the other hand, in the histological study, it is also possible to see the hyphae and spores as elongated eosinophilic or

rounded structures, respectively. In addition, being angioinvasive, it is characteristic to observe extensive cutaneous necrosis, due to their facility to invade and cause thrombosis of vessel [13].

Regarding treatment, the highest survival rates have been obtained with the combined use of surgical debridement and amphotericin B [1-8,13-15]. According to the meta-analysis performed by Jeong et al. [15], it seems that amphotericin B continues to be the most widely used antifungal drug over new treatments available such as posaconazole or isavuconazole, perhaps because of the greater variability of their plasma levels, which need frequent monitoring, and the narrower antifungal spectrum. Furthermore, in the case of pediatric patients, the existing formulations make administration difficult, since the oral suspension is less bioavailable, requiring a greater number of intakes per day and the gastroresistant capsules are often difficult to swallow due to their size. Nevertheless, a great advantage of these over amphotericin B is that they do not cause renal toxicity and can be used in patients with moderate or severe renal insufficiency [16].

On the other hand, in the same review, the authors found no statistically significant differences between the use of various antifungals and amphotericin B in monotherapy in terms of survival. To date, the most recommended dose of amphotericin B has not been established, although it seems that doses higher than 10mg/kg/day do not confer greater efficacy but a greater number of adverse effects. The duration of treatment has not been established either, with the average, in the cases of greater survival, being 30 days [15].

Finally, it should not be forgotten that most cases occur in immunosuppressed patients, so immune restitution is also important [7], and therefore, our patient was treated with granulocyte colony growth factors for one week until the desired blood neutrophil level was reached.

## Conclusion

In conclusion, mucormycosis is an acute infection that can be fatal. Although the primary cutaneous



form has a better prognosis than other forms of mucormycosis, prompt recognition and treatment are critical to prevent the spread of the fungus and increase patient survival. Further studies are needed

to elucidate the best treatment regimen and the role of newly available treatments.

### Potential conflicts of interest

The authors declare no conflicts of interest.

### References

1. Skiada A, Drogari-Apiranthitou M, Pavleas I, Daikou E, Petrikos G. Global cutaneous mucormycosis: A systematic review. *J Fungi (Basel)*. 2022;16;8:194. [PMID: 35205948].
2. Ziaka M, Papakonstantinou E, Vasileiou E, et al. Paediatric cutaneous mucormycosis: A case report and review of the literature. *Mycoses*. 2022;65:674-682. [PMID: 35514044].
3. Valdés TGE, Martínez BME, Morayta RCARR. Mucormicosis rinoorbitaria en niños con inmunosupresión. Serie de tres casos y revisión de la literatura. *Rev Latin Infect Pediatr*. 2020;33:49-56. [DOI:10.35366/92386].
4. Page AV, Evans AJ, Snell L, Liles WC. Primary cutaneous mucormycosis in a lung transplant recipient: case report and concise review of the literature. *Transpl Infect Dis*. 2008;10:419-25. [PMID: 18627579].
5. Lewis RE, Kontoyiannis DP. Epidemiology and treatment of mucormycosis. *Future Microbiol*. 2013;8:1163-75. [PMID: 24020743].
6. Joshi S, Telang R, Tambe M, et al. Outbreak of mucormycosis in coronavirus disease patients, Pune, India. *Emerg Infect Dis*. 2022;28:1-8. [PMID: 34586055].
7. Bonifaz A, Tirado-Sánchez A, Hernández-Medel ML, et al. Mucormycosis with cutaneous involvement. A retrospective study of 115 cases at a tertiary care hospital in Mexico. *Australas J Dermatol*. 2021;62:162-167. [PMID: 33222179].
8. Andresen D, Donaldson A, Choo L, et al. Multifocal cutaneous mucormycosis complicating polymicrobial wound infections in a tsunami survivor from Sri Lanka. *Lancet*. 2005;5-11;365(9462):876-8. [PMID: 15752532].
9. Ramos L, Mellado S, Ramadán S, Bulacio L, López C. Empleo de blanco de calcoflúor para el estudio de las especies de *Malassezia* por microscopía directa. *Revista Argentina de Microbiología*. <https://www.redalyc.org/articulo.oa?id=213016797002>.
10. Antonov NK, Tang R, Grossman ME. Utility of touch preparation for rapid diagnosis of cutaneous mucormycosis. *JAAD Case Rep*. 2015;1:175-177. [PMID: 27051722].
11. Lass-Flörl C. Zygomycosis: conventional laboratory diagnosis. *Clin Microbiol Infect*. 2009;15 Suppl 5:60-5. [PMID: 19754760].
12. Fuentes Marín MD, López Gómez M, Miguel Molinos AC, et al. Espectrometría de masas MALDI-TOF en el diagnóstico microbiológico. In: *Revista Sanitaria de Investigación*. Vol 2. Nº 7. 2021.
13. Quiroz N, Villanueva J del P, Lozano E A. Mucormicosis. In: *Revista de la Asociación Colombiana de Dermatología y Cirugía Dermatológica*. 2019, 25, 284-293. [DOI: 10.29176/2590843X.302].
14. Roden MM, Zaoutis TE, Buchanan WL, et al. Epidemiology and outcome of zygomycosis: a review of 929 reported cases. *Clin Infect Dis*. 2005;1;41:634-53. [PMID: 16080086].
15. Jeong W, Keighley C, Wolfe R, et al. Contemporary management and clinical outcomes of mucormycosis: A systematic review and meta-analysis of case reports. *Int J Antimicrob Agents*. 2019;53:589-597. [PMID: 30639526].
16. Terap IDEP, Espa S, Infecciosas E, et al. Informe de posicionamiento terapéutico de isavuconazol en el tratamiento de la aspergilosis invasora y la mucormicosis. 2016;1-5. <https://www.aemps.gob.es/medicamentosUsoHumano/informePublicos/docs/IPT-isavuconazol-Cresemba-aspergilosis-mucormicosis.pdf>. Accessed on July 7, 2023.