

Sneddon-Wilkinson disease following COVID-19 vaccination

Tatiana McCoy¹ BS, Dalia Shamsian² PA-C, Adrienne Pan^{2,3,5} BS, Raja K Sivamani²⁻⁶ MD MS AP

Affiliations: ¹School of Medicine, University of California Davis, Sacramento, California, USA, ²Pacific Skin Institute, Sacramento, California, USA, ³Department of Dermatology, University of California-Davis, Sacramento, California, USA, ⁴Department of Biological Sciences, California State University, Sacramento, California, USA, ⁵College of Medicine, California Northstate University, Sacramento, California, USA, ⁶Integrative Skin Science and Research, Sacramento, California, USA

Corresponding Author: Raja Sivamani MD MS AP, Pacific Skin Institute, 1495 River Park Drive, Suite 200, Sacramento, CA 95815, Email: raja.sivamani.md@gmail.com

Abstract

Sneddon-Wilkinson disease, also known as subcorneal pustular dermatosis (SPD), is a rare disease characterized by vesicles or pustules that may rapidly expand and coalesce. Idiopathic in nature, SPD's clinical presentation of "half-half" blisters, with half of each blister containing pus and half containing clear fluid, is characteristic of this disease. We describe a previously healthy 21-year-old man who developed acute pustular vesicular eruptions consistent with SPD eight days following the Moderna COVID-19 vaccination.

Keywords: COVID-19, Moderna vaccine, pustular dermatosis, Sneddon-Wilkinson, subcorneal

Introduction

Sneddon-Wilkinson disease or subcorneal pustular dermatosis (SPD), is characterized by sterile pustular eruptions. The exact pathogenic mechanism of SPD is unknown [1]. This condition more commonly impacts middle-aged women [2]. This rare neutrophilic dermatosis begins with an eruption of pustules that are pea-sized in nature. We describe a 21-year-old man with no prior history of SPD who developed erythematous and vesicular lesions consistent with SPD 8 days following his second dose of the Moderna COVID-19 vaccine.

Case Synopsis

A 21-year-old man with no significant past medical history presented with a chief complaint of a rash on

the trunk and extremities. He described a two-week history of severe, progressive pustular skin eruptions on his chest, back, bilateral upper and lower extremities, and bilateral hips and buttocks. The lesions began as blisters and areas of dry skin eight days following his second dose of the Moderna COVID-19 vaccination. The patient noted arthralgia and myalgia but denied fevers after receiving the vaccination.

The rash worsened following the application of an over-the-counter lotion for pruritus. Prior treatment included clotrimazole-betamethasone cream once daily, which was effective in alleviating pruritus but not his lesions. Additionally, he was given oral prednisone 50mg daily for 4-5 days, which improved both pruritus and his skin lesions. On examination, the patient had a flaccid vesiculopustular eruption of the left axilla (**Figure 1A**) and large superficial crusted serpiginous plaques on the left chest (**Figure 1B**). Physical examination was also notable for multiple, superficial, erythema-based, crusted papules coalescing into plaques on the dorsal hands, bilateral arms, axillae, bilateral legs, and groin (**Figure 1C**).

A 6mm punch biopsy was performed on the left lateral chest. In addition, thyroid stimulating hormone (TSH), complete blood count (CBC), complete metabolic panel (CMP), glucose-6-phosphate dehydrogenase (G6PD), and a bacterial culture of the left axilla was obtained. G6PD, TSH, and CMP were unremarkable; however, the CBC was abnormal with leukocytosis (monocytes, 1154 cells/ μ l; normal range 200.00-950.00 cells/ μ l). Histopathological evaluation of the 6mm punch

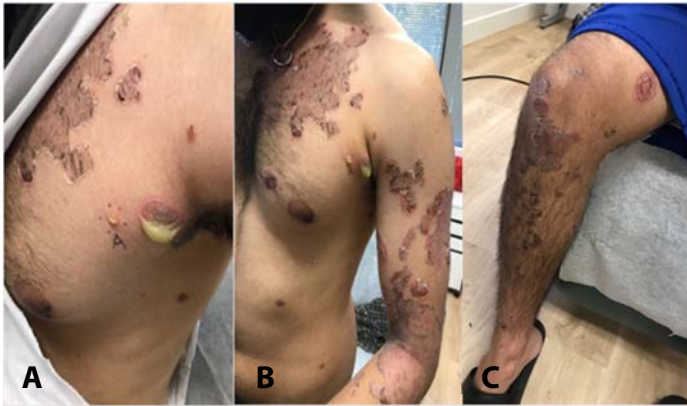

Figure 1. **A)** Flaccid vesiculopustular on the left axilla. **B)** Large superficial crusted serpiginous plaques on the left chest. **C)** Multiple superficial crusted papules coalescing into a plaque on an erythematous base on the right leg.

biopsy revealed subcorneal pustules accompanied by mild spongiosis and a concomitant mixed neutrophilic and lymphocytic infiltrate, most consistent with the clinical impression of Sneddon-Wilkinson disease (**Figure 2**). There were no features to suggest an underlying autoimmune vesiculobullous disorder such as pemphigus.

Bacterial cultures and stains were positive for methicillin-resistant *Staphylococcus aureus* (MRSA). The patient was instructed to continue prednisone 50mg daily and apply triamcinolone acetonide 0.1% ointment twice daily to areas with persistent scaling or itching. The patient experienced significant improvement after two weeks, showing only post-inflammatory hyperpigmentation and residual crust on the right upper arms and right chest, so prednisone was discontinued. The patient continued to apply triamcinolone acetonide 0.1% ointment to any areas with persistent scaling and itching and he

was instructed to follow up as needed for symptom reoccurrence.

Case Discussion

Subcorneal pustular dermatosis is a neutrophilic dermatoses condition marked by an inflammatory infiltrate composed of polymorphonuclear leukocytes [2]. A key defining feature of SPD is pustules composed of both serous fluid and purulence. Patients can present with a history of relapsing symmetrical pustular lesions encompassing intertriginous areas, the trunk, and flexor sites [3]. Rupture of the pustules causes subsequent superficial scaling, potentially followed by hyperpigmentation, scarring, or new crops of pustules [4]. A unique feature is the subcorneal accumulation of neutrophils, indicating the presence of chemoattractants in the stratum corneum [1].

Dapsone is the first line of therapy for the treatment of SPD, though sulfapyridine and sulfamethoxypyridazine can be used as alternative options. Systemic corticosteroids can also be utilized. Prednisone dosages range from 50 to 100mg/day and can be used as a monotherapy but tend to be inferior to dapsone. Typically, dapsone dosages range from 50 to 200mg/day [2]. Retinoids, narrowband ultraviolet B (UVB), broadband UVB, psoralen+UVA (PUVA), and re-PUVA have all been reported as being effective methods for treatment [4]. Although the management of SPD is better understood than the pathological mechanism, significant research is needed to fully explain the etiology. The differential diagnosis of SPD includes

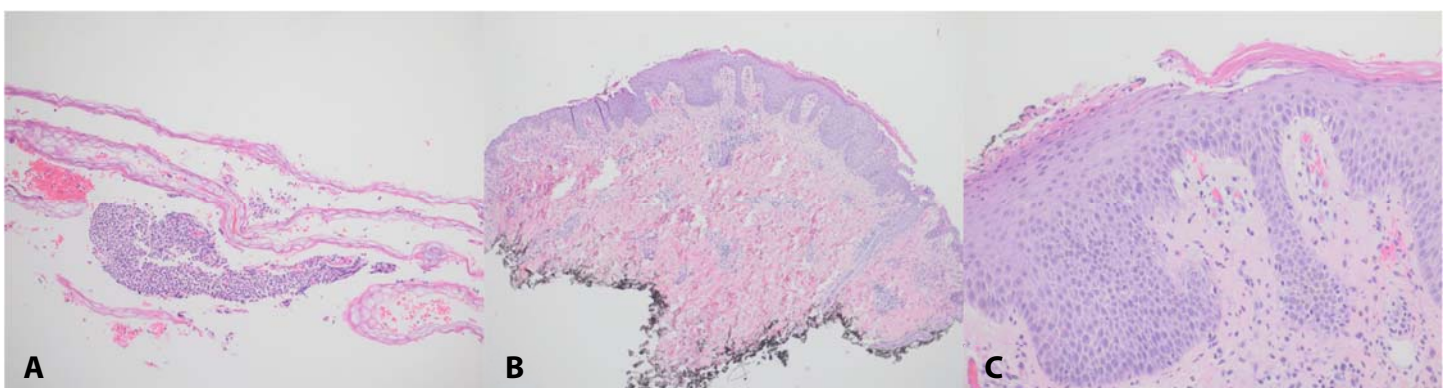


Figure 2. H&E staining for subcorneal pustular dermatosis showing subcorneal pustules and mild spongiosis with perivascular infiltrate. **A)** 4x, **B)** 10x and **C)** 20x.

pustular psoriasis, IgA pemphigus, pemphigus foliaceus, dermatitis herpetiformis, impetigo, and acute generalized exanthematous pustulosis. However, unlike the other diagnoses, SPD presents with the striking appearance of “half-half” blisters [6]. The histopathology of SPD does not show pathognomonic findings; however, it does illustrate subcorneal pustules and dermal infiltrate containing mainly neutrophils with few eosinophils, little or no spongiosis, and rarely acantholysis (**Figure 2**).

The discovery of an etiological pathogen for SPD has not been made. Subcorneal pustular dermatosis can be associated with cancer, medication, systemic disease, and infections. Subcorneal pustular dermatosis is often reported in association with various forms of immune dysfunction, such as IgA or IgG monoclonal gammopathy and multiple myeloma [1]. At this time, an association between SPD, viral infections, and COVID-19 vaccinations have not been made. Other studies have reported dermatosis associated with other vaccinations [7,8]. There are a number of reports on the onset of acute annular pustular psoriasis with the COVID-19 vaccine as well the development of pustular psoriasis in a patient with established plaque psoriasis following the administration of the vaccine. There are of course significant clinical and light microscopic similarities between acute pustular psoriasis and Sneddon-Wilkinson disease suggesting potentially pathophysiologic commonality at least in some cases. It has been suggested that certain cutaneous COVID-19 vaccine reactions may represent unmasking of subclinical inflammatory dermatoses due to the immune boosting properties of the vaccine. This, as well the encoded spike glycoprotein elicits a highly effective adaptive T cell response especially given the superantigen properties of the spike glycoprotein [9]. This effective T cell response might encompass those T cells that generate a proinflammatory cytokine milieu and offers another explanation for some of the unusual inflammatory lesions seen following the vaccine. Others have also

shown that the cutaneous vaccine reactions are more commonly seen following the second dose of the vaccine [9]. The Moderna vaccine phase three randomized control trial (RCT) reported an efficacy of 94.1%, noting no serious side effects [10]. Systemic side effects including fatigue, fever, and headache were more common amongst the vaccine recipients between the ages of 16 and 55 years of age [10].

The mRNA COVID-19 vaccine (mRNA-1273) was issued an Emergency Use Authorization to protect against severe acute respiratory syndrome coronavirus two (SARS-CoV-2) and rapid development of this efficacious vaccine resulted in scarce knowledge of long-term side effects [11]. A better understanding of potential long-term consequences can help to potentially address voids in the pathogenic mechanism of SPD. This occurrence of SPD should also not discourage the administration of COVID-19 vaccinations but should prompt further investigation into these associations.

Conclusion

Our case highlights the rare occurrence of subcorneal pustular dermatosis in a previously healthy 21-year-old man following the COVID-19 vaccination. Subcorneal pustular dermatosis is a rare condition with an unknown ideology. Our case was unique in the fact that the lesions presented following a novel COVID-19 vaccination. This association may have significance in determining the pathophysiology of subcorneal pustular dermatosis.

Potential conflicts of interest

Raja Sivamani is a scientific advisor for LearnHealth, Arbonne, and Codex Labs and a Consultant/Honoraria for Burt's Bees, Novozymes, Biogena, Bristol Myers Squibb, Novartis, Nutrafol, Abbvie, Leo, Galderma, UCB, Sun Pharmaceuticals, and Regeneron Pharmaceuticals.

References

1. Reed J, Wilkinson J. Subcorneal pustular dermatosis. *Clin Dermatol*. 2000;18:301-13. [PMID: 10856662].
2. Cohen PR. Neutrophilic dermatoses: a review of current treatment options. *Am J Clin Dermatol*. 2009;10:301-12. [PMID: 19658442].

3. Cheng S, Edmonds E, Ben-Gashir M, Yu RC. Subcorneal pustular dermatosis: 50 years on. *Clin Exp Dermatol*. 2008;33:229-33. [PMID: 18355359].
4. Orton DI, George SA. Subcorneal pustular dermatosis responsive to narrowband (TL-01) UVB phototherapy. *Br J Dermatol*. 1997;137:149-61. [PMID: 9274645].
5. Park YK, Park HY, Bang DS, Cho CK. Subcorneal pustular dermatosis treated with phototherapy. *Int J Dermatol*. 1986;25:124-6. [PMID: 3516894].
6. Sneddon IB, Wilkinson DS. Subcorneal pustular dermatosis. *Br J Dermatol*. 1956;68:385-94. [PMID: 13396129].
7. Retrouvey M, Koch LH, Williams JV. Gianotti-Crosti syndrome following childhood vaccinations. *Pediatr Dermatol*. 2013;30:137-8. [PMID: 22141410].
8. Kolivras A, André J. Gianotti-Crosti syndrome following hepatitis A vaccination. *Pediatr Dermatol*. 2008;650. [PMID: 19067881].
9. Magro C, Nuovo G, Mulvey JJ et.al. The skin as a critical window in unveiling the pathophysiologic principles of COVID-19. *Clin Dermatol*. 2021;39:934-965. [PMID: 34920833].
10. Polack FP, Thomas SJ, Kitchin N, et.al; C4591001 Clinical Trial Group. Safety and Efficacy of the BNT162b2 mRNA Covid-19 Vaccine. *N Engl J Med*. 2020;383:2603-2615. [PMID: 33301246].
11. Anand P, Stahel VP. Review the safety of Covid-19 mRNA vaccines: a review. *Patient Saf Surg*. 2021 May 1;15(1):20. Erratum in: *Patient Saf Surg*. 2021;15:22. [PMID: 33933145].