

Case presentation

Aquagenic wrinkling of the palms: a case report and literature review

Matteo Megna, Mariateresa Cantelli, Donata Martellotta, Gabriella Calabrò, Anna Balato and Fabio Ayala

Dermatology Online Journal 22 (9): 9

Department of Dermatology, University of Naples Federico II, Italy

Correspondence:

Matteo Megna, MD
Via Pansini, 5 80131 Napoli, Italy
Tel. +39 - 081 -7462457 Fax.+39 - 081 - 7462442
E-mail: mat24@libero.it

Abstract

Aquagenic wrinkling of the palms (AWP) is an unusual and rare dermatological condition characterized by excessive palmar wrinkling, occurring within a few minutes of water exposure. Cystic fibrosis (CF) or CF carrier state associated forms, drug induced cases, and idiopathic forms have been described. We report the case of a 27-year-old woman with a 7-year history of transient excessive wrinkling of her palms after brief exposure to water. We present also a comprehensive review of the literature. We believe that AWP has been underdiagnosed thus far and we would like to encourage investigations such as sweat chloride test or genetic studies in these patients because of the association with CF or CF carrier state, particularly when AWP appears in younger ages.

Key words: Aquagenic wrinkling of the palms, cystic fibrosis, transient reactive and acquired papulotranslucent acrokeratoderma, aquagenic palmoplantar keratoderma, aquagenic syringeal acrokeratoderma

Introduction

Aquagenic wrinkling of the palms (AWP) is an uncommon condition characterized by excessive wrinkling, palmar edema, and whitish papules possibly accompanied by pain, pruritus, or discomfort after brief exposure to water [1]. Etiology is unknown, but several studies indicate an association with cystic fibrosis (CF) or CF carrier state; some case reports also demonstrate various drugs as possible triggering factors [2-4]. In addition, idiopathic forms have been described [5]. We herein report a case of idiopathic AWP and perform a thorough review of the literature.

Case synopsis

A 27-year-old woman presented to our outpatient clinic with a 7-year history of transient excessive wrinkling of her palms after brief exposure to water during daily activities such as hand washing or showering. Other body sites were unaffected. The patient noted that tender swelling of the palms, followed after a few minutes by development of white papules, plaques, and wrinkling occurred shortly after water exposure. The lesions tended to resolve within 30-40 minutes after drying hands. Her medical history was unremarkable and she was taking no medications. Family history was negative for similar skin manifestations and the patient denied positive personal and family history of CF. Her palms were unremarkable on physical exam. After immersion of her hands in water for 3 minutes, numerous white translucent papules and plaques as well as marked wrinkling of both palms appeared. This “hand in bucket sign” (Figure 1) was consistent with the diagnosis of AWP.

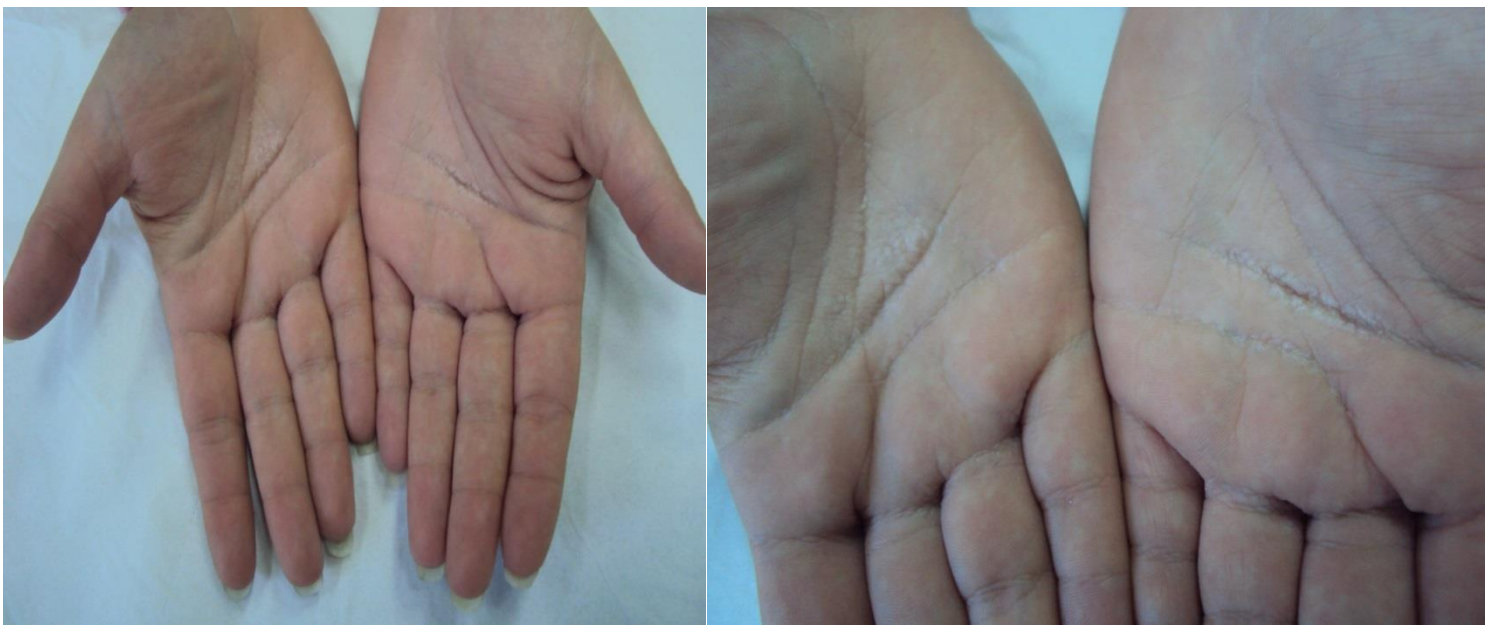


Figure 1. Appearance of translucent white papules and palmar wrinkling after hand immersion in water for 3 minutes.

Owing to the well-documented possible association of AWP with CF or a CF carrier state, a sweat chloride test and genetic studies for the most common cystic fibrosis transmembrane conductance regulator (CFTR) disease causing mutations were performed; both tests gave normal results. However, a limitation of the genetic test is its inability to detect rare CFTR mutations. Therefore, even though the patient did not present any CF related sign or symptoms and showed a CF negative family history, a CF carrier state could not be definitively excluded. The patient was put on daily treatment with topical mometasone furoate ointment 0.1% and urea 10% and was encouraged to avoid unnecessary exposure to water and humidity. Nevertheless, APW still persisted after 4 weeks. The patient refused other proposed treatments (botulinum toxin injection or iontophoresis) and the condition persisted with only little improvement regarding intensity and duration of the skin manifestations at 3 months follow-up.

Discussion

Wrinkling of the palms is a physiological response to prolonged water immersion, occurring an average of 11.5 minutes after exposure [6]. Conversely, AWP, also known as *transient reactive and acquired papulotranslucent acrokeratoderma*, *aquagenic palmoplantar keratoderma*, or *aquagenic syringeal acrokeratoderma*, is an unusual and rare dermatological condition characterized by an excessive and rapid palmar wrinkling, occurring within few minutes of water exposure. A macerated appearance of the palms appearing as white edematous translucent papules and plaques is the main feature of AWP; it may also be associated with discomfort and functional impairment [1]. Particularly, patients may complain of paraesthesia and burning or pruritic sensations with thickening and wrinkling of the palms shortly after immersion in water (2-5 minutes). The condition spontaneously resolves within several minutes to a few hours.

Idiopathic cases [5,7,8], drug induced forms [4,9], and cystic fibrosis (CF) [1,2,10-13] or CF carrier state-associated cases [3,13,14] have been described. Particularly, a detailed review of the literature showed a total of 227 cases of AWP described so far [1-5,7-53]. Most cases (154/227, 67.9%) were associated with CF, followed by idiopathic forms (57/227, 25.1%), CF carrier state related forms (10/227, 4.4%), and drug induced cases (6/227, 2.6%) (Table 1).

Table 1. AWP cases described in literature.

Patients	Mean age (years)	Sex (%)	AWP form (%)
227*	n/a*	n/a*	154 CF (67.9%) 10 CF carrier state (4.4%) 6 Drug-related (2.6%) 57 idiopathic (25.1%)
87**	22.4	36 M (41.4%) 51 F (58.6%)	20 CF 4 CF carrier state 6 drug-related 57 idiopathic

*Some studies are lacking of AWP patients' demographic data (age and sex).

**AWP patients with literature available demographic data (87/227).

AWP= aquagenic palmar wrinkling, CF= cystic fibrosis, n/a= not applicable.

However, it should be considered that genetic or sweat tests were not performed in all studies, particularly those describing idiopathic cases. Involved drugs were reported to be rofecoxib, aspirin, spironolactone, paracetamol, indometacin with sulfasalazine, ascorbic acid with clarithromycin, and the association of indomethacin, caffeine, and prochlorperazine dimaleate. Accurate data regarding age and sex were available only for 87/227 (38.3%) of the subjects, showing a higher prevalence of AWP in female patients (51/87, 58.6%) and mean age of onset of 22.4 years (range: 3-65).

The actual prevalence of AWP in the general population is unknown, but the condition is thought to be rare and its etiology and pathogenesis are still poor understood. Abnormality and weakness of sweat ducts as well as defective stratum corneum barrier function have been implied in AWP development [15,16]. It has been postulated that abnormal electrolyte fluxes resulting in sodium retention within epidermal keratinocytes and osmotically induced cell volume increase could be an explanation. Particularly, in CF and CF carrier related forms, it is believed that sweat hypertonicity induced by loss of function of CFTR through reduced electrolyte reabsorption in eccrine ducts, may lead to an increased rate of diffusion of water into palmar skin through eccrine glands ducts [18,54]. Moreover, CFTR impairment increases salt concentration in the epidermis and the water binding capacity of keratin [3]. However, dysregulation of aquaporin 3 and 5, proteins responsible for rapid water transport across cell membrane has also been proposed in AWP development, especially for CF-unrelated forms [55,56]. For example, nonsteroidal anti-inflammatory drugs use has been linked with AWP development [4,9,57] owing to the fact that these drugs are able to alter aquaporin expression and promote increased sodium reabsorption in epithelial cells through cyclooxygenase inhibition.

AWP diagnosis is easily made by the medical history. Clinical examination is generally inconclusive but the “hand in the bucket” test (water immersion) can be used to confirm AWP diagnosis. Rapid and excessive skin wrinkling is generally easily demonstrated [3]. Histopathological examination is rarely required; it generally discloses orthokeratotic hyperkeratosis, dilated eccrine ducts, and, rarely, hypergranulosis [18,49]. Because of the well-known possible association to CF or CF carrier state (44-88% and up to 25%, respectively) [12,21], patients with AWP should be promptly screened through sweat chloride and genetic testing for CFTR mutations [18]. Indeed, AWP diagnosis may be one of the main warning signs suggesting the need for further evaluations and referral to detect patients with mild forms of CF who might develop late-onset or slowly progressing disease [17].

Percentages of success in AWP management are very variable [23,24] and different treatments have been proposed: botulinum toxin injection [22,23], topical aluminum chloride [2,23,24], topical urea and salicylic acid combination [25], iontophoresis [15], 12% ammonium lactate [15], and topical corticosteroid [15,23].

This case has been here reported because of possible underreporting of AWP cases thus far. Greater awareness of AWP is needed since, given its frequent association with CF and CF carrier state, AWP diagnosis should guide dermatologists to conduct detailed medical history and physical examination in search of high-risk individuals, which require prompt further work up.

References

1. Katz KA, Yan AC, Turner ML. Aquagenic wrinkling of the palms in patients with cystic fibrosis homozygous for the delta F508 CFTR mutation. *Arch Dermatol.* 2005 May;141(5):621-4. [PMID: 15897385]
2. Chinazzo C, De Alessandri A, Menoni S, Romanisio G, Rebora A, Rongioletti F. Aquagenic wrinkling of the palms and cystic fibrosis: an Italian study with controls and genotype-phenotype correlations. *Dermatology.* 2014;228(1):60-5. [PMID: 24434749]
3. Gild R, Clay CD. Aquagenic wrinkling of the palms in a cystic fibrosis carrier. *Australas J Dermatol.* 2008 Feb;49(1):19-20. [PMID: 18186841]
4. Khuu PT, Duncan KO, Kwan A, Hoyme HE, Bruckner AL. Unilateral aquagenic wrinkling of the palms associated with aspirin intake. *Arch Dermatol.* 2006 Dec;142(12):1661-2. [PMID: 17179009]
5. Vale R, Adam DN. Idiopathic aquagenic wrinkling of the palms in sisters *J Dermatol.* 2012 May;39(5):471-2. [PMID: 22011022]
6. Tsai N, Kirkham S. Fingertip skin wrinkling - the effect of varying tonicity *J Hand Surg Br.* 2005 Jun;30(3):273-5. [PMID: 15862367]
7. Trotot C, Studer M, Waton J, Bursztejn AC, Schmutz JL, Barbaud A. Idiopathic aquagenic wrinkling of the palms. *Ann Dermatol Venereol.* 2012 May;139(5):412-3. [PMID:22578350]
8. Davis LS, Woody CM. Idiopathic aquagenic wrinkling of the palms. *Pediatr Dermatol.* 2004 Mar-Apr;21(2):180. [PMID: 15078368]
9. Carder KR, Weston WL. Rofecoxib-induced instant aquagenic wrinkling of the palms. *Pediatr Dermatol.* 2002 Jul-Aug;19(4):353-5. [PMID: 12220285]
10. Grasemann H, Ratjen F, Solomon M. Aquagenic wrinkling of the palms in a patient with cystic fibrosis. *N Engl J Med.* 2013 Dec 12;369(24):2362-3. [PMID: 24328486]
11. Arkin LM, Flory JH, Shin DB, Gelfand JM, Treat JR, Allen J, Rubenstein RC, Yan AC. High prevalence of aquagenic wrinkling of the palms in patients with cystic fibrosis and association with measurable increases in transepidermal water loss. *Pediatr Dermatol.* 2012 Sep-Oct;29(5):560-6. [PMID: 22471628]

12. Weibel L, Spinas R. Images in clinical medicine. Aquagenic wrinkling of palms in cystic fibrosis. *N Engl J Med*. 2012 May 24;366(21):e32. [PMID: 22621642]
13. Gild R, Clay CD, Morey S. Aquagenic wrinkling of the palms in cystic fibrosis and the cystic fibrosis carrier state: a case-control study. *Br J Dermatol*. 2010 Nov;163(5):1082-4. [PMID: 20560957]
14. Park L, Khani C, Tamburro J. Aquagenic wrinkling of the palms and the potential role for genetic testing. *Pediatr Dermatol*. 2012 May-Jun;29(3):237-42. [PMID:22044449]
15. MacCormack MA, Wiss K, Malhotra R. Aquagenic syringeal acrokeratoderma: report of two teenage cases *J Am Acad Dermatol*. 2001 Jul;45(1):124-6. [PMID:11423847]
16. Itin PH, Lautenschlager S. Aquagenic syringeal acrokeratoderma (transient reactive papulotranslucent acrokeratoderma). *Dermatology*. 2002;204(1):8-11. [PMID: 11834842]
17. Garçon N, Roguedas AM, Misery L, Audrezet MP, Ferec C. Aquagenic wrinkling of the palms in a patient with cystic fibrosis heterozygous for the DeltaF 508 mutation. *Ann Dermatol Venereol*. 2008 Mar;135(3):232-4. [PMID: 18374861]
18. Gild R. Aquagenic wrinkling of the palms. *Skinmed*. 2012 Jul-Aug;10(4):203-4. [PMID: 23008935]
19. Bhojani S, Sriskandan S, Bush A. Aquagenic wrinkling of palms on exposure to alcohol gel. *Pediatr Pulmonol*. 2011 Jan;46(1):98-9. [PMID: 21171188]
20. Glatz M, Muellegger RR. Drug-associated aquagenic wrinkling of the palms in an atopic male patient. *BMJ Case Rep*. 2014 Jun 5;2014. [PMID: 24903725]
21. Garçon-Michel N, Roguedas-Contios AM, Rault G, Le Bihan J, Ramel S, Revert K, Dirou A, Misery L. Frequency of aquagenic palmoplantar keratoderma in cystic fibrosis: a new sign of cystic fibrosis? *Br J Dermatol*. 2010 Jul;163(1):162-6. [PMID: 20302572]
22. Diba VC, Cormack GC, Burrows NP. Botulinum toxin is helpful in aquagenic palmoplantar keratoderma. *Br J Dermatol*. 2005 Feb;152(2):394-5. [PMID:15727674]
23. Uyar B. Aquagenic syringeal acrokeratoderma. *Indian J Dermatol*. 2014 Nov;59(6):632. [PMID: 25484422]
24. Stewart LC, Doe SJ, Bourke SJ, Leech S. Aquagenic palmar wrinkling as a presenting feature of cystic fibrosis gene dysfunction. *Clin Exp Dermatol*. 2009 Dec;34(8):e647-9. [PMID: 19548945]
25. Ertürk-Özdemir E, Özcan D, Seçkin D. Acquired aquagenic syringeal acrokeratoderma: A case series of 10 patients. *Australas J Dermatol*. 2015 May;56(2):e43-5. [PMID: 24283504]
26. Gündüz O, Ozsaraç KÇ, Ercin ME. Aquagenic palmar wrinkling induced by combined use of salazopyrin and indomethacin. *Case Rep Dermatol*. 2013 Jan;5(1):21-6. [PMID: 23466824]
27. Chambers CJ, Konia T, Burrall B, Fung MA, Sharon V. Unilateral prickly palmar papules. Punctate prokeratotic keratoderma (PPK). *Arch Dermatol*. 2011 May;147(5):609-14. [PMID: 21576584]
28. Tolland JP, Boyle J, Hall V, McKenna KE, Elborn JS. Aquagenic wrinkling of the palms in an adult cystic fibrosis population. *Dermatology*. 2010;221(4):326-30. [PMID: 20881360]
29. Gualdi G, Pavoni L, Monari P, Calzavara-Pinton P, Manganoni MA. Dermoscopy of drug-induced aquagenic wrinkling phenomenon *J Eur Acad Dermatol Venereol*. 2015 Mar 31. [PMID: 25827615]
30. Okuhira H, Matsunaka H, Iwahashi Y, Nakamura Y, Furukawa F, Yamamoto Y. Case report of aquagenic wrinkling of the palms associated with impaired stratum corneum function. *J Dermatol*. 2015 Sep;42(9):913-4. [PMID: 26047387]
31. Lim KS, Ng SK. Aquagenic wrinkling of the palms in a boy with a congenital cardiac anomaly. *J Eur Acad Dermatol Venereol*. 2007 Aug;21(7):985-6. [PMID:17659016]
32. Poiraud C, Vourc'h-Jourdain M, Cassagnau E, Barbarot S. Aquagenic palmoplantar keratoderma associated with acrokeratoelastoidosis. *Clin Exp Dermatol*. 2014 Jul;39(5):671-2. [PMID: 24708219]
33. Syed Z, Wanner M, Ibrahim OA. Aquagenic wrinkling of the palms: A case report and literature review. *Dermatol Online J*. 2010 Jul 15;16(7):7. [PMID: 20673535]
34. Tchernev G, Semkova K, Cardoso JC, Ananiev JJ, Wollina U. Aquagenic keratoderma. Two new case reports and a new hypothesis. *Indian Dermatol Online J*. 2014 Jan;5(1):30-3. [PMID: 24616851]
35. Bonhomme A, Barbaud A, Schmutz JL, Bursztejn AC. Aquagenic palmoplantar keratoderma during treatment of Langerhans cell histiocytosis. *Ann Dermatol Venereol*. 2015 Mar;142(3):197-200. [PMID: 25683007]
36. Poletti ED, Muñoz-Sandoval R. Images in clinical medicine. Aquagenic keratoderma. *N Engl J Med*. 2014 Sep 4;371(10):952. [PMID: 25184867]
37. Martín JM, Pellicer ZM, Bella R, Jordá E. Transient aquagenic palmar hyperwrinkling. *J Pediatr*. 2013 Jun;162(6):1296, 1296.e1. [PMID: 23332464]
38. Baldwin BT, Prakash A, Fenske NA, Messina JL. Aquagenic syringeal acrokeratoderma: report of a case with histologic findings. *J Am Acad Dermatol*. 2006 May;54(5):899-902. [PMID: 16635679]
39. Falcón CS, Ortega SS. Aquagenic syringeal acrokeratoderma. *J Am Acad Dermatol*. 2008 Nov;59(5 Suppl):S112-3. [PMID:19119115]
40. English JC 3rd, McCollough ML. Transient reactive papulotranslucent acrokeratoderma. *J Am Acad Dermatol*. 1996 Apr;34(4):686-7. [PMID: 8601664]
41. Schmults C, Sidhu G, Urbanek RW. Aquagenic syringeal acrokeratoderma. *Dermatol Online J*. 2003 Oct;9(4):27. [PMID: 14594600]
42. D'Erme AM, Braggion C, de Martino M, Greco A. Aquagenic palmoplantar keratoderma: a sign of cystic fibrosis early in life. *Int J Dermatol*. 2014 Nov;53(11):e536-8. [PMID: 25069884]

43. Lowes MA, Khaira GS, Holt D. Transient reactive papulotranslucent acrokeratoderma associated with cystic fibrosis. *Australas J Dermatol*. 2000 Aug;41(3):172-4. [PMID: 10954989]
44. Neri I, Bianchi F, Patrizi A. Transient aquagenic palmar hyperwrinkling: the first instance reported in a young boy. *Pediatr Dermatol*. 2006 Jan-Feb;23(1):39-42. [PMID: 16445410]
45. Darlenski R, Tsankov N. Aquagenic syringeal acrokeratoderma. *J Dtsch Dermatol Ges*. 2012 Mar;10(3):198. [PMID: 22128881]
46. Yalcin B, Artuz F, Toy GG, Lenk N, Alli N. Acquired aquagenic papulotranslucent acrokeratoderma. *J Eur Acad Dermatol Venereol*. 2005 Sep;19(5):654-6. [PMID: 16164739]
47. Betlloch I, Vergara G, Albares MP, Pascual JC, Silvestre JF, Botella R. Aquagenic keratoderma *J Eur Acad Dermatol Venereol*. 2003 May;17(3):306-7. [PMID: 12702072]
48. Luo DQ, Zhao YK, Zhang WJ, Wu LC. Aquagenic acrokeratoderma. *Int J Dermatol*. 2010 May;49(5):526-31. [PMID:20015211]
49. Rongioletti F, Tomasini C, Crovato F, Marchesi L. Aquagenic (pseudo) keratoderma: a clinical series with new pathological insights. *Br J Dermatol*. 2012 Sep;167(3):575-82. [PMID: 22512866]
50. Luo DQ, Li Y, Huang YB, Wu LC, He DY. Aquagenic syringeal acrokeratoderma in an adult man: case report and review of the literature. *Clin Exp Dermatol*. 2009 Dec;34(8):e907-9. [PMID:20055864]
51. Tan C, Zhu W. Atypical form of transient reactive papulotranslucent acrokeratoderma: a case report and review of the literature. *Int J Dermatol*. 2010 Aug;49(8):937-40. [PMID: 21128920]
52. Ghosh SK, Agarwal M, Ghosh S, Dey AK. Aquagenic palmar wrinkling in two Indian patients with special reference to its dermoscopic pattern. *Dermatol Online J*. 2015 Jun 16;21(6). [PMID: 26158367]
53. Houle MC, Al Dhaybi R, Benohanian A. Unilateral aquagenic keratoderma treated with botulinum toxin A. *J Dermatol Case Rep*. 2010 Apr 11;4(1):1-5. [PMID: 21886737]
54. Mishra A, Greaves R, Massie J. The relevance of sweat testing for the diagnosis of cystic fibrosis in the genomic era. *Clin Biochem Rev*. 2005 Nov;26(4):135-53. [PMID: 16648884]
55. Schreiber R, Pavenstädt H, Greger R, Kunzelmann K. Aquaporin 3 cloned from *Xenopus laevis* is regulated by the cystic fibrosis transmembrane conductance regulator. *FEBS Lett*. 2000 Jun 23;475(3):291-5. [PMID: 10869574]
56. Kabashima K, Shimauchi T, Kobayashi M, Fukamachi S, Kawakami C, Ogata M, Kabashima R, Mori T, Ota T, Fukushima S, Hara-Chikuma M, Tokura Y. Aberrant aquaporin 5 expression in the sweat gland in aquagenic wrinkling of the palms. *J Am Acad Dermatol*. 2008 Aug;59(2 Suppl 1):S28-32. [PMID: 18625374]
57. Lauridsen TG, Vase H, Starklint J, Graffe CC, Bech JN, Nielsen S, Pedersen EB. Increased renal sodium absorption by inhibition of prostaglandin synthesis during fasting in healthy man. A possible role of the epithelial sodium channels. *BMC Nephrol*. 2010 Oct 28;11:28. [PMID: 21029429]