

# A case of segmental Darier disease treated with doxycycline monotherapy

Cory Pettit<sup>1</sup>, Catherine A Ulman<sup>2</sup> MD, Gina Spohn<sup>2</sup> MD, Jessica Kaffenberger<sup>2</sup> MD

Affiliations: <sup>1</sup>College of Medicine, The Ohio State University, Columbus, Ohio, USA, <sup>2</sup>Division of Dermatology, The Ohio State University Wexner Medical Center, Columbus, Ohio, USA

Corresponding Author: Jessica Kaffenberger, 540 Officenter PI Suite 430, Gahanna, OH 43230. Email: Jessica.kaffenberger@osumc.edu

## Abstract

Darier disease is a rare autosomal dominant disorder that results from a mutation in the gene coding for the endoplasmic reticulum membrane calcium pump Ca<sup>2+</sup>-ATPase type 2 (SERCA2), leading to compromised intercellular adhesion. Patients typically present in the first two decades of life with keratotic, greasy papules in a seborrheic distribution. Segmental Darier disease is a variant with localized disease that follows Blaschko lines. Treatment options include topical and systemic agents including corticosteroids, retinoids, and antibiotics. We present a 67-year-old woman who came to our clinic with segmental Darier disease recalcitrant to topical therapy. Owing to cost and side effect profile, the patient declined treatment with oral retinoids. Doxycycline 100mg daily was started with significant improvement. Tetracyclines both chelate and assist calcium to cross membranes. This mechanism may correct the cellular calcium imbalance present in Darier disease. In addition, tetracyclines have been shown to inhibit metalloproteinase 9, an important part of Darier disease pathogenesis. Owing to its favorable side effect profile, further investigation is warranted to establish doxycycline as a more widely utilized treatment option for Darier disease.

*Keywords: Darier disease, doxycycline, Grover disease*

## Introduction

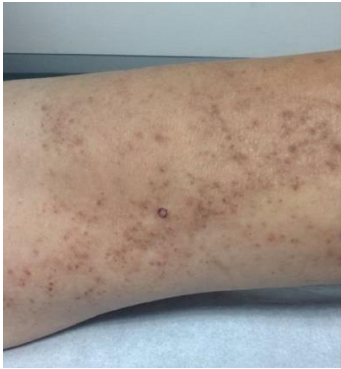Darier disease is a rare autosomal dominant disorder with variable expressivity, high penetrance, and a

prevalence between 1 in 55,000 to 1 in 100,000 [1]. The disease presents with keratotic, greasy papules in seborrheic areas such as the scalp, forehead, trunk, and flexures. The papules often coalesce and are prone to secondary infection. A rare variant of the disease, segmental Darier disease, presents with unilateral lesions limited to the Blaschko lines. It is thought that this variant is caused by a post-zygotic somatic mutation, and is only heritable if mosaicism involves the gonads [2]. Treatment options include a combination of systemic and topical therapies. Oral retinoid therapy is a very effective treatment for Darier disease, but has significant side effects including elevated lipids, alopecia, and elevated liver function tests. Herein, we present a patient with segmental Darier disease successfully treated with doxycycline.

## Case Synopsis

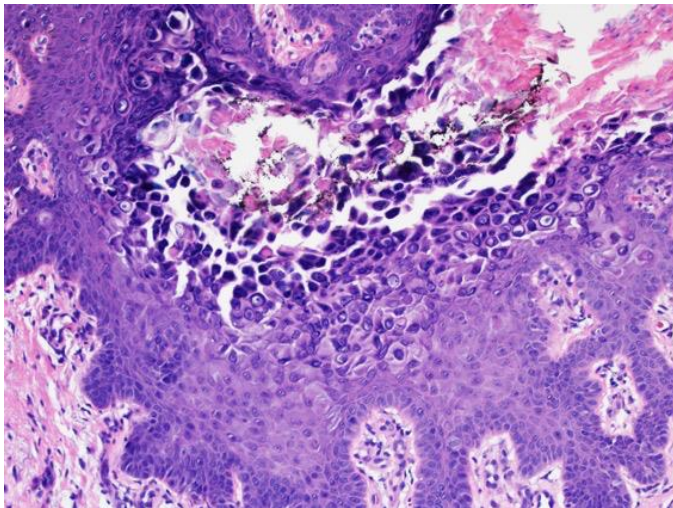
A 67-year-old woman with a history of stage I melanoma presented to our clinic with pink-brown crusted papules in a linear distribution extending from the knee to the groin (**Figure 1**).

She noted recurrent flares in the summer and improvement over the fall and winter. She previously had good control of her symptoms on isotretinoin, but she reported significant depression on the drug. Given the unusual unilateral involvement of the eruption on the upper left thigh, a 4mm punch biopsy performed. The biopsy showed suprabasilar acantholytic dyskeratosis, and corps ronds and corps



**Figure 1.** Photo of left upper medial thigh at time of presentation. Papules and crusting due to segmental Darier disease are present.

grains (**Figure 2**). With the history, clinical presentation and this pathology, a diagnosis of segmental Darier disease was made.

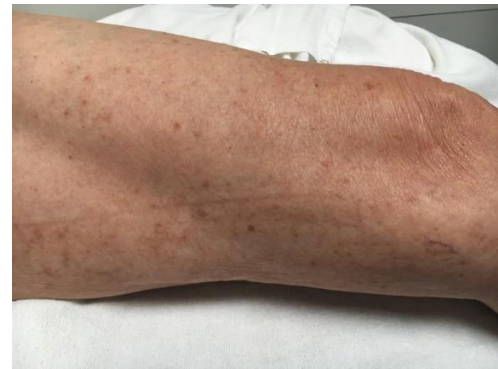

**Figure 2.** Biopsy demonstrating suprabasilar acantholytic dyskeratosis, corps ronds and grains. H&E, 400x.

Treatment, including topical and systemic retinoids was offered. However, considering cost and side effect profile, the patient declined this treatment. Thus, 100mg daily doxycycline was initiated. The patient presented at her 6 week follow up with significant improvement (**Figure 3**) and no reported side effects from the medication.

### Case Discussion

The gene mutation that causes Darier disease, *ATP2A2* on chromosome 12, encodes the calcium pump  $\text{Ca}^{2+}$ -ATPase type 2 (SERCA2) [3]. Calcium homeostasis is thought to influence cell-cell adhesion via several mechanisms. In vitro, the



**Figure 3.** Photo of left upper medial thigh after 6-week treatment with doxycycline. The papules and crusting had resolved, and the patient reported a resolution of symptoms.

assembly of desmosomes can be induced by increased extracellular calcium concentration [4]. Changes in intracellular calcium levels have also been shown to induce cell-cell adhesion [5]. Additionally, calcium-dependent signaling is required for the processing of desmoplakin, an important component of the desmosome interface [5]. Blockage of the SERCA pump has been shown to deplete endoplasmic reticulum calcium stores and lead to impaired intercellular adhesion [6]. Histologically, Darier disease presents with acantholysis, dyskeratosis, and large, pale keratinocytes surrounded by clear halos [1].

Treatment of Darier disease includes general preventative measures such as sun and heat avoidance, antimicrobial washes, exfoliating emollients, topical retinoids, topical corticosteroids, and both topical and systemic antibiotics. Systemic therapies that are widely used include the retinoids isotretinoin and acitretin, which exert an anti-proliferative effect on the epithelium. The side effects with retinoids, however, are numerous and include mucosal dryness, skin fragility, impaired renal function, abnormal lipid profile, and hepatic dysfunction [1]. In this case, doxycycline was chosen for its anti-inflammatory effects via inhibition of metalloproteinase 9, which has been shown to play a part in Darier disease pathogenesis [8]. Doxycycline also acts as an ionophore, chelating calcium ions and facilitating their transport across the cell membrane [9]. By normalizing intracellular and endoplasmic reticulum calcium stores, doxycycline may help restore the cell to cell adhesion that is lost in Darier

disease. To our knowledge, there has only been one previously published report of treatment of Darier disease with doxycycline [7].

## Conclusion

Darier disease can be recalcitrant to treatment. The

most widely used therapy of, oral retinoids [1], is effective but has considerable side effects. Owing to its more favorable side effect profile, further investigation is warranted to establish doxycycline as a more widely utilized treatment option for Darier disease.

## References

1. Cooper SM, Burge SM. Darier's disease: epidemiology, pathophysiology, and management. *Am J Clin Dermatol*. 2003;4(2):97-105. [PMID: 12553850].
2. Barfield RL, Barrett KR, Moon CM, David-Bajar K. Pruritic linear papules on a 75-year-old woman: a case of localized Darier-White disease. *Cutis*. 2002;70(4):225-8. [PMID: 12403314].
3. Sakuntabhai A, Ruiz-Perez V, Carter S, Jacobsen N, Burge S, Monk S, Smith M, Munro CS, O'Donovan M, Craddock N, Kucherlapati R, Rees JL, Owen M, Lathrop GM, Monaco AP, Strachan T, Hovnanian A. Mutations in ATP2A2, encoding a Ca<sup>2+</sup> pump, cause Darier disease. *Nat Genet*. 1999;21(3):271-7. [PMID: 10080178].
4. Watt FM, Matthey DL, Garrod DR. Calcium-induced reorganization of desmosomal components in cultured human keratinocytes. *J Cell Biol*. 1984;99(6):2211-5. [PMID: 6209289].
5. Stuart RO, Sun A, Bush KT, Nigam SK. Dependence of epithelial intercellular junction biogenesis on thapsigargin-sensitive intracellular calcium stores. *J Biol Chem*. 1996;271(23):13636-41. [PMID: 8662885].
6. Lytton J, Westlin M, Hanley MR. Thapsigargin inhibits the sarcoplasmic or endoplasmic reticulum Ca-ATPase family of calcium pumps. *J Biol Chem*. 1991;266(26):17067-71. [PMID: 1832668].
7. Sfecci A, Orion C, Darrieux L, Tisseau L, Safa G. Extensive Darier Disease Successfully Treated with Doxycycline Monotherapy. *Case Rep Dermatol*. 2015;7(3):311-5. Epub 2015/10/29. [PMID: 26594170].
8. Kobayashi T, Sakuraoka K, Hattori S, Hori H, Nagai Y, Tajima S, Nishikawa T. Immunolocalization of human gelatinase (type IV collagenase, MMP-9) and tissue inhibitor of metalloproteinase 1 in Hailey-Hailey and Darier's diseases. *Dermatology*. 1996;193(2):110-4. [PMID: 8884145].
9. Sapadin AN, Fleischmajer R. Tetracyclines: nonantibiotic properties and their clinical implications. *J Am Acad Dermatol*. 2006;54(2):258-65. [PMID: 16443056].