

UC Davis

Dermatology Online Journal

Title

Porokeratosis ptychotropica: a rare variant of porokeratosis

Permalink

<https://escholarship.org/uc/item/26d5p9v7>

Journal

Dermatology Online Journal, 20(6)

Authors

D'souza, Paschal
Dhali, Tapan Kumar
Arora, Shikha
[et al.](#)

Publication Date

2014

DOI

10.5070/D3206022872

Copyright Information

Copyright 2014 by the author(s). This work is made available under the terms of a Creative Commons Attribution-NonCommercial-NoDerivatives License, available at <https://creativecommons.org/licenses/by-nc-nd/4.0/>

Peer reviewed

Case Presentation

Porokeratosis ptychotropica: a rare variant of porokeratosis

Paschal D'souza, Tapan Kumar Dhali, Shikha Arora, Himanshu Gupta, Urmi Khanna

Dermatology Online Journal 20 (6): 12

Department of Dermatology, ESI- PGIMSR, Basaidarapur, New Delhi, India

Correspondence:

Shikha Arora
Department of Dermatology
ESI- PGIMSR
Basaidarapur, New Delhi, India
dr_shikhaarora@yahoo.co.in

Abstract

Background: Porokeratosis, a well recognized disorder of keratinization, is known to have several clinical variants. This report describes a rare variant characterized by verrucous plaques.

Methods: An adult male presented with a slowly progressive verrucous plaque on the gluteal region **that was** resistant to conventional therapy. Careful inspection revealed a keratotic ridge at the plaque border leading to the diagnosis.

Results: Histopathology showed the presence of multiple cornoid lamellae confirming the diagnosis of porokeratosis ptychotropica.

Conclusions: Porokeratosis ptychotropica is a rare variant of porokeratosis with fewer than 25 cases described in the literature. This report is to highlight the importance of considering this particular entity in the diagnosis of genitogluteal plaques, especially those not responding to conventional modalities.

Introduction

Porokeratosis is a disorder of keratinization, characterized clinically by hyperkeratotic papules or plaques with a thread-like elevated border and histologically by a cornoid lamella. Six clinical variants are commonly recognized: classic porokeratosis of Mibelli, disseminated superficial porokeratosis, disseminated superficial actinic porokeratosis, porokeratosis palmaris et plantaris disseminata, linear porokeratosis, and punctate porokeratosis [1]. We report a rare variant confined to the perianal area.

Case synopsis

A 37-year-old Indian man presented with a dark colored, mildly itchy plaque involving both buttocks for the past 25 years. It started as a pea-sized raised papule on the anal cleft and slowly progressed over the next 15-20 years. He had no history of tuberculosis or other infectious or systemic diseases. Family history was non-contributory. The plaque had been surgically excised 13 years previously but recurred at the same site. Previous therapy with topical potent corticosteroids, systemic antifungals, as well as antitubercular therapy (for 7 days) was ineffective.

On examination, a well-defined “butterfly” shaped greyish black, verrucous plaque, measuring 15×10 cm, was present bilaterally on the buttocks and on the anal cleft with sparing of the anal margin (Figure 1). There was central clearing and

crusting on some areas of the plaque. On close inspection, a keratotic peripheral ridge was seen throughout most of the lesion. The remaining cutaneous and systemic examination was unremarkable.

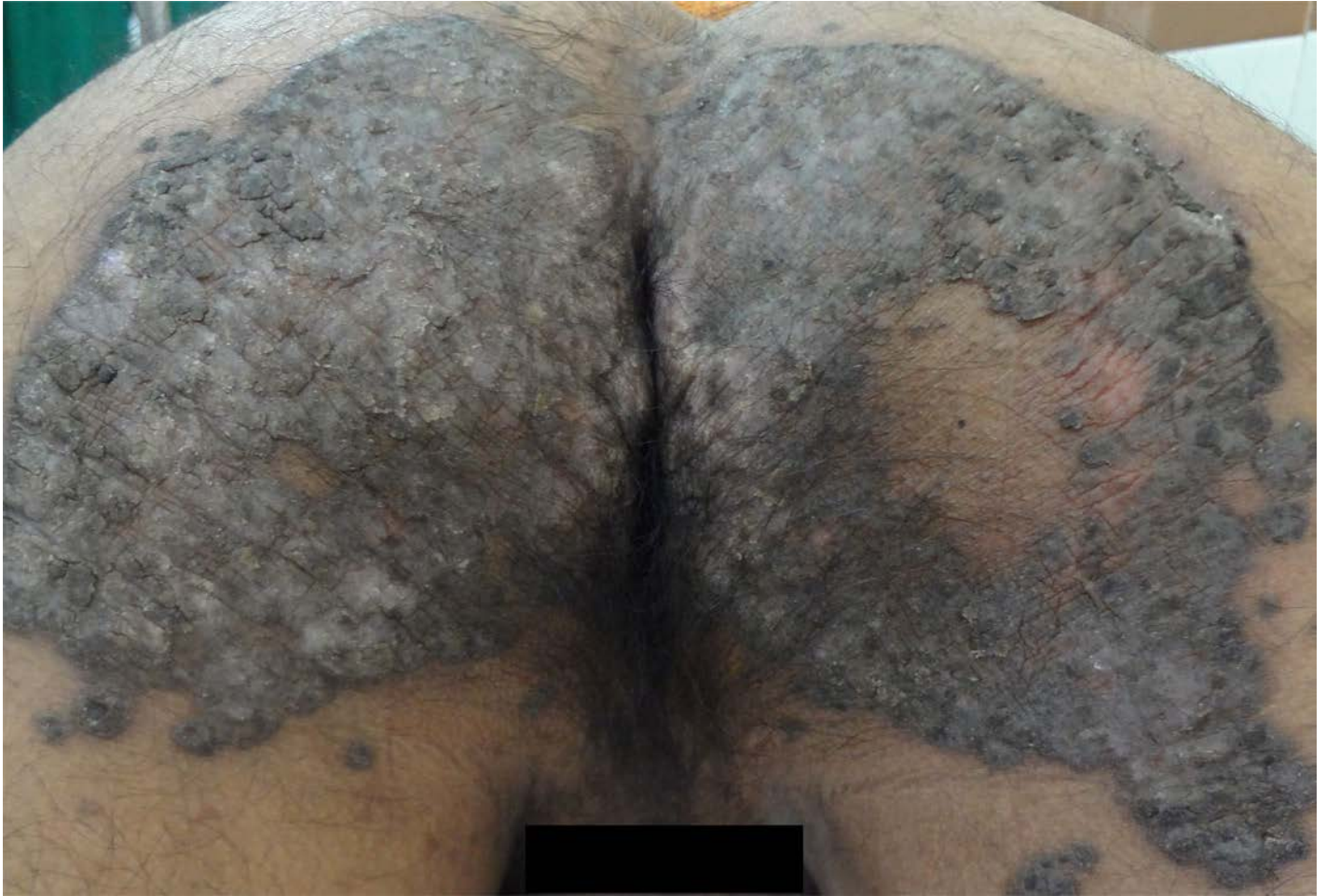

Figure 1. 'Butterfly shaped' verrucous plaque over buttocks with crusting at a few places

Routine blood investigations and chest X-ray were normal. Mantoux test revealed 12×12 mm induration at 48 hours. The differential diagnoses included hyperkeratotic lupus vulgaris, chromoblastomycosis, tuberculosis verrucosa cutis, porokeratosis, and squamous cell carcinoma.

A punch biopsy from the margin sent for histopathological examination showed epidermal hyperkeratosis with multiple foci of parakeratosis suggestive of cornoid lamellae, a diminished granular layer, as well as irregularly arranged underlying keratinocytes with intercellular edema and a few dyskeratotic cells. The dermis showed a patchy lymphohistiocytic infiltrate (Figure 2a, Figure 2b).

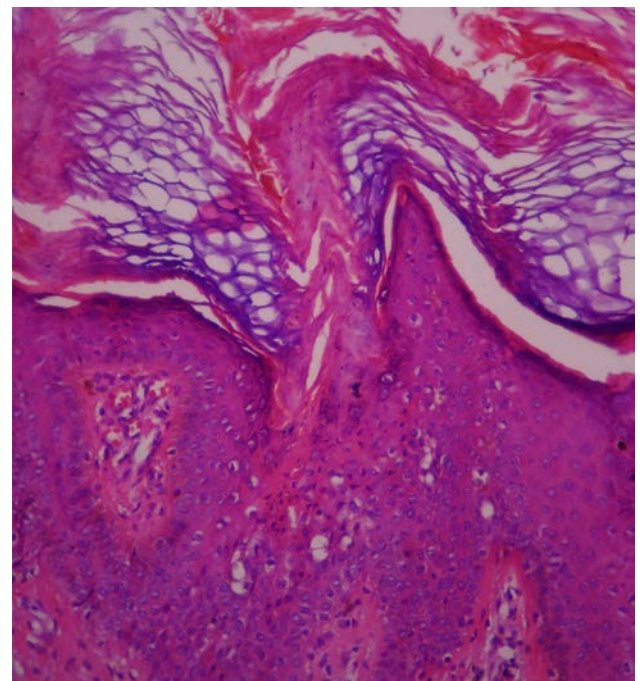
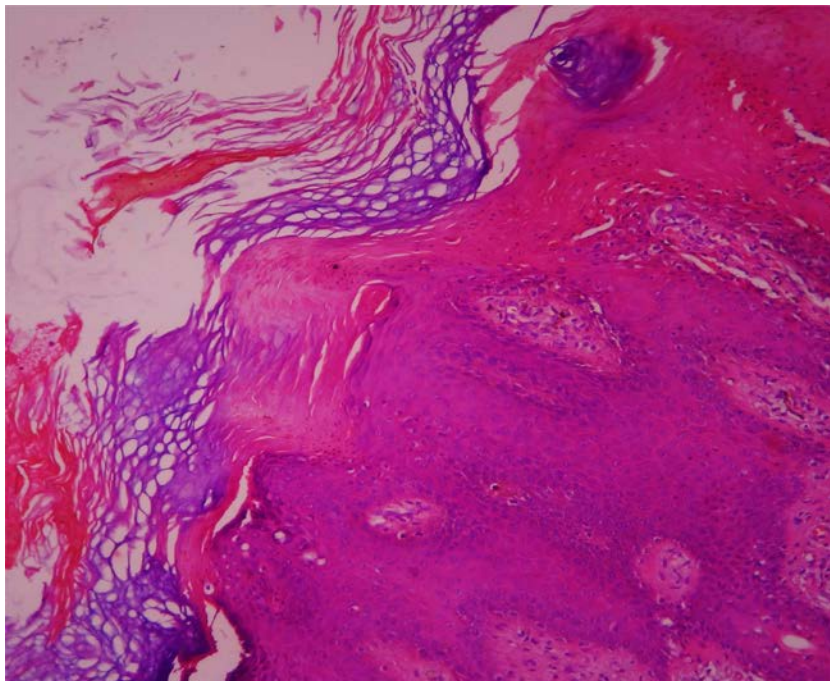


Figure 2a. Histopathological examination showing multiple cornoid lamellae (H&E x100)

Figure 2b. Higher magnification showing a column of parakeratosis, diminished granular layer and underlying dyskeratotic keratinocytes (H&E x400)

On PAS staining, there were no amyloid deposits. On the basis of clinical and histopathological findings, a diagnosis of porokeratosis ptychotropica was established.

The patient was treated with oral isotretinoin, 30 mg daily, and topical 5-fluorouracil 1% cream applied every other day. He showed improvement in itching and resolution of crusts as well as slight flattening of the lesion within 4 weeks (Figure 3). However the patient was then lost to follow up.

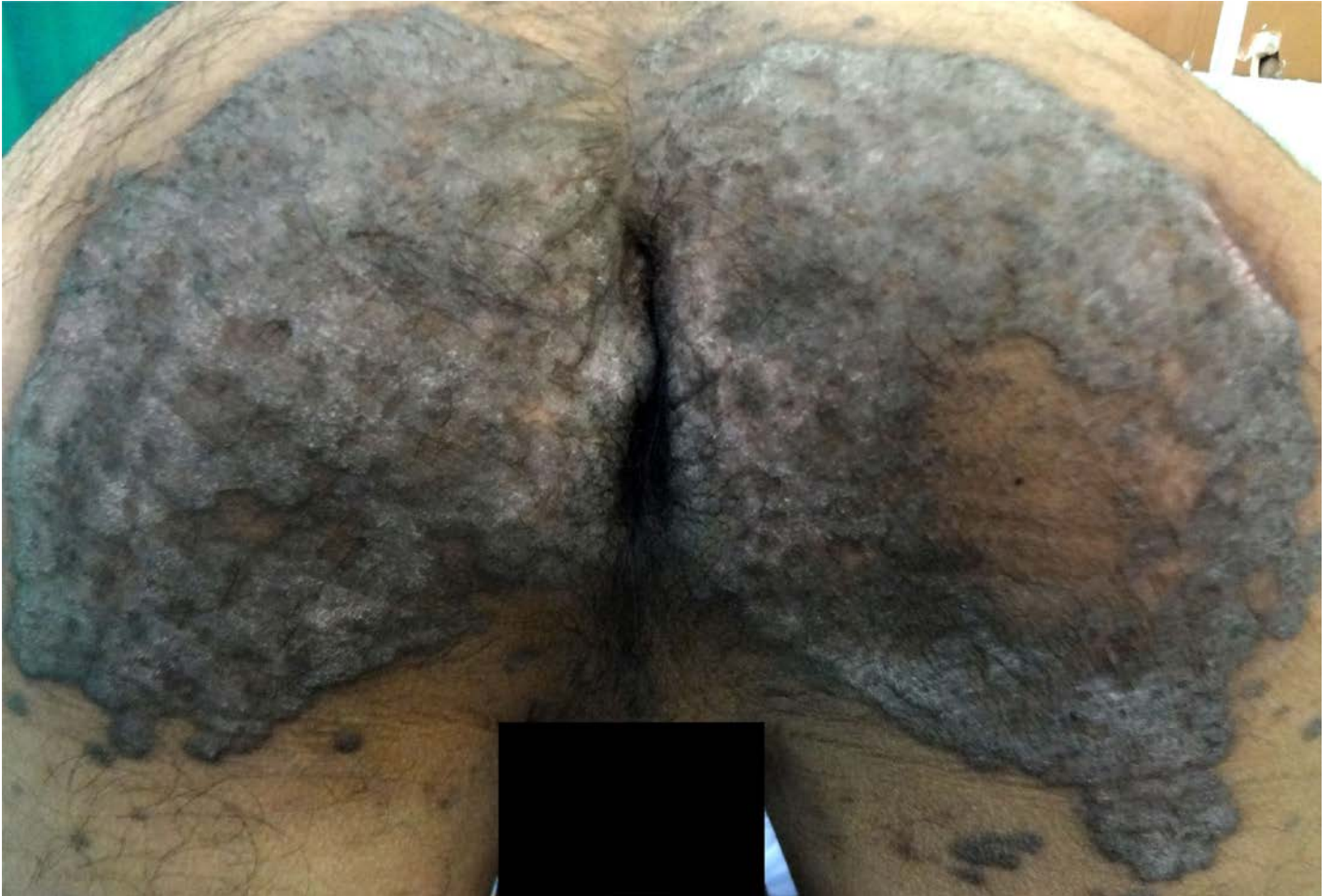

Figure 3. Slight flattening with resolution of crusts after 4-week therapy with oral isotretinoin and topical 5-fluorouracil

Conclusion

We report a case of the rare porokeratosis variant, porokeratosis ptychotropica, in an Indian man with the aim of increasing awareness of this distinct porokeratosis subtype. Less than 25 cases have been reported to date, leading to a high probability of misdiagnosis.

In 1995, Lucker, Happle, and Steijlen[2] described the first case of porokeratosis ptychotropica using the Greek words *ptyche* (fold) and *trope* (a turning) to depict the flexural distribution of this condition. Subsequently terms like “perianal inflammatory verrucous porokeratosis [3]”, and “verrucous porokeratosis [4]” have also been used to describe this condition. Usually known to occur alone, this variant can also occur with other forms of porokeratosis [5].

The clinical clues aiding in the diagnosis include the tendency to form a butterfly shaped scaly plaque on the buttocks surrounding the anus. The growth is often slow, occurring over the course of 5–10 years [4]. Pruritus is often present, unlike in porokeratosis of Mibelli [6].

On H&E staining, multiple layers of concentric cornoid lamellae are present, which is unique to this variant of porokeratosis and probably contributes to its verrucoid appearance [4]. Dermal amyloid deposits, though not present in our case, have also been reported in some cases [7,8].

A timely recognition of this condition is important because counselling and follow up are required owing to the small potential risk of malignant transformation [4]. This variant of porokeratosis has also been observed to be non-responsive to conventional modalities of treatment, including topical steroids, retinoids, tacrolimus, PUVA, imiquimod, and vitamin A [3,7,9]. Some improvement has been reported with topical 5-fluorouracil, CO₂ laser, and dermabrasion, but recurrence has been noted after CO₂ laser treatment [9]. However, the treatment response in our case could not be definitely ascertained because the patient was lost to follow up after showing an initial improvement at 4 weeks.

We suggest that in the future this entity may be added to the classification of porokeratosis and should be considered in the differential diagnosis of non-venereal gluteal plaques.

References

1. O'Regan G, Irvine AD. Porokeratosis. In: Fitzpatrick's Dermatology in General Medicine (Goldsmith LA, Katz SI, Gilchrest BA, Paller AS, Leffell DJ, Wolff K, eds), 8th edn. New York: McGraw-Hill, 2012: 563-8.
2. Lucker GPH, Happle R, Steijlen PM. An unusual case of porokeratosis involving the natal cleft: porokeratosis ptychotropica? *Br J Dermatol.* 1995 Jan;132(1):150-1. [PMID: 7756129]
3. Stone N, Ratnavel R, Wilkinson JD. Bilateral perianal inflammatory verrucous porokeratosis (porokeratosis ptychotropica). *Br J Dermatol.* 1999 Mar;140(3):553-5. [PMID: 10233294]
4. Takiguchi RH, White KP, White CR Jr, Simpson EL. Verrucous porokeratosis of the gluteal cleft (porokeratosis ptychotropica): a rare disorder easily misdiagnosed. *J Cutan Pathol.* 2010 Jul;37(7):802-7. [PMID: 19638069]
5. Murase J, Gilliam AC. Disseminated superficial actinic porokeratosis co-existing with linear and verrucous porokeratosis in an elderly woman: Update on the genetics and clinical expression of porokeratosis. *J Am Acad Dermatol.* 2010 Nov;63(5):886-91. [PMID: 20451293]
6. Corradin MT, Giulioni E, Forcione M, Fiorentino R, Faggion D, Alaibac M, Belloni-Fortina A. Porokeratosis ptychotropica. *Eur J Dermatol.* 2011 May-Jun;21(3):416-7. [PMID: 21527368]
7. Jee MS, Chang SE, Suh HS, Choi JH, Sung KJ, Moon KC, Koh JK. Porokeratosis ptychotropica associated with dermal amyloid deposits. *Clin Exp Dermatol.* 2003 Jul;28(4):450-2. [PMID: 12823315]
8. Ramírez-Santos A, Suárez-Amor O, Pérez-Pérez L, Loureiro M, Peteiro C, Toribio J. Localized cutaneous amyloidosis secondary to porokeratosis: a retrospective histopathologic study of 30 patients. *Actas Dermosifiliogr.* 2008 Oct;99(8):639-43. [PMID: 19080895]
9. Wallner JS, Fitzpatrick JE, Brice SL. Verrucous porokeratosis of Mibelli on the buttocks mimicking psoriasis. *Cutis.* 2003 Nov;72(5):391-3. [PMID: 14655780]