

UC Davis

Dermatology Online Journal

Title

Temozolomide-induced inflammation of disseminated superficial actinic porokeratosis

Permalink

<https://escholarship.org/uc/item/25m6s6nc>

Journal

Dermatology Online Journal, 24(3)

Authors

Lee, Dylan E
Kaffenberger, Benjamin H
Gru, Alejandro A
et al.

Publication Date

2018

DOI

10.5070/D3243038616

Copyright Information

Copyright 2018 by the author(s). This work is made available under the terms of a Creative Commons Attribution-NonCommercial-NoDerivatives License, available at <https://creativecommons.org/licenses/by-nc-nd/4.0/>

Peer reviewed

Temozolomide-induced inflammation of disseminated superficial actinic porokeratosis (DSAP)

Dylan E. Lee^{1,2} BS, Benjamin H Kaffenberger¹ MD, Alejandro A Gru³ MD; and Dathan Hamann¹ MD

Affiliations: ¹Department of Internal Medicine, Division of Dermatology, The Ohio State University Wexner Medical Center, Gahanna, Ohio, USA, ²Creighton University School of Medicine, Omaha, Nebraska, USA, ³Department of Pathology, University of Virginia Medical Center, Charlottesville, Virginia, USA

Corresponding Author: Dathan Hamann MD, 2012 Kenny Road, Room 232, Columbus, OH 43212, E-mail: Dathan.Hamann@osumc.edu

Abstract

We report a case of temozolomide (TMZ)-induced inflammation of disseminated superficial actinic porokeratosis (DSAP), an uncommon and pre-malignant cutaneous disorder. Dermatologists and oncologists should be aware of this cutaneous eruption of DSAP associated with TMZ to prevent the discontinuation of effective medical therapy in cancer patients.

Keywords: disseminated superficial actinic porokeratosis, DSAP, temozolomide, chemotherapy

Introduction

Distinguishing between low and high morbidity cutaneous effects of chemotherapy is important to prevent the discontinuation or delay of effective medical therapy in cancer patients. Although inflammation and emergence of sub-clinical actinic keratoses is a well-described phenomenon in patients undergoing chemotherapy [1-3], we report a case of temozolomide (TMZ)-induced inflammation of disseminated superficial actinic porokeratosis (DSAP). DSAP is an uncommon and pre-malignant cutaneous disorder characterized by agminated, pink, scaly papules with pronounced hyperkeratotic borders, which commonly occur on sun-exposed extremities. This border corresponds to a pathognomonic histopathologic finding of

diagonally-stacked, eosinophilic parakeratosis called a cornoid lamella.

Case Synopsis

A 47-year-old man with a left temporal lobe glioblastoma status post resection, 2 cycles of adjuvant radiotherapy, and TMZ was referred to the dermatology clinic with a 1-month history of a progressive, non-painful, non-itchy, pink, and scaly rash on the bilateral forearms, which emerged after his second cycle of TMZ. His oncologist wanted to rule out drug hypersensitivity syndrome prior to proceeding with a third cycle of TMZ. Interestingly, he reported being a welder and strongly suspected that the rash appeared within scars he had sustained during welding. Physical exam revealed several dozen round, pink, scaly papules and plaques with peripheral collarettes of scale densely distributed on the bilateral extensor forearms (**Figure 1**). Shave biopsy demonstrated porokeratosis consistent with DSAP (**Figure 2**) and the patient was reassured that he could safely proceed with a third cycle of treatment with TMZ.

Case Discussion

Inflammation of actinic keratoses during systemic chemotherapy, including 5-fluorouracil, cisplatin, doxorubicin, vincristine, dactinomycin, decarbazine, capecitabine, and paclitaxel, has been described [1-3],

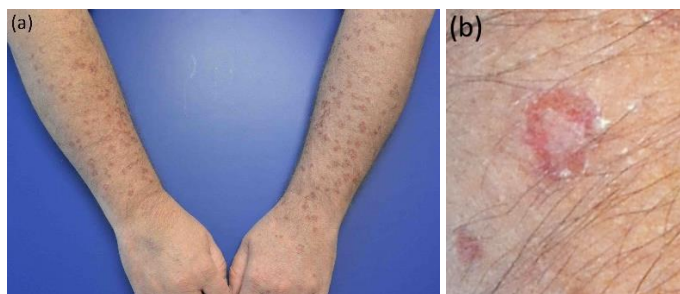


Figure 1. a) Numerous round, pink, scaly papules and plaques with peripheral scale densely distributed on the bilateral extensor forearms. **b)** Close-up view of one of the lesions, showing fine collarette of peripheral scale.

but inflammation or emergence of DSAP during chemotherapy has not been described previously.

TMZ is an oral alkylating agent indicated for the treatment of adults with glioblastoma multiforme concomitantly with radiotherapy and then as maintenance treatment [4]. Because TMZ works to methylate DNA, it has increased influence on proliferating cells, similar to most of the other types of chemotherapy agents that cause inflammation of actinic keratoses [5]. Commonly-reported side effects of TMZ include myelosuppression, nausea, vomiting, anorexia, constipation, fatigue, and headache. Dermatologic side effects, including alopecia, rash, dry skin, erythema, and pruritus, are infrequent but have also been observed [4]. Various cutaneous eruptions, including generalized maculopapular eruption, dermal hypersensitivity reaction with plaques and nodules, desquamative skin rash, and Stevens-Johnson Syndrome-Toxic Epidermal Necrolysis overlap syndrome have been reported in patients undergoing therapy with TMZ [6-9].

DSAP is an uncommon and pre-malignant cutaneous disorder that demonstrates the characteristic

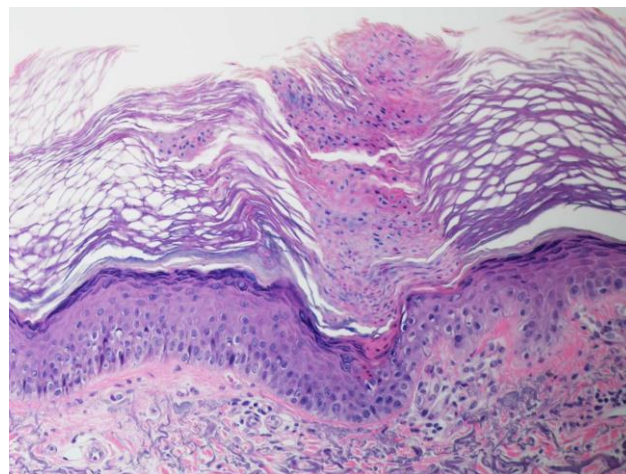


Figure 2. Column of diagonally-stacked, eosinophilic, parakeratotic cells, consistent with a cornoid lamella, shown on H&E, 40x.

cornoid lamella histologically. Estimates of the long-term malignant potential of actinic keratoses suggest a 0.1-1% risk of conversion. The long-term malignant potential of DSAP lesions has been estimated in just one series of 281 patients and was suggested to be approximately 7.5%, although other subtypes of prokeratosis, such as linear prokeratosis, may have higher rates of malignant transformation [10]. Although clinical surveillance is often sufficient for the management of asymptomatic DSAP, other treatment options include topical imiquimod, topical or systemic retinoids, cryotherapy, and surgical interventions [11].

Conclusion

Dermatologists and oncologists should be aware of this cutaneous eruption of DSAP associated with TMZ to prevent the discontinuation of effective medical therapy in cancer patients.

References

1. Johnson TM, Rapini RP, Duvic M. Inflammation of actinic keratoses from systemic chemotherapy. *J Am Acad Dermatol.* 1987;17(2 Pt 1):192-7. [PMID: 3624557].
2. Stanciu M, Aubut N, Gagne E, Thibeault MM. Capecitabine-induced inflammation of actinic keratosis: case report and literature review. *J Cutan Med Surg.* 2012;16(5):298-9. [PMID: 22971302].
3. Ali FR, Yiu ZZ, Fitzgerald D. Inflammation of actinic keratoses during paclitaxel chemotherapy. *BMJ Case Rep.* 2015;2015. [PMID: 26055606].
4. Cohen MH, Johnson JR, Pazdur R. Food and Drug Administration Drug approval summary: temozolomide plus radiation therapy for the treatment of newly diagnosed glioblastoma multiforme. *Clin Cancer Res.* 2005;11(19 Pt 1):6767-71. [PMID: 16203762].

5. Zhang J, Stevens MF, Bradshaw TD. Temozolomide: mechanisms of action, repair and resistance. *Curr Mol Pharmacol*. 2012;5(1):102-14. [PMID: 22122467].
6. Alonso-Llamazares A, Vega-Castro A, Beitia-Mazuecos JM, Mateo-Borrega B, Cardenas-Contreras R. Rapid desensitization with temozolomide in patients with delayed maculopapular rash. *J Investig Allergol Clin Immunol*. 2012;22(6):448-9. [PMID: 23101195].
7. Deluche E, Leobon S, Touraine F, Clavere P. Two cases of cutaneous drug eruption associated with temozolomide therapy for glioblastoma. *Curr Oncol*. 2014;21(6):e779-81. [PMID: 25489267].
8. Virmani P, Chung E, Thomas AA, Mellinghoff IK, Marchetti MA. Cutaneous adverse drug reaction associated with oral temozolomide presenting as dermal and subcutaneous plaques and nodules. *JAAD Case Rep*. 2015;1(5):286-8. [PMID: 27051755].
9. Pick AM, Neff WJ, Nystrom KK. Temozolomide-induced desquamative skin rash in a patient with metastatic melanoma. *Pharmacotherapy*. 2008;28(3):406-9. [PMID: 18294121].
10. Sasson M, Krain AD. Porokeratosis and cutaneous malignancy. A review. *Dermatol Surg*. 1996;22(4):339-42. [PMID: 8624658].
11. Weidner T, Illing T, Miguel D, Elsner P. Treatment of Porokeratosis: A Systematic Review. *Am J Clin Dermatol*. 2017;18(4):435-49. [PMID: 28283894].