

# UC Davis

## Dermatology Online Journal

### Title

Idiopathic perniosis of the buttocks and thighs – clinical report

### Permalink

<https://escholarship.org/uc/item/22k2t70z>

### Journal

Dermatology Online Journal, 21(1)

### Authors

Antonio, Ana Marta  
Alves, Joao  
Matos, Diogo  
[et al.](#)

### Publication Date

2015

### DOI

10.5070/D3211025427

### Copyright Information

Copyright 2015 by the author(s). This work is made available under the terms of a Creative Commons Attribution-NonCommercial-NoDerivatives License, available at <https://creativecommons.org/licenses/by-nc-nd/4.0/>

Peer reviewed

## Case Report

### Idiopathic perniosis of the buttocks and thighs – clinical report

Ana Marta António, João Alves, Diogo Matos, Ricardo Coelho

Dermatology Online Journal 21 (1): 3

Dermatovenereology Service, Hospital Garcia de Orta, Almada, Portugal

#### Correspondence:

Ana Marta António  
Hospital Garcia de Orta  
Avenida Torrado da Silva 2801-95  
Almada, Portugal  
(+351) 212 940 294  
anamartaantonio@gmail.com

---

## Abstract

Perniosis manifests as inflammatory cutaneous lesions mostly located on acral skin in association with cold and damp conditions. Perniosis of the thighs is quite uncommon and has been associated in the literature with horse riding (equestrian perniosis) or with other recreational activities with long time exposure to cold and humidity. We report a rare case of perniosis of the buttocks and thighs in a 34-year-old healthy woman without a previous history of horse riding or other high-risk activities. In this case, the use of thin and tight clothes is believed to have been enough for the development of perniosis in this susceptible subject.

**Keywords:** perniosis, chilblains, idiopathic perniosis, equestrian perniosis, thighs, buttocks.

## Introduction

Perniosis or chilblains manifests as inflammatory cutaneous lesions associated with exposure to a cold, nonfreezing, and humid climate. These inflammatory lesions present as pruritic or painful, erythematous to violaceous papules, plaques, or nodules, typically located on the extremities, dorsum of fingers and toes, nose, and ears. In severe cases, blisters and ulcerations may also occur [1, 2].

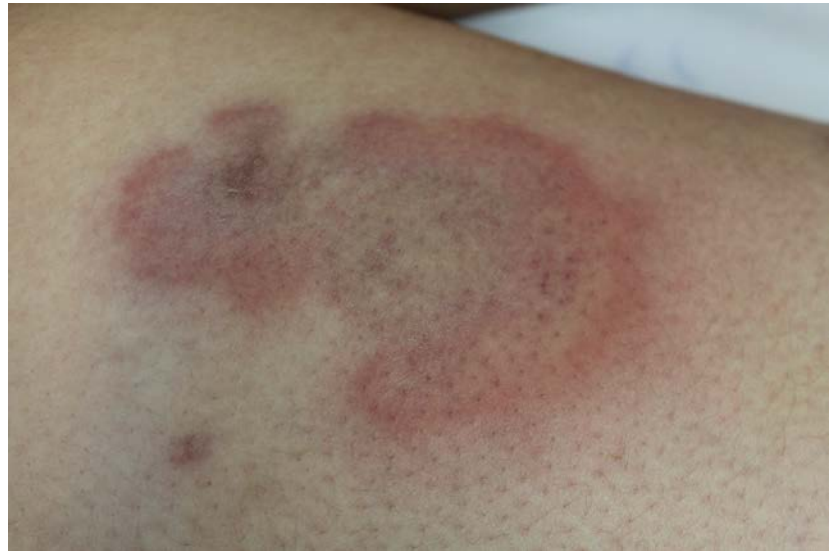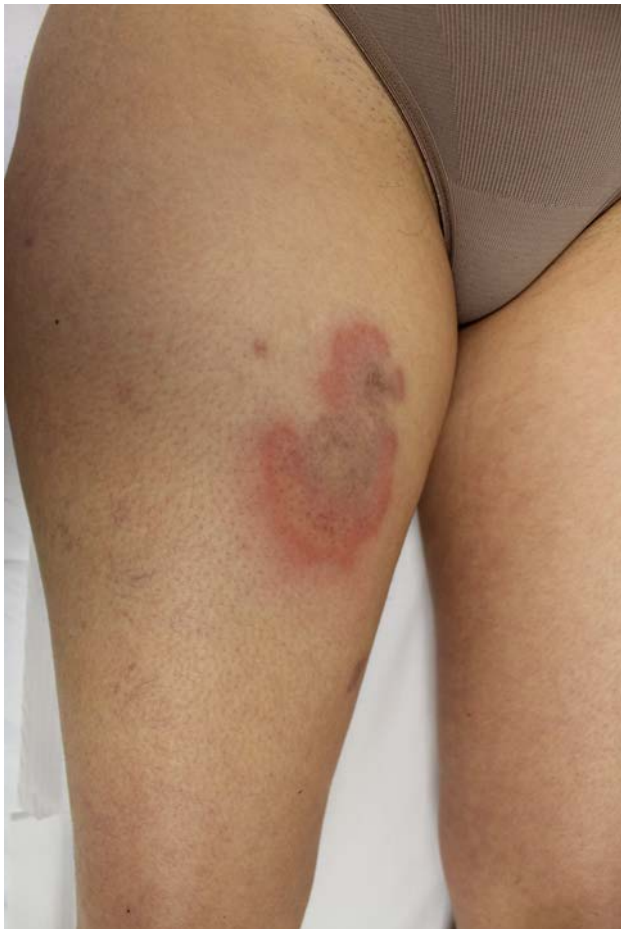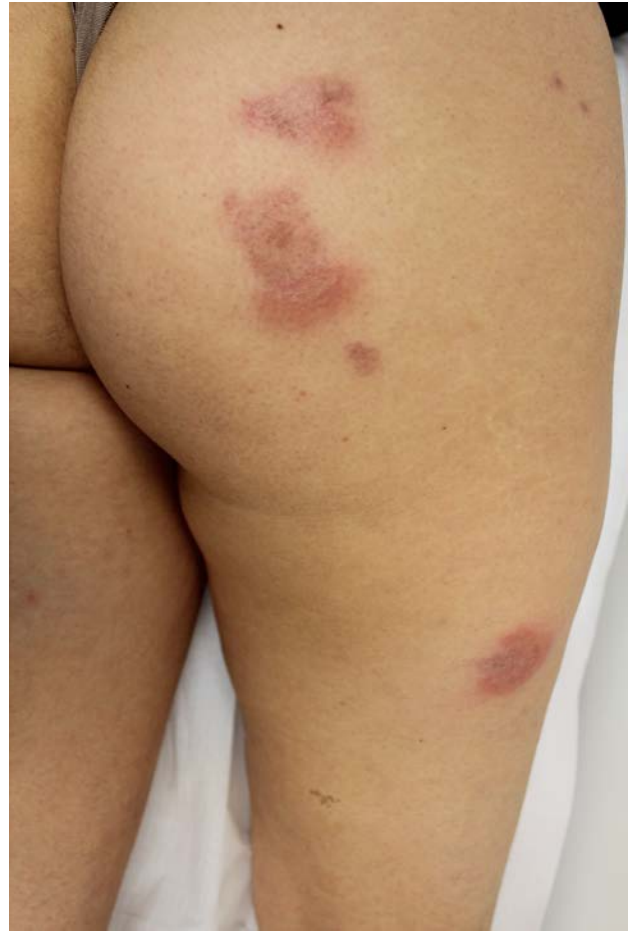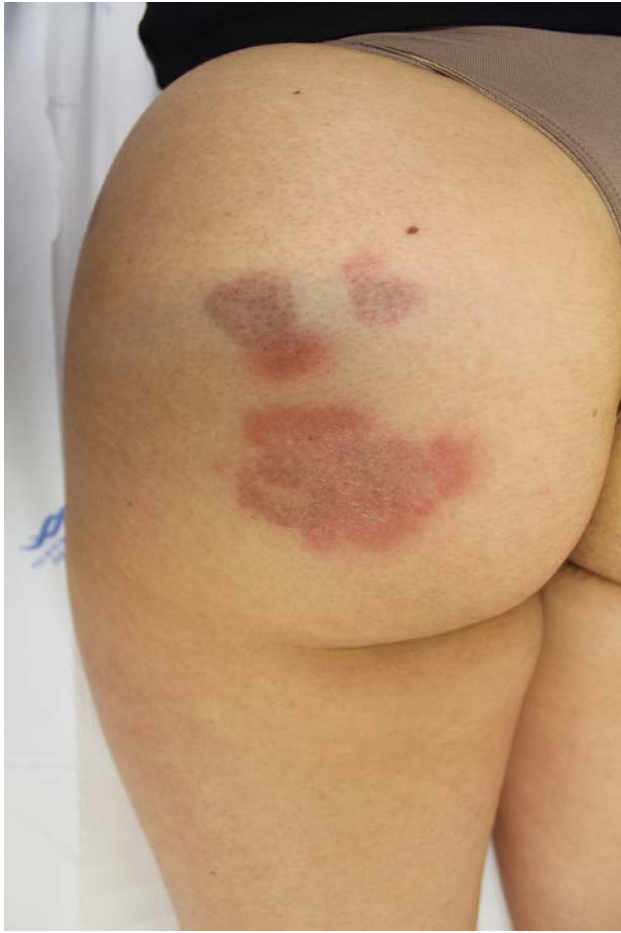One special type of perniosis has been reported to occur on the lateral thighs of female horse riders [3, 4], or on thighs and buttocks of people who are exposed to cold and damp conditions for a significant time during recreational nonequestrian activities [5]. We present a case of idiopathic perniosis of the buttocks and thighs in a young woman who was not exposed to the previously mentioned triggering factors.

## Case synopsis

A 34-year-old woman came to our clinic in January because of painful cutaneous lesions of the buttocks and thighs, which appeared one-week prior. Physical examination revealed several erythrocyanotic papules and plaques located bilaterally on the buttocks (Figure 1 and 2) and thighs (Figure 3 and 4), with dimensions ranging between 1 and 10 cm (long axis). Most plaques exhibited an annular shape, an erythematous distinct edge, and a pale cyanotic center (Figure 4).

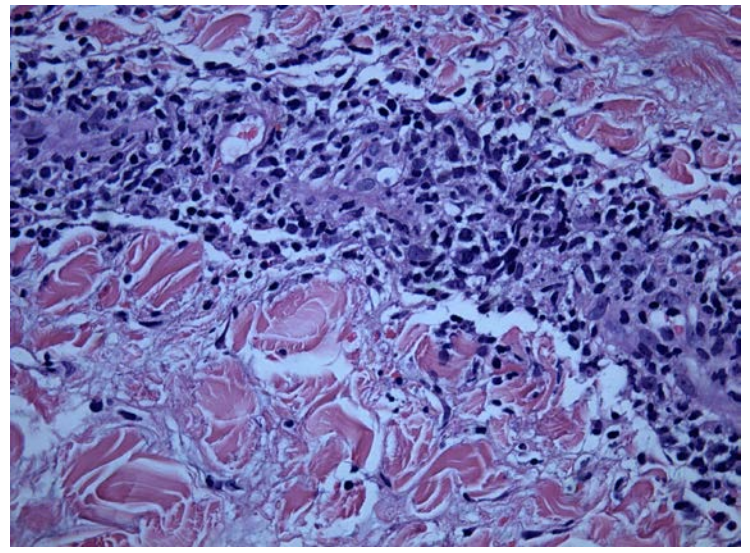
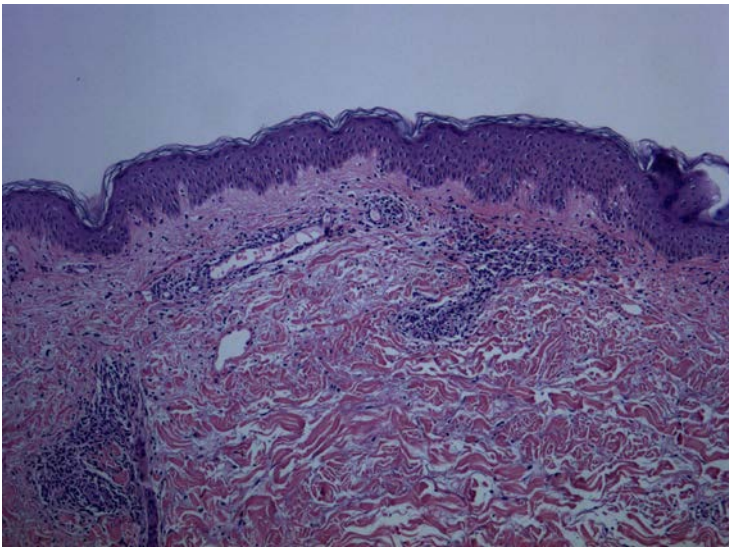
The patient had a previous recurrent six year history of chronic idiopathic chilblains of the fingers and toes during winter. She was a non smoker and her medical and family history was unremarkable. She denied any chronic or occasional medication. She had a normal body mass index. As in previous episodes of finger and toe chilblains, there were no other accompanying signs or symptoms such as fever, arthralgia, Raynaud's phenomenon, or other cutaneous lesions. She was a housekeeper and

worked at home and sometimes outside in the garden in which she was exposed to temperatures around 6-13°C on the coldest days. She usually wore only thin and tight-fitting leggings with short sweaters even during winter. There were no other identified triggering factors. Laboratory analyses were negative, including autoimmunity markers (antinuclear antibody-ANA, antibodies to the extractable nuclear antigen-ENA, anti-ds-DNA antibodies, and antiphospholipid antibodies), rheumatoid factor, complement, cryoglobulins, cold agglutinins, syphilis, and antibodies to HIV and hepatitis B and C.



**Figure 1 and 2.** Erythrocyanotic papules and plaques located bilaterally on the buttocks

**Figure 3 and 4.** Erythrocyanotic plaque located on the right thigh, with an annular shape, a erythematous distinct edge and a cyanotic center.



**Figure 5.** Papillary dermal edema and perivascular inflammatory lymphocytic infiltrate (H&E x100) **Figure 6.** Fibrinoid necrosis and lymphocytic vasculitis (H&E x400)

Skin biopsy was performed and revealed papillary dermal edema and perivascular inflammatory lymphocytic infiltrate (Figure 5) with some focus of fibrinoid necrosis and lymphocytic vasculitis (Figure 6). Given the history, clinical examination, histological features and negative laboratory investigation, the diagnosis of idiopathic perniosis of thighs and buttocks was deduced. The patient was advised to wear warm and loose clothes; extended release nifedipine, 30mg once daily, and betamethasone dipropionate ointment were prescribed. The lesions improved and almost disappeared after 10 days of treatment.

## Discussion

Perniosis of the thighs and buttocks was first described by Haxthausen as “erythrocyanosis crurum puellaris” [6] and later by Beacham *et al.* in 1980, who defined equestrian panniculitis associated with female horse riders [3]. Since then many reports have been published about equestrian perniosis [4,6,7]. In this recreational activity, exposure of thighs to cold, associated with tight riding clothes contribute to deficient blood supply and development of perniosis [8]. Other clinical report described the same lesions in four men and one woman who were exposed to cold and damp conditions for many hours, following river crossings and motorcycling on a rainy day, respectively [5]. As far as we are aware, there are no individual cases published in the English language reporting idiopathic thigh and buttock chilblains without evidence of these extreme triggering factors. However, a previous clinical report described two young girls who developed hip perniosis during winter related to wearing tight-fitting jeans with a low waistband [9]. Similarly, in our case, the use of thin and tight clothing was the only identified trigger for the development of thigh and buttock chilblains. As with other types of perniosis [10], nifedipine seems to contribute to the resolution of lesions and complaints.

## Conclusion

This case is reported because of its rarity and in support of the assertion that inappropriate clothing during cold months could be associated with the development of perniosis of the thighs in some predisposed individuals.

## References

1. Page EH, Shear NH. Temperature-dependent skin disorders. *J Am Acad Dermatol.* 1988;18(5 Pt 1):1003-19. [PMID:3290279]
2. Goette DK. Chilblains (perniosis). *J Am Acad Dermatol.* 1990;23(2 Pt 1): 257-62. [PMID:2212122]
3. Beacham BE, Cooper PH, Buchanan CS, Weary PE. Equestrian cold panniculitis in women. *Arch Dermatol.* 1980;116(9):1025-7. [PMID:7191239]
4. Yang AY, Schwartz L, Divers AK, Sternberg L, Lee JB. Equestrian chilblain: another outdoor recreational hazard. *J Cutan Pathol.* 2013;40(5):485-90. [PMID:23432072]
5. Price RD, Murdoch DR. Perniosis (chilblains) of the thigh: report of five cases, including four following river crossings. *High Alt Med Biol.* 2001;2(4):535-8. [PMID:11809094]
6. De Silva BD, McLaren K, Doherty VR. Equestrian perniosis associated with cold agglutinins: a novel finding. *Clin Exp Dermatol.* 2000;25(4):285-8. [PMID:10971486]
7. Stewart CL, Adler DJ, Jacobson A, Brod BA, Shinohara MM, Seykora JT, Elenitsas R, Rosenbach M. Equestrian perniosis: a report of 2 cases and review of the literature. *Am J Dermatopathol.* 2013;35(2):237-40. [PMID:22534636]
8. Pekki A, Sauni R, Vaalasti A, Toivio P, Huotari-Ovara R, Hasan T. Cold panniculitis in Finnish horse riders. *Acta Derm Venereol.* 2011;91(4):463-4. [PMID:21547345]

9. Weismann K, Larsen FG. Pernio of the hips in young girls wearing tight-fitting jeans with a low waistband. *Acta Derm Venereol.* 2006;86(6):558-9. [PMID:17106612]
10. Rustin MH, Newton JA, Smith NP, Dowd PM. The treatment of chilblains with nifedipine: the results of a pilot study, a double blind placebo-controlled randomized study and long term open trial. *Br J Dermatol.* 1989;120(2):267-75. [PMID:2647123]