

Case presentation

Angiolymphoid hyperplasia with eosinophilia

Joshua A Farhadian MD, Marianna Shvartsbeyn MD, Shane A Meehan MD, and Richard W Urbanek MD

Dermatology Online Journal 21 (12): 5

New York University School of Medicine

Special Guest Editor: Nicholas A Soter MD

Abstract

Angiolymphoid hyperplasia with eosinophilia is a rare, benign, vascular proliferation that presents as dome-shaped, light-pink-to-red-brown papules or subcutaneous masses that lack distinguishing surface changes. The condition typically presents as a single lesion or multiple lesions that involve contiguous areas. The pathogenesis is poorly understood. Angiolymphoid hyperplasia with eosinophilia has been associated with antecedent trauma, T-cell proliferation, infection, and hormone imbalance. This report details a case of widespread angiolymphoid hyperplasia with eosinophilia that flared while the patient was pregnant.

Case synopsis

History: A 39-year-old woman presented for evaluation of pruritic, erythematous papules. The lesions first appeared approximately six years ago on her right upper back. Over the years, they increased in number and size and spread to involve the chest, neck, abdomen, arms, and legs. The rate of development of new papules accelerated four years ago during her third pregnancy. She was previously treated with intralesional triamcinolone acetonide 2.5 mg/mL, pulsed-dye laser, and cetirizine 10 mg daily, all resulting in no improvement.

Past medical history and family history were not contributory. She denied taking any medications. Punch biopsies were taken from representative chronic lesions on the right anterior forearm and middle upper back.

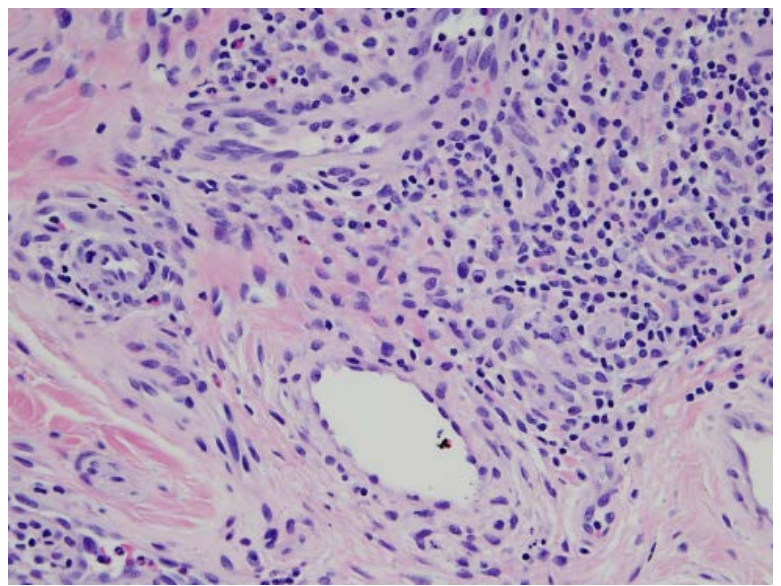
Physical examination: On the neck, chest, abdomen, arms, and legs were widespread, smooth, erythematous papules with excoriations.

Laboratory data: None

Histopathology: There is a circumscribed proliferation of blood vessels within the reticular dermis. The vessel walls are slightly thickened and are lined by plump endothelial cells. There is an accompanying infiltrate of lymphocytes, eosinophils, and mast cells.

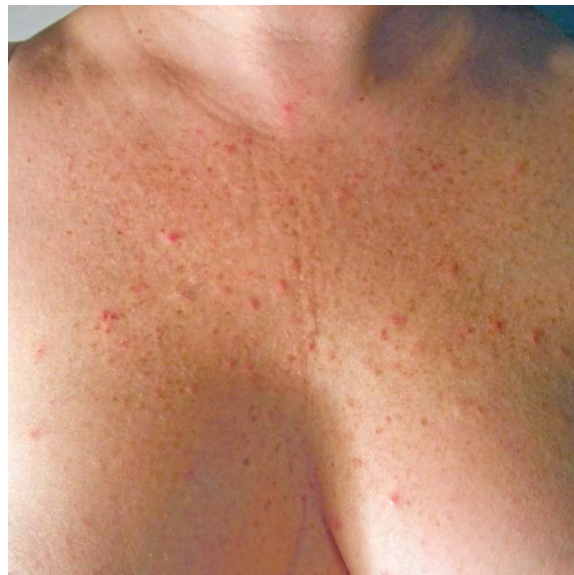

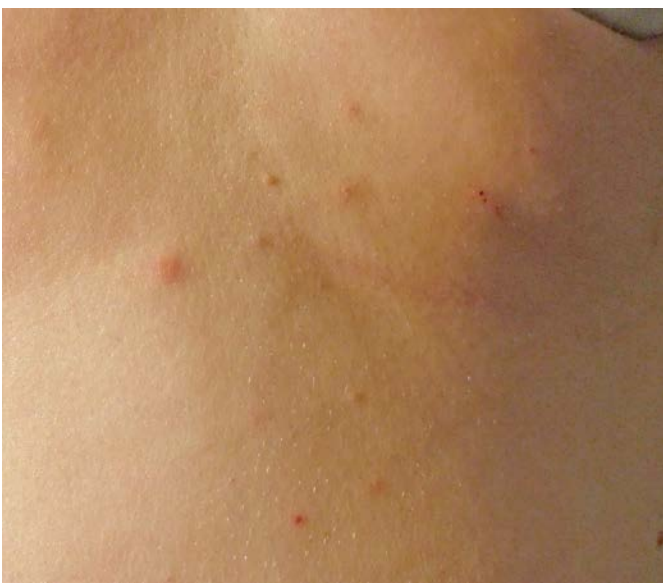Figure 1. Multiple erythematous papules on chest



Figures 2. Erythematous papules on back Figure 3. Proliferation of blood vessels lined by plump endothelial cells

Discussion

Diagnosis: Angiolympoid hyperplasia with eosinophilia

Comment: In 1969, Wells and Whimster reported the first case of angiolympoid hyperplasia with eosinophilia (ALHE) [1]. ALHE is a rare and benign vascular proliferation that presents as dome-shaped, light-pink-to-red-brown papules or subcutaneous masses that lack distinguishing surface changes. Typical cutaneous lesions vary from asymptomatic to pruritic, painful, and/or pulsatile. Wells and Whimster initially considered ALHE to be a late stage of Kimura disease. However, it is now accepted that these two conditions are separate entities. Unlike ALHE, Kimura's disease is associated with lymphadenopathy and an elevated serum immunoglobulin E level [2]. In Kimura disease, peripheral eosinophilia is always present but only occurs in 20% of patients with ALHE [3, 4].

ALHE appears as a single lesion in 80% of patients and as multiple lesions in 20%. Multiple lesions tend to merge and form a plaque in a grapelike cluster. Sites of involvement are usually contiguous and are most often located on the head and neck; the ear and forehead are involved in 50% of patients [4]. There is one reported case of a 37-year-old-Cantonese man who developed disseminated ALHE on his head, trunk, and extremities [5]. Similar to this patient, our patient also presented with widespread disease that involved her neck, trunk, and extremities. Her head was relatively spared.

The cause of ALHE is not completely understood. Approximately 10% of cases are preceded by trauma, which suggests a reactive phenomenon [4, 6]. However, more recent data suggest that it may be a primary lymphoproliferative process, as evidenced by findings of T-cell gene rearrangements, although PCR analysis has not shown monoclonality in all cases [7, 8]. Infection (human T-lymphotropic virus or human herpesvirus-8) and hormonal background also have been implicated [9]. There are six reported cases of patients who developed ALHE during the first trimester of pregnancy [4, 9-11]. Four of these patients had single nodules and two had multiple lesions. ALH also has been reported in the post-partum period [11]. Additionally, there is one reported case of a patient who, similar to our patient, developed multiple, asymptomatic lesions over several years that then increased in size and number during her pregnancy [12]. In this patient, estrogen and progesterone receptors were overexpressed in lesional skin. Hormone receptor upregulation also was observed in the lesional skin of a patient who developed ALHE that resolved after discontinuing oral contraception [12]. Our patient reported an increase in the size and number of her lesions throughout her third pregnancy, which suggests possible hormone involvement in her as well.

ALHE is a benign condition and not associated with internal disease. Thus, additional evaluation is not necessary. Rarely do lesions regress spontaneously. There is currently no standard of care. Case reports and small case series have demonstrated efficacy with topical, intralesional, and oral glucocorticoids. In addition, imiquimod, indomethacin, pentoxifylline, vinblastine, systemic retinoids, intralesional interferon alpha-2a, intravenous immunoglobulin, surgery (including Mohs micrographic surgery), sclerotherapy, radiotherapy, electrodesiccation, and laser treatments (carbon dioxide, neodymium:yttrium-aluminum-garnet, and pulsed-dye laser) have been used. It is worth noting that our patient responded poorly to both intralesional triamcinolone acetonide and pulsed-dye laser. To date, there are no studies or case reports that comment on the role of estrogen antagonists or selective estrogen receptor modulators in ALHE. However, this could be a potential therapeutic option for patients who have hormone receptor overexpression in lesional skin and is worth further investigation.

References

1. Wells GC, Whimster IW. Subcutaneous angiolymphoid hyperplasia with eosinophilia. *Br J Dermatol* 1969; 81: 1
2. Tabata H, et al. Kimura's disease with marked proliferation of HLA-DR+CD4+ T cells in the skin, lymph node and peripheral blood. *Dermatology* 1992; 184: 145
3. Chun SI, Ji HG. Kimura's disease and angiolymphoid hyperplasia with eosinophilia: clinical and histopathologic differences. *J Am Acad Dermatol* 1992; 27: 954
4. Olsen TG, Helwig EB. Angiolymphoid hyperplasia with eosinophilia: a clinicopathologic study of 116 patients. *J Am Acad Dermatol* 1985; 12: 781
5. Zhang GY, et al. Disseminated angiolymphoid hyperplasia with eosinophilia: a case report. *Cutis* 2003; 72: 323
6. Stewart N, et al. Angiolymphoid hyperplasia with eosinophilia occurring after venipuncture trauma. *J Dermatol* 2013; 40: 393
7. Gonzalez-Cuyar LF, et al. Angiolymphoid hyperplasia with eosinophilia developing in a patient with history of peripheral T-cell lymphoma: evidence for multicentric T-cell lymphoproliferative process. *Diagn Pathol* 2008; 3: 22
8. Jang KA, et al. Polymerase chain reaction (PCR) for human herpesvirus 8 and heteroduplex PCR for clonality assessment in angiolymphoid hyperplasia with eosinophilia and Kimura's disease. *J Cutan Pathol* 2001; 28: 363
9. Hollo P, et al. Angiolymphoid hyperplasia with eosinophilia in pregnancy. *J Eur Acad Dermatol Venereol* 2005; 19: 645
10. Zarrin-Khameh N, et al. Angiolymphoid hyperplasia with eosinophilia associated with pregnancy: a case report and review of the literature. *Arch Pathol Lab Med* 2005; 129: 1168
11. Marcum CB, et al. Profound proliferating angiolymphoid hyperplasia with eosinophilia of pregnancy mimicking angiosarcoma. *Cutis* 2011; 88: 122
12. Moy RL, et al. Estrogen receptors and the response to sex hormones in angiolymphoid hyperplasia with eosinophilia. *Arch Dermatol* 1992; 128: 825