

Original

Prevalence of osteoma cutis in the maxillofacial region and classification of its radiographic pattern in cone beam CT

Dermatology Online Journal 22 (1): 2

Yaser Safi¹, Solmaz Valizadeh¹, Zahra Vasegh¹, Mohammad Mahdi Aghdasi¹, Nafiseh Shamloo², Zeynab Azizi¹

¹Oral and Maxillofacial Radiology Department, Shahid Beheshti University of Medical Science, Dental Faculty, Tehran, Iran

²Pathology Department, Shahid Beheshti University of Medical Science, Dental School, Tehran, Iran

Correspondence:

Zeynab Azizi
Shahid Beheshti University of Medical Sciences, Dental Faculty
Velenjak, Evin, Tehran, Iran
09124039068
02122967307
dr_azizi_mp@yahoo.com

Abstract

Background: Osteoma cutis is a rare soft tissue ossification of cutaneous tissue and may be primary or secondary. In the majority of cases it is clinically asymptomatic and may be detected incidentally on radiographic examination. Cone beam computed tomography (CBCT) can be of great assistance in the detection of this asymptomatic lesion.

Objectives: In this retrospective study, the prevalence and different radiographic appearance of osteoma cutis was evaluated.

Materials and Methods: A total of 6,500 CBCT images were evaluated for the presence of osteoma cutis. Ectopic existence of calcified tissue within the soft tissue of the dermis or epidermis that was incompatible with the calcification of other anatomic structures or soft tissue calcifications was considered to be osteoma cutis. Accordingly, the detected patterns were divided into four distinct groups: (1) a single nodule, (2) plate-like lesion, (3) single or multiple depth lesion(s), trans-epidermal, and (4) multiple, disseminated lesions of various sizes known as multiple miliary. The data were evaluated in terms of prevalence and variations. The frequency, total prevalence, percentage and the prevalence of different radiographic forms of this lesion were calculated.

Results: One hundred and forty eight (2.27%) cases of 6,500 evaluated tomograms had osteoma cutis. Of these, 5 (0.07%) were in the form of a single nodule, 4 (0.06%) were single, plate-like lesions, 7 (0.1%) were multiple plate-like lesions, 2 (0.03%) were in the form of a deep thread-like lesion, and 130 (2%) presented as multiple disseminated lesions.

Conclusion: According to the radiographic views, osteoma cutis may be categorized into single nodular, single or multiple plate-like, deep, and multiple disseminated forms. Of the mentioned radiographic patterns, the multiple disseminated form (miliary) had a higher prevalence in our study. CBCT images enable accurate evaluation of the nature and frequency of osteoma cutis.

Keywords: Cone beam computed tomography, Osteoma cutis, Prevalence

Introduction

Osteoma cutis is a rare soft tissue ossification in the skin or cutaneous tissue also known as focal bone formation within the dermis [1]. It also refers to the ectopic presence of calcification within the dermis or epidermis. These lesions are benign with limited and non-invasive growth [2]. The condition neither progresses nor recedes within the soft tissue [3]. It may be seen primarily with no related cutaneous lesion. Developmentally, the mesenchymal cells secrete a matrix that becomes calcified and differentiates into normal but ectopic bone. This is seen in some diseases such as Albright syndrome. The secondary form is often seen after cutaneous or metabolic changes secondary to a primary condition such as scleroderma, trauma, scar, and specific or nonspecific inflammatory processes [4]. About 85% of detected lesions are secondary and appear following conditions with a long duration, such as acne, chronic inflammatory dermatoses, or scars [1]. Moreover, some researchers associate alendronate intake with osteoma cutis formation in the skin [5]. The majority of osteoma cutis lesions are clinically asymptomatic [6]. Sometimes they are seen as skin-colored dome-shaped papules [3] or yellowish-white areas on the skin with a stone like resistance to needle insertion [1]. The commonly involved sites include the face, scalp, digits, and subangular areas [2]. The face is the most commonly involved site, particularly the cheeks and lips. In the oral cavity the lesions are known as osteoma mucosae or osseous chistoma. The tongue is the most common intraoral site with single or multiple lesions. Radiographically, these appear as smoothly outlined radiopaque regions with a homogenous internal structure, which usually has a radiolucent center formed of normal fatty marrow [1].

Cone Beam Computed Tomography (CBCT) was invented primarily for angiography in the early 1980s [7] and was introduced to dentistry by 1990 [8]. CBCT uses a cone-shape X-ray beam instead of fan-shape beam, which in turn produces a volumetric data set, which is later reconstructed and reformatted to multiplanar and three-dimensional images [1]. Currently, CBCT has various applications for the assessment of the hard tissue of the maxillofacial region, including three-dimensional volumetric images of the temporomandibular joint, airway assessments, bone graft assessment, lip, cleft palate, and craniofacial surgery assessments, impacted tooth assessment, root resorption evaluation, and estimation of impacted canine eruption pathway. In addition, one can use this technique for treatment planning for implants [9-13]. CBCT has two main advantages compared to 2D radiographic techniques; 1. Elimination of geometric distortion and 2. lessening of structural superimpositions [14]. Moreover, CBCT has a lower radiation dose (ranges between 29 up to 577 μ SV) compared with CT scans that have radiation exposures approximately 2000 μ SV [12]. This reduction in radiation is a great advantage especially in children and young adults [15]. However, it has some disadvantage and limitations; the FOV (field of view) is smaller in CBCT units than in CT, which leads to limitation in large area scanning. More importantly, it does not have the ability to differentiate between different soft tissues because it does not produce images with contrast resolution. Basically, it is recommended for hard and dental tissue evaluation in the maxillofacial area [8].

Despite all of the advantages of this new diagnostic method, most clinicians are not familiar with the interpretation of this technique [8]. Some studies have reported accidental findings on CBCT images. However, further studies are required to assess the type and frequency of incidental findings for more accurate diagnosis and treatment [16]. Soft tissue calcification has also been reported as an incidental finding in a few studies [7, 14, 15, 17-19]; some of these incidental findings have been osteoma cutis. Some studies reported different cases with different radiographic patterns [2, 3, 5, 6, 16, 20-26].

Objective

Considering the absence of adequate data about the prevalence and variability of the radiographic patterns of osteoma cutis, this study aimed to assess the prevalence and radiographic patterns of this lesion as an incidental finding on CBCT images.

Materials and Methods

A total of 6,500 CBCT images taken by Soredex Scanora 3D device (Helsinki, Finland) from three oral and maxillofacial radiology were evaluated. The selected CBCT images had been obtained in the past two years for pre-implantation assessment. Images had been obtained with exposure settings of 10*7.5 cm field of view (FOV), 13 mA, and 90 kVp. Images were evaluated by two oral and maxillofacial radiologists. Images with optimal quality, which had an FOV covering the entire anterior facial soft tissue from the inferior border of the chin to the mid-face and cheeks were selected. CBCT images of patients were evaluated for the presence of osteoma cutis. The evaluation was performed on the axial, coronal, and sagittal planes of CBCT as well as the reconstructed 3D images and Ray-Sum and Maximum Intensity Projection (MIP) views. Cases with ectopic calcified tissue within dermis or epidermis, which was not compatible with calcification of any other anatomic structure or other soft tissue calcifications were diagnosed as osteoma cutis [14]. Four radiographic patterns of detected osteoma cutis cases were catalogued.

Single nodular shaped lesion [2]: A single, nodule shape lesion with variable dimensions in dermis (Figure 1)

Plate-like lesion [3, 22-24]: An extensive, plaque-like area in dermis (Figure 2)

Trans-epidermal lesion [2]: Single or multiple deep lesion(s) (Figure 3)

Multiple miliary [6,16, 21,25, 26]: Multiple, disseminated lesions with variable dimensions (Figure 4)

The data were evaluated in terms of prevalence and variations. The frequency, total prevalence percentage and the prevalence of different forms of this lesion were calculated.

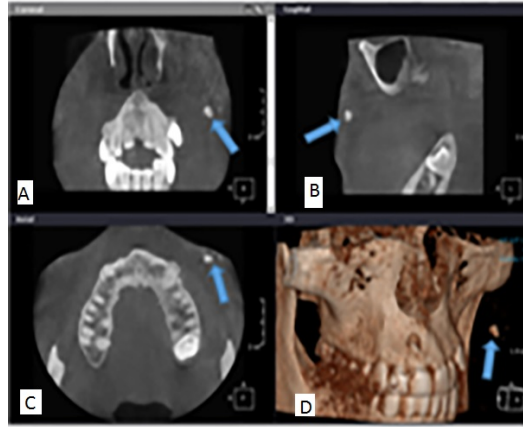


Figure 1. Nodule-shape osteoma cutis measuring 3x6mm in the cheek. The arrows points to the radiopaque lesion in the coronal (A), sagittal (B) and axial (C) plane as well as in the 3D reconstructed image (D), which is diagnosed radiographically as an osteoma cutis.

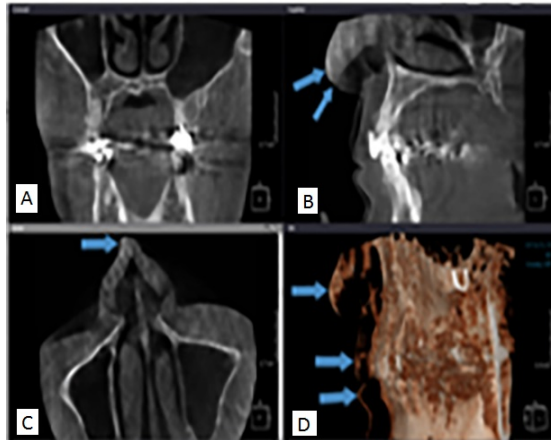


Figure 2. Plate-like osteoma cutis expanded in the form of a radiopaque plate in the nose and lips area. The arrow points to the lesion, which is detectable as a radiopaque line in the sagittal (B) and axial (C) plane as well as in the 3D reconstructed image (D).

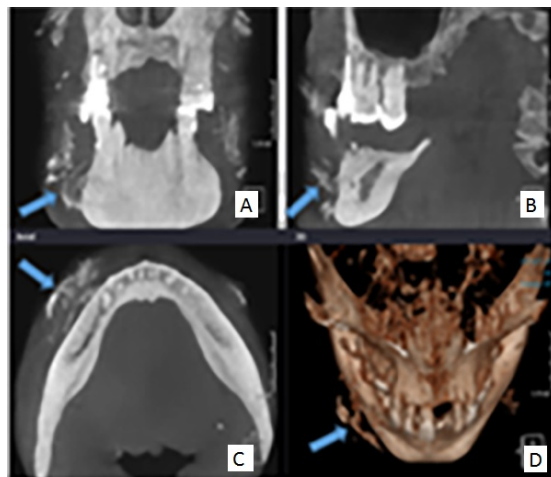


Figure 3. Trans-epidermal lesion. The arrows point to multiple, thread-like radiopaque lesions in the coronal (A), sagittal (B) and axial (C) plane as well as in the 3D reconstructed image (D) placed deeply from the skin toward the mandibular bone surface.

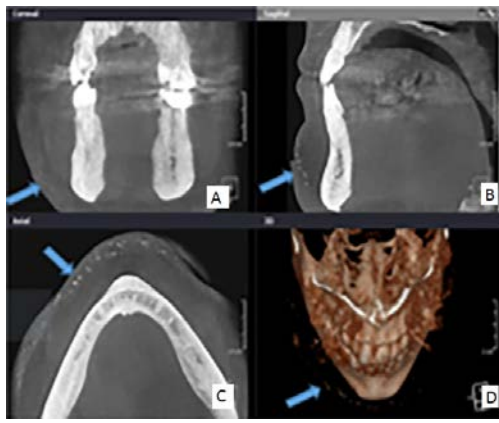


Figure 4. Miliary lesion: Multiple, small detectable radiopaque lesions in the skin of the chin area and lateral side of the face. The arrow points to the lesions in the coronal (A), sagittal (B) and axial (C) plane as well as in the 3D reconstructed image (D).

Results

In this retrospective study, of the total of 6,500 CBCT scans evaluated, osteoma cutis was diagnosed in 148 (2.27%) cases. Nodule shape, single and multiple plate-like, transepidermal, and multiple military type were reported in 5 (0.07%), 11(0.16%), 4 (0.06%) for single and 7 (0.1%) for multiple), 3(0.02%), and 130 (2%) cases, respectively. The frequency and prevalence percentage of each form are presented in Table 1.

Table 1. The frequency distribution and prevalence percentage of different types of osteoma cutis in CBCT images

Type of lesion	Frequency (prevalence%)		Total frequency (prevalence%)
Nodule-shape	5(3.3%)		5(3.3%)
Plate-like	single	4(2.7%)	11(7.4%)
	multiple	7(4.7%)	
Trans-epidermal	Thread like	2(1.3%)	2(1.3%)
	Plaque like	-----	
	Single	-----	
Miliary	130(87.8%)		130(87.8%)
Total frequency (prevalence%)	148(100%)		148(100%)

Discussion

The evaluation of the CBCT images in axial, coronal and sagittal planes and 3D reconstruction in different formats such as Ray-Sum and MIP, showed a total of 148 (2.27%) cases of osteoma cutis in the 6,500 reviewed CBCT scans. Reports concerning osteoma cutis are mostly case reports and many different radiographic patterns have been reported [8, 22-26]. Some others have demonstrated accidental detection [2,3,9,14,17,18]. This study is the first of its kind to report a definitive classification for radiographic patterns of osteoma cutis. Moreover, no study to the authors knowledge has yet assessed the accurate prevalence rate of osteoma cutis in any population. According to the classification, osteoma cutis can be categorized into four groups:

1. Type I : Single nodule-shaped lesion measuring 2-6 mm. In a study by Duarte [2] this form of lesion measured 2-5 mm, in the same range of this study.

2. Type II: Plate-like lesion in the form of a plaque within the dermis or epidermis. Aneiros-Fernandez [3], Vashi [22], Haro [23], and Douri [24] have also reported some cases with a plate-like appearance. This type can also be seen in the form of multiple plaques [2]. Single and multiple plate-like lesions were also detected in this study. Multiple plate-like lesions were more frequent than the single plate-like lesions.
3. Type III: Trans-epidermal osteoma cutis, which was reported also by Duarte [2]. This type of lesion is often located deeper in the tissue than other types and can be nodular, plate-shape, or thread-like. In this study, only one case of thread-like osteoma cutis was found extending deeply from the skin surface to the mandibular bone.
4. Type IV: Miliary form reported by Bouraoui [16], Bergonse [21], Baskan [25], and Myllyla [26]. As seen in the current study, the miliary form appears to have a higher prevalence than the other forms.

It can be readily deduced that CBCT enables more accurate detection of lesions such as osteoma cutis rather than conventional techniques and provides comprehensive information for accurate diagnosis and reassurance of patients.

Conclusions

In CBCT evaluations, four radiographic patterns may be considered for osteoma cutis. Of the four types of nodule shape, plaque-like, trans-epidermal, and multiple miliary, the latter form had a higher prevalence in our population.

Acknowledgements: We would like to thank Dr. Laleh Alim Marvasti for editing helping in this research.

References

1. White SC, Pharoah MJ. Oral radiology principles and interpretation. 7th ed. St. Louis: Mosby; 2014 . Chapter28, soft tissue calcification and ossification; p. 536,7.
2. Duarte IGL. Multiple injuries of osteoma skin in the face: therapeutical least invasive in patients with acne sequel –case report. An. Bras. Dermatol. 2010; 85(5). [PMID 21152797]
3. Aneiros-FernandezJ, H Husein-ElAhmed , J Orgaz-Molina , F O'ValleRavassa , S Arias-Santiago . Unknown: A man with infiltrated and indurated plaque on the forehead. Dermatology Online Journal 2010;16 (6): 12. [PMID 20579467]
4. Fazeli P, Harvell J, Jacobs MB. Osteomacutis(cutaneous ossification). West J Med. 1999; 17:243-5. PMID1305869
5. Riahi RR¹, Cohen PR. Multiple miliary osteoma cutis of the face after initiation of alendronate therapy for osteoporosis. Skinmed. 2011 Jul-Aug; 9(4):258-9. [PMID: 21980713]
6. Thielen AM et al. Multiple cutaneous osteomas of the face associated with chronic inflammatory acne. J Eur Acad Dermatol Venereol. 2006; 20: 321-6. [PMID: 16503897]
7. Caglayan F, Tozoglu U. Incidental findings in the maxillofacial region detected by cone beam CT. DiagnInterv Radiol2012;18:159-63. [PMID 21960135]
8. Oberoi S, Chigurupati R, Gill P, Hoffman WY, Vargervik K. Volumetric assessment of secondary alveolar bone grafting using cone beam computed tomography. Cleft Palate Craniofac J 2009;46:503-11. [PMID 19929098]
9. Oberoi S, Gill P, Chigurupati R, Hoffman WY, Hatcher D. C, Vargervik K. Three-dimensional assessment of the eruption path of the canine in individuals with bone-grafted alveolar clefts using cone beam computed tomography. Cleft Palate Craniofac J2010;47:507-12. [PMID 20184425]
10. Oberoi S, KnuettelS. Three-dimensional assessment of impacted canines and root resorption using cone beam computed tomography. Oral Surg Oral Med Oral Pathol Oral Radiol Endod 2011;113:260-7. [PMID: 22677744]
11. Hatcher DC. Cone beam computed tomography: craniofacial and airway analysis. Dent Clin North Am2012; 56:343-57. [PMID: 22480807]
12. Cheung T, Oberoi S. Three dimensional assessment of the pharyngeal airway in indivisuals with non-syndromic cleft lip and palate. Plos One 2012; 7:1-5. [PMID: 22952677]
13. Allareddy V, Vincent SD, Hellstein JW, Qian F, Smoker WRK, Ruprecht A. Incidental Findings on Cone Beam Computed Tomography Images. Hindawi Publishing Corporation International Journal of Dentistry Volume 2012, Article ID 871532, 9 pages. [PMID: 23304148]
14. Pazera P, Bornstein MM, Pazera A, Sendi P, Katsaros C. Incidental maxillary sinus findings in orthodontic patients: A radiographic analysis using cone-beam computed tomography (CBCT). Orthod Craniofac Res 2011; 14: 17-24. [PMID: 21205165]
15. Rheem S, Nielsen IL, Oberoi S. Incidental findings in the maxillofacial region identified on cone-beam computed tomography scans. J Orthod Res 2013;1(1): 33-9.
16. Bouraoui S, Mlika M, Kort R, Cherif F, Lahmar A, Sabeh M. Miliary osteoma cutis of the face. J Dermatol Case Rep. Dec 12, 2011; 5(4): 77–81. [PMID: 22408708]

17. Pette GA, Norkin FJ, Ganeles J, Hardigan P, Lask E, Zfaz S, *et al.* Incidental findings from a retrospective study of 318 cone beam computed tomography consultation reports. *Int J Oral Maxillofac Implants* 2012; 27: 595-602. [PMID: 22616053]
18. Cha JY, Mah J, Sinclair P. Incidental findings in the maxillofacial area with 3-dimensional cone-beam imaging. *Am J Orthodont Dentofacial Orthopedics* 2007;132:7-13. [PMID: 17628245]
19. Edwards R, Alsufyani N, Heo G, Flores-Mir C. The frequency and nature of incidental findings in large-field cone beam computed tomography scans of an orthodontic sample. *Prog Orthod.* 2014 Jun 11; 15(1):37. [PMID: 25033888]
20. Cohen PR, Tschen JA, Schulze KE, Martinelli PT, Nelson BR. Dermal plaques of the face and scalp. Plate-like osteoma cutis. *Arch Dermatol.* 2007 Jan; 143(1):109-14. [PMID: 17224551]
21. Bergonse FN, Nico MM, Kavamura MI, Sotto MN. Miliary osteoma of the face: a report of 4 cases and review of the literature. *Cutis.* 2002 May; 69(5):383-6. [PMID: 12041819]
22. Vashi N, Chu J, Patel R. Acquired plate-like osteoma cutis. *Dermatology Online Journal* 17 (10): 1. [PMID: 22031627]
23. Haro R, Revelles JM, Angulo J, FariñaMdel C, Martín L, Requena L. Plaque-like osteoma cutis with transepidermal elimination. *J CutanPathol.* 2009;36(5):591-3. [PMID: 19476531]
24. Douri T, Shawaf AZ. Plate-like cutaneous osteoma on the scalp. *Dermatol Online J.* 2006 May 30; 12(4):17. [PMID: 17083872]
25. Baskan EB, Turan H, Tunali S, Toker SC, Adim SB, Bolca N. Miliary osteoma cutis of the face: treatment with the needle microincision-extirpation method. *J Dermatolog Treat.* 2007;18(4):252-4. [PMID: 17671887]
26. Myllylä RM, Haapasaari KM, Palatsi R, Germain-Lee EL, Hägg PM, Ignatius J, Tuukkanen J. Multiple military osteoma cutis is a distinct disease entity: four case reports and review of the literature. *Br J Dermatol.* 2011 Mar;164(3):544-52. [PMID: 21062265]