

# UC Davis

## Dermatology Online Journal

### Title

Chronic actinic dermatitis occurring in an adult with atopic dermatitis

### Permalink

<https://escholarship.org/uc/item/1x19n7vm>

### Journal

Dermatology Online Journal, 21(12)

### Authors

Quatrano, Nicola A  
Shvartsbeyn, Marianna  
Meehan, Shane A  
et al.

### Publication Date

2015

### DOI

10.5070/D32112029546

### Copyright Information

Copyright 2015 by the author(s). This work is made available under the terms of a Creative Commons Attribution-NonCommercial-NoDerivatives License, available at <https://creativecommons.org/licenses/by-nc-nd/4.0/>

Peer reviewed

## Case presentation

### Chronic actinic dermatitis occurring in an adult with atopic dermatitis

Nicola A Quatrano MD, Marianna Shvartsbeyn MD, Shane A Meehan MD, Nicholas A Soter MD, and David E Cohen MD MPH

Dermatology Online Journal 21 (12): 19

New York University School of Medicine

Special Guest Editor: Nicholas A Soter MD

---

## Abstract

Chronic actinic dermatitis (CAD) is a photosensitivity disorder that is characterized by a persistent eczematous eruption in sun-exposed sites. The hallmark of CAD is a reduced minimal erythema dose (MED) to ultraviolet B (UVB), ultraviolet A (UVA), and/or to visible light, which makes phototesting the essential diagnostic investigation. The uncommon subgroup of patients with atopic dermatitis (AD) that are affected by CAD has primarily been described in young patients in the United Kingdom. We present an atopic adult women with CAD who was diagnosed years after symptoms began. We believe it is important that dermatologists perform phototests on AD patients with features of a photoaggravated dermatitis in order to avoid delay in diagnosis of a true photosensitivity condition and provide appropriate management.

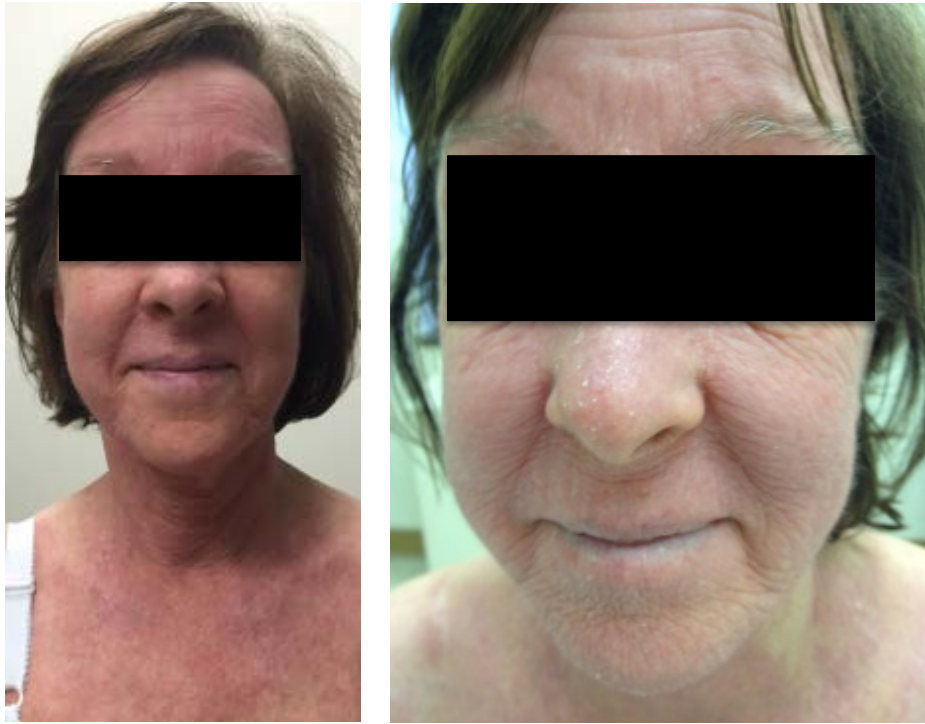## Case synopsis

**History:** A 61-year-old woman with a history of atopic dermatitis since childhood and allergic contact dermatitis with positive patch-test reactions to quaternium 15, balsam of Peru, colophony, propylene glycol, and propolis was referred to the Photomedicine Section at the Skin and Cancer Unit in March, 2015, for investigation of a photodistributed eruption. At the age of 36 years, she had become aware of a change in the pattern of her eczematous dermatitis. What originally had only intermittently involved her arms and legs, was now characterized by a persistent, pruritic eruption on her face and neck. Her condition was perennial, but she experienced increased symptoms in the summer and began to associate the flares with exposure to one hour of sunlight. Over the years, she was treated with topical glucocorticoids, systemic antibiotics, narrow-band ultraviolet B phototherapy, oral glucocorticoids, and IL-4 therapy for presumed flaring of her atopic dermatitis without resolution. Upon presentation, she had been taking cyclosporin 150 mg daily for two years with some improvement. Past medical history included asthma, rhinitis, and hyperlipidemia. Other medications included simvastatin, venlafaxine, and esomeprazole. The patient worked as a photographer, often outdoors, and enjoyed sailing and skiing.

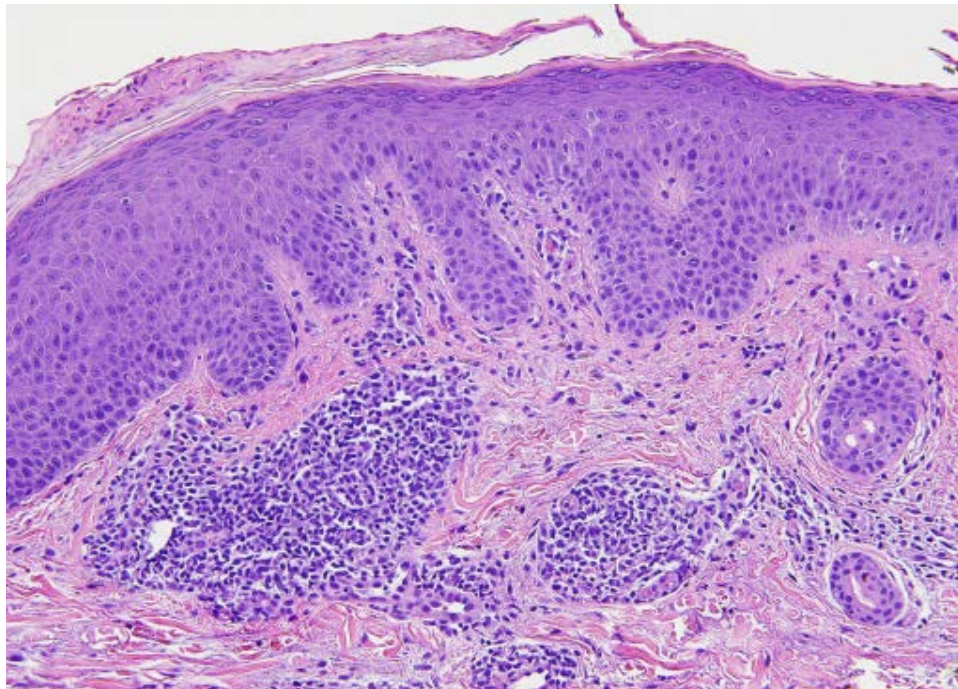
**Physical examination:** There were erythematous, eczematous plaques with lichenification that involved the face, neck, and chest in a v-shaped distribution.

**Laboratory data:** A complete blood count and comprehensive metabolic panel were normal. Phototests showed a low minimal erythema dose (MED) to ultraviolet A (UVA) of 2 J/cm<sup>2</sup>, a low MED to narrow-band ultraviolet B of 75 mJ/cm<sup>2</sup>, and a negative reaction to visible light. Photopatch tests showed equivalent, positive reactions to propolis, usnic acid and lichen acid mix in both the irradiated and nonirradiated sites

**Histopathology:** There is a superficial, perivascular infiltrate of lymphocytes that extend to epidermis where there is spongiosis, minimal acanthosis, and foci of parakeratosis.



**Figures 1,2. Erythematous eczematous facial plaques**



**Figure 3. Perivascular dermal lymphocyte infiltrate**

## **Discussion**

**Diagnosis:** Chronic actinic dermatitis occurring in an adult with atopic dermatitis

**Comment:** Chronic actinic dermatitis (CAD) is a photosensitivity disorder that is characterized by a persistent, eczematous eruption in sun-exposed sites that initially may worsen in the spring and summer before becoming perennial with time [1]. The hallmark of CAD is a reduced minimal erythema dose (MED) to ultraviolet B (UVB), ultraviolet A (UVA), and/or visible light, which makes phototesting the essential diagnostic investigation. Photosensitivity to both UVA and UVB is observed in 95% of

patients with CAD, and sensitivity to visible light is observed in 50% of patients [2]. Patients with CAD also have multiple contact allergies, with positive patch tests occurring in 70% [3]. The most frequently reported contact allergens are sesquiterpene lactone, fragrances, sunscreens, and *Compositae* oleoresins [3-6].

At times, atopic dermatitis (AD) may involve sun-exposed areas of the skin, such as the face, neck, and hands. It also is known that photosensitivity may develop during the course of AD, with sunlight exposure estimated to cause deterioration in up to 10% of AD patients [7]. This may occur secondary to photoaggravation of the underlying dermatitis in the setting of heat-induced sweating and/or sunburn [7,8]. Alternatively, exacerbation of AD may occur in the setting of a photodermatosis, such as polymorphic light eruption, actinic prurigo, or drug-induced phototoxicity [9,10]. However, most patients with a history of photoexacerbated AD have normal phototests [8,11]. The incidence of CAD among these patients has been estimated to be 3 to 10% [11].

The uncommon subgroup of AD patients that are affected by CAD has primarily been described in young patients in the United Kingdom. One of the first in 1998 reported seven young British patients with AD, with a mean age at diagnosis of 22 years, who had photosensitivity [12]. Subsequently, several more groups in the United Kingdom reported CAD in young patients with a history of atopic dermatitis [13,14]. A more recent report in the United States described two cases of CAD that occurred in two 52-year-old male patients with positive patch and photopatch tests to methylene bis-benzotriazol tetramethylbutylphenol [15].

The pathogenesis of CAD is not fully understood. It has been suggested that CAD is a contact dermatitis-like reaction to an endogenous cutaneous antigen that is induced by UV exposure [13,16]. Histopathologic examination of CAD typically demonstrates a dermal infiltrate that is composed of lymphocytes and macrophages sometimes with epidermal spongiosis and atypical mononuclear cells [17].

Photoprotection is essential in the management of patients with CAD. Sunlight avoidance, sunscreen application, skin-protective clothing, and the avoidance of known allergens should be emphasized. In younger patients in whom behavioral avoidance may be more difficult, systemic immunosuppressive therapy may be necessary. Clinical experience with CAD patients has suggested that the condition generally improves or resolves completely over time [1,16,18]. In a retrospective study of 20 patients with CAD in New York, 90% experienced resolution (35%) or improvement (55%) of their CAD during a three- to 19-year follow-up period [1].

About one-half of patients diagnosed with CAD are unaware of the role of sunlight at presentation [12]. This undoubtedly contributes to a delay in diagnosis with, on average, a seven-year gap between onset of symptoms of CAD and a phototest diagnosis [1]. Instead of solely affecting elderly individuals with long history of sun exposure as originally described, the condition may also occur in younger and adult patients with AD. Therefore, it is important to perform phototests on patients with AD and features of a photoaggravated dermatitis in order to permit diagnosis of a true photosensitivity condition and provide appropriate management.

## References

1. Wolverson JE, et al. The natural history of chronic actinic dermatitis: an analysis at a single institution in the United States. *Dermatitis* 2014;25:27
2. Frain-Bell W. Photosensitivity and actinic reticuloid. *Semin Dermatol* 1982;1:161
3. Menage H, et al. Contact and photocontact sensitization in chronic actinic dermatitis: sesquiterpene lactone mix is an important allergen. *Br J Dermatol* 1995;132:543
4. Addo HA, et al. The relationship between exposure to fragrance materials and persistent light reaction in the photosensitivity dermatitis and actinic reticuloid syndrome. *Br J Dermatol* 1982;107:261
5. Bilsland D, Ferguson J. Contact allergy to sunscreen chemicals in photosensitivity dermatitis/actinic reticuloid syndrome (PD/AR) and polymorphic light eruption (PLE). *Contact Derm* 1993;29:70
6. Frain-Bell W, Johnson BE. Contact allergic sensitivity to plants and the photosensitivity dermatitis and actinic reticuloid syndrome. *Br J Dermatol* 1979;101:503
7. Vieluf D, Ruzicka J. Complications and diseases associated with atopic eczema. In: Ruzicka J, et al eds. *Handbook of Atopic Dermatitis*, Berlin: Springer-Verlag, 1991: 54
8. Frain-Bell W. The photoaggravated dermatoses. In: Frain-Bell W, ed. *Cutaneous Photobiology*. Frain-Bell Oxford: Oxford University Press, 1985:60
9. Jansen CT. Heredity of chronic polymorphous light eruptions. *Arch Dermatol* 1978;114:188
10. Addo HA, Frain-Bell W. Actinic prurigo: A specific photodermatosis? *Photodermatol Photoimmunol Photomed* 1984;1:119
11. ten Berge O, et al. Throwing light on photosensitivity in atopic dermatitis: a retrospective review. *Am J Clin Dermatol* 2009;10:119

12. Russell SC, et al. The photosensitivity dermatitis and actinic reticuloid syndrome (chronic actinic dermatitis) occurring in seven young atopic dermatitis patients. *Br J Dermatol* 1998;138:96
13. Creamer D, et al. Chronic actinic dermatitis occurring in young patients with atopic dermatitis. *Br J Dermatol* 1998;139:1111
14. Ogboli MI, Rhodes LE. Chronic actinic dermatitis in young atopic dermatitis sufferers. *Br J Dermatol* 2000;142:812
15. Gonzalez ME, et al. Positive patch- and photopatch-test reactions to methylene bis-benzotriazolyl tetramethylbutylphenol in patients with both atopic dermatitis and chronic actinic dermatitis. *Dermatitis* 2011;22:106
16. Bryden AM, et al. Spontaneous resolution of chronic actinic dermatitis in a young patient with atopic dermatitis. *Clin Exp Dermatol* 2002;27:160
17. Lim HW, et al. Chronic actinic dermatitis: an analysis of 51 patients evaluated in the United States and Japan. *Arch Dermatol* 1994;130:1284
18. Dawe RS, et al. The natural history of chronic actinic dermatitis. *Arch Dermatol* 2000;136: 1215