

Case Presentation

Adiposis dolorosa

Panta Rouhani Schaffer MD PhD, Christopher S. Hale MD, Shane A. Meehan MD, Jerome L. Shupack MD, and Sarika Ramachandran MD

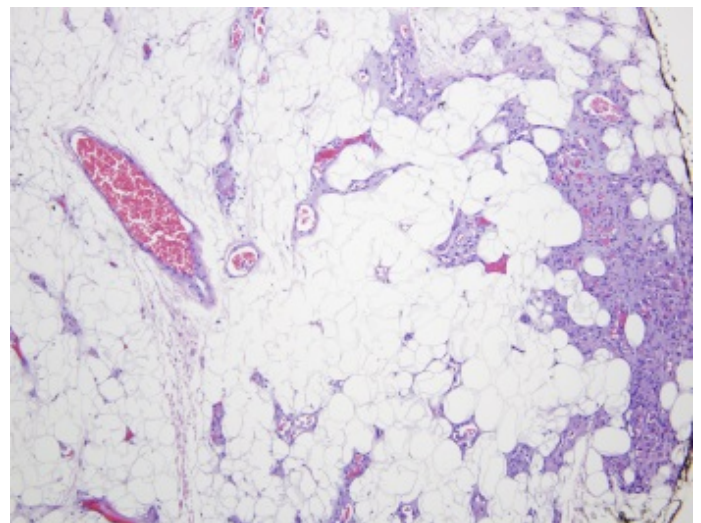
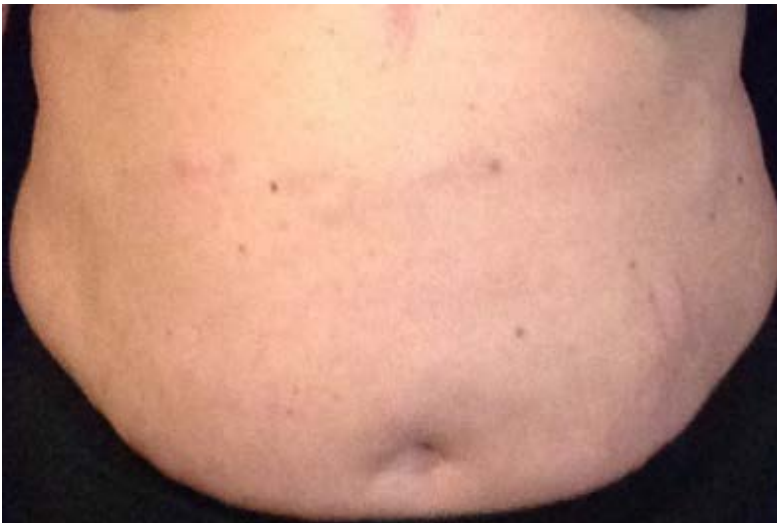Dermatology Online Journal 20 (12): 17

New York University School of Medicine

Special Guest Editor: Nicholas A. Soter, MD

Abstract

We report a 46-year-old woman with a nine-year history of obesity; chronic diffuse pain in the adipose tissue of her medial upper arms, lower trunk, and thighs; multiple biopsy-proven lipomas and angioliipomas; and a lipomatous pseudomass of the breast. Her systemic symptoms included generalized weakness, fatigue, memory impairment, and arthralgias. Although some of the lesions were tender, most were only appreciated with palpation. Her clinical history and histopathologic data suggested adiposis dolorosa (Dercum's disease). Owing to the chronic pain, an interdisciplinary approach with the use of analgesics and doxycycline has been initiated.



Case synopsis

History: A 46-year old obese woman presented to the Charles C. Harris Skin and Cancer Unit with a nine-year history of multiple lipomas, angioliipomas, chronic diffuse aching pain, increased numbers of cherry angiomas, generalized weakness, fatigue, impaired memory, and bloating. She noted that her lesions and symptoms began after weight gain, which was associated with the birth of her second child.

The patient had an 11-year history of temporal lobe seizures, factor V leiden deficiency, heterozygosity for methylenetetrahydrofolate reductase (MTHFR) deoxyribonucleic (DNA) mutation, and gastroesophageal reflux disorder. She reported having erythema nodosum within the past year. Her current daily medications included topiramate, aspirin, omeprazole, and ibuprofen. She denied history of smoking. She was adopted as a child and had limited knowledge of her biological family history. As a child, she experienced recurrent epistaxis and easy bruising.

Physical examination: Three, discrete, tender, subcutaneous tumors were present along the abdominal wall, one ill-defined tender subcutaneous plaque was present along the medial aspect of the right upper arm, and one ill-defined, tender subcutaneous nodule was present along her midline lower back. Additionally, there were 70 to 80, ruby-red papules that were scattered on the scalp, chest, abdomen, back, and extremities.

Laboratory data: A complete blood count, complete metabolic panel, urinalysis, and serum protein electrophoresis were normal. Antinuclear antibodies (ANA), anti-topoisomerase I (Scl-70), anti-Smith (Sm), anti-small antinuclear ribonucleoproteins (snRNP), anti-SSA (anti-Sjogren's syndrome A/Ro), anti-SSB (anti-Sjogren's B/La), and rheumatoid factor (RF) were absent. Magnetic resonance imaging of the brain was normal. Colonoscopy was normal. Ultrasound of the left breast showed a lipomatous pseudomass.

Histopathology: There is a circumscribed neoplasm that is composed of mature adipocytes and within which are lobular aggregates of small vessels, some of which contain microthrombi.

Discussion

Diagnosis: Adiposis dolorosa (Dercum's disease)

Comment: Adiposis dolorosa (Dercum's disease) is a complex, incompletely understood disorder of subcutaneous fat. The disease was first described in 1901 by Roux and Vitaut, who proposed four cardinal symptoms: multiple, painful, fatty masses; generalized obesity; weakness and susceptibility to fatigue (asthenia); and psychiatric manifestations, which included emotional instability, depression, epilepsy, confusion, and dementia [1]. Although the cardinal symptoms have been used as diagnostic criteria, it is unclear which symptoms are major or minor. A recent review proposes a minimal definition, which was based on the symptoms that are most often part of the disease as well as a classification schema [1]. The proposed diagnostic criteria are either overweight or obese patients with a three-month or greater time period with chronic pain in the adipose tissue. The World Health Organization has recognized adiposis dolorosa as a distinct entity and classes it as lipomatosis not elsewhere classified (International Classification of Diseases-10th Edition, IV, E88.2) [2].

Patients with adiposis dolorosa are overweight or obese and present with painful, subcutaneous nodules and tumors. Patients typically report generalized weakness and fatigue, arthralgia, painful lesions that are unaffected by weight loss, easy bruising, sleep disturbances, and a wide range of neuropsychiatric manifestations that may include impaired memory, depression, anxiety, or difficulty concentrating [1]. It is unclear if the psychological components are primary symptoms or secondary to the chronic pain and burden of disease [1-5]. There is symptomatic overlap with fibromyalgia although the etiologies are different [1-2,6-8]. Additional symptoms and comorbidities include palpitations, dyspnea, bloating, constipation, diabetes mellitus, and muscle aches [1]. There is a female preponderance and perimenopausal women between the ages of 35 and 50 years are affected [1-2]. The incidence and prevalence of adiposis dolorosa have not yet been established [1]. Whereas the majority of cases of adiposis dolorosa occur sporadically, it has been suggested that some cases of adiposis dolorosa might be an extreme expression of familial multiple lipomas [1]. However, studies have failed to detect the A to G mutation at position A8344 of mitochondrial DNA in patients with adiposis dolorosa, which is sometimes associated with familial multiple lipomas. For the studies that report a genetic element, adiposis dolorosa is presumed to be autosomal dominant with incomplete penetrance. When there is no relevant family history, the presentation is thought to relate to a new mutation [1-2,4-9].

The lesions have been reported to occur anywhere on the body. However, the majority of patients report involvement of the upper arms, the lower trunk, and the thighs. The most recently proposed classification of adiposis dolorosa accounts for the area of the body that is most involved. There are four classification types proposed: generalized diffuse form with diffusely widespread painful adipose tissue without clear lipomas, generalized nodular form with general pain in adipose tissue and intense pain in and around multiple lipomas, localized nodular form with pain in and around multiple lipomas, and juxtarticular form with solitary deposits of excess fat [1].

The etiology of these lipomatous nodules is not clear. Endocrine dysfunction, nerve system dysfunction, mechanical pressure on adjacent nerves, adipose tissue dysfunction, edema, inflammation, and trauma have been proposed, yet none has been conclusively proved. The differential diagnosis of adiposis dolorosa includes multiple symmetric lipomatosis (Madelung's disease, Lanois-Bensaude syndrome), adipose tissue neoplasms, myoclonic epilepsy with red ragged fibers (MERRF), and familial multiple lipomatosis [1-2,4-10].

Although there are no laboratory markers for this condition and laboratory tests for inflammatory and autoimmunity are negative, cases of adiposis dolorosa show similar imaging features [1-2]. A study that examined the magnetic resonance imaging (MRI)

and ultrasound appearances of the subcutaneous lesions of adiposis dolorosa reported that the lesions were centered in the superficial subcutaneous fat, were more numerous than clinically appreciated, and were typically oblong rather than round [2]. The long axis of these lesions was described to be parallel to the skin surface. Most lesions measured less than two centimeters in maximum diameter. Although most lesions that were visible at imaging were clinically asymptomatic, there were no imaging differences between symptomatic and asymptomatic lesions on ultrasound or MRI. Imaging did not demonstrate inflammation, edema, or increased vascularity, although the MRI appearance was consistent with that of angioliipomas [2,12]. There was no contrast medium enhancement with MRI and no MRI findings that were typical for adiposis dolorosa when prospectively evaluated on 6,247 MRI examinations that were performed over a period of eight months. The combination of asymptomatic and occasionally tender, multiple, subcutaneous, fatty lesions, which were hyperechoic on ultrasound, and the appearance of ill-defined, nodular, blush-like subcutaneous fat on unenhanced MRI with a decreased T1-weighted signal and increased signal in water-sensitive sequences is proposed to be pathognomonic of adiposis dolorosa [2]. In 11 cases in this study, the diagnosis of adiposis dolorosa was suggested first by a radiologist [2].

The sonographic findings in adiposis dolorosa differ from those of simple lipomas. Lipomas are often larger, not so hyperechoic, and, although they can be multiple, are not so numerous as those observed in typical cases of adiposis dolorosa [2]. Simple lipomas also are located in the deeper subcutaneous fat and tend to be round. Although simple lipomas may cause local discomfort, they are rarely tender or painful. The sonographic appearance of the lesions in adiposis dolorosa has been described in biopsy-proven cases of angioliipomas [12].

Although the imaging features of adiposis dolorosa appear to be consistent, it is unclear whether the painful lesions in adiposis dolorosa have defined histopathological features. Some studies have found them to be indistinguishable from lipomas, whereas other studies have suggested angioliipoma-like changes or inflammation [1-2]. In one case series, the histopathologic features showed angioliipoma in one case and a spindle-cell lipoma in the other case [9]. The distortion of septa could explain the imaging features of MRI and ultrasound.

The treatment of adiposis dolorosa is governed by the symptoms and comorbidities of the patient and by their overall burden of disease. For patients with diabetes mellitus and adiposis dolorosa, metformin has been reported to be beneficial in controlling the diabetes mellitus as well as the pain [13]. Metformin favorably affects the inflammatory cytokine profile (i.e., tumor necrosis factor, interleukin (IL)-1 β , IL-6, and IL-10), adipokines (i.e., adiponectin, leptin, and resistin), and β -endorphin. Other reported pharmacologic agents that are used in adiposis dolorosa include methotrexate, infliximab, interferon α -2b, glucocorticoids, calcium-channel modulators, and doxycycline for its anti-inflammatory properties [1,3-11]. Liposuction has provided relief to patients with the localized nodular form [1]. Anti-inflammatory agents, such as glucocorticoids, analgesics, and lidocaine patches, have been used for pain management. Rapid cycling hypobaric pressure treatments were beneficial for a small group of patients [3]. Patients with adiposis dolorosa should be treated by an interdisciplinary team that specializes in chronic pain management.

References

1. Hansson E, et al.: Review of Dercum's disease and proposal of diagnostic criteria, diagnostic methods, classification and management. *Orphanet J Rare Dis* 2012;7:23 [PMID: 22546240]
2. Tins BJ, et al.: Adiposis dolorosa (Dercum's disease): MRI and ultrasound appearances. *Clin Radiol* 2013; 68:1047 [PMID: 23809264]
3. Herbst KL, Rutledge T: Pilot study: rapidly cycling hypobaric pressure improves pain after 5 days in adiposis dolorosa. *J Pain Res* 2010;3:147 [PMID: 21197318]
4. Lange U, et al.: Dercum's disease (lipomatosis dolorosa): successful therapy with pregabalin and manual lymphatic drainage and a current overview. *Rheumatol Int* 2008;29:17 [PMID: 18604537]
5. Hansson E, et al.: Depression in Dercum's disease and in obesity: a case-control study. *BMC Psychiatry* 2012;12:74 [PMID: 22759645]
6. Yousefi M. Adiposis dolorosa. In: Elston D, ed. *Medscape*. New York: WebMD; 2010
7. Amine B, et al.: Dercum's disease (adiposis dolorosa): a new case report. *Joint Bone Spine* 2004;71:147 [PMID: 15050201]
8. Brodovsky S, et al.: Adiposis dolorosa (Dercum's disease): 10-year follow-up. *Ann Plast Surg* 1994;33:664 [PMID: 7880063]
9. Campen R, et al.: Familial occurrence of adiposis dolorosa. *J Am Acad Dermatol* 2001;44:132 [PMID: 11148491]
10. Lynch HT, Harlan WL: Hereditary factors in adiposis dolorosa (Dercum's disease). *Am J Hum Genet* 1963;15:184 [PMID: 17948485]
11. Hansson E, et al.: Histology of adipose tissue inflammation in Dercum's disease, obesity and normal weight controls: a case control study. *J Inflamm (Lond)* 2011;8:24. [PMID: 21955696]
12. Bang M, et al.: Ultrasonographic analysis of subcutaneous angioliipoma. *Skeletal Radiol* 2012;41:1055 [PMID: 22064985]
13. Labuzek K, et al.: A successful case of pain management using metformin in a patient with adiposis dolorosa. *Int J Clin Pharmacol Ther* 2013;51:517 [PMID: 23611575]