

**Case presentation**

**Breast nodularity and ulceration: diffuse dermal angiomatosis a corticosteroid responsive disease**

**JD Ho<sup>1,2</sup>, D Wolpowitz<sup>1,2</sup>, TJ Phillips<sup>1</sup>**

**Dermatology Online Journal 22 (11): 9**

<sup>1</sup> **Department of Dermatology, Boston University School of Medicine, Boston, MA**

<sup>2</sup> **Department of Dermatology and Section of Dermatopathology, Boston University School of Medicine, Boston, MA**

**Correspondence:**

Jonathan Dale Ho MBBS, M.Sc  
609 Albany Street  
Boston, MA 02115  
Phone: 954-260-4621  
Email: jdho@bu.edu

---

**Abstract**

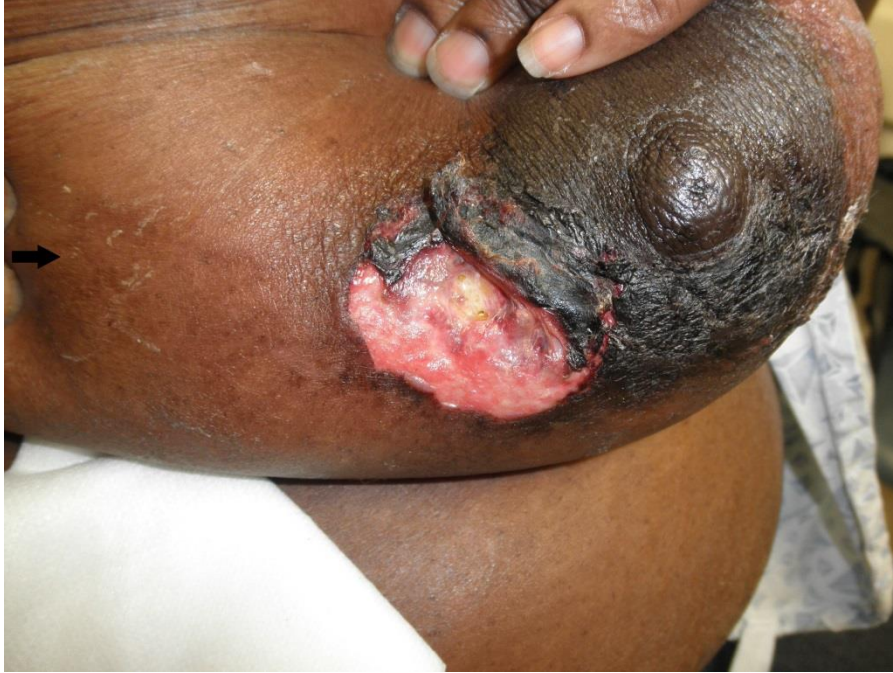Diffuse dermal angiomatosis of the breast (DDAB) is an uncommon ulcerative angiomatosis, which occurs in middle aged women with large pendulous breasts, a history of cigarette smoking, and risk factors for atherosclerosis. Based on its rarity, no well-defined therapeutic regimen has been elucidated. We report a case of DDAB in a woman with no history of smoking or radiographic evidence of occluded vasculature who presented with ulceration and pain-associated breast nodularity. She had a complete reproducible response to oral corticosteroids.

**Keywords: dermal angiomatosis, vascular proliferation, breast nodularity, breast ulceration, prednisone**

**Introduction**

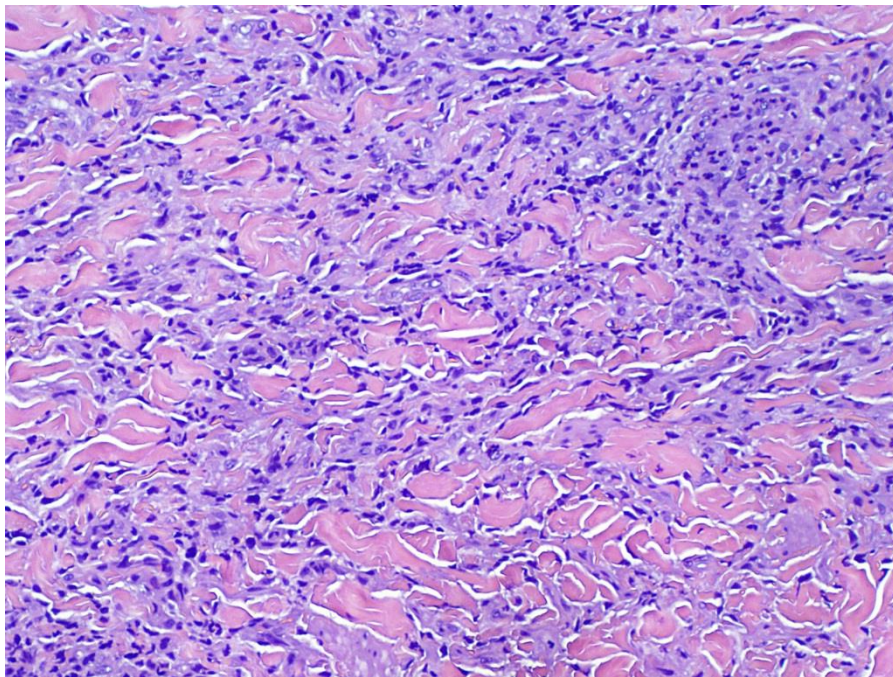
Diffuse dermal angiomatosis of the breast (DDAB) is an uncommon ulcerative angiomatosis with fewer than 50 reported cases. DDAB occurs in middle aged females with large pendulous breasts, a history of cigarette smoking, and risk factors for atherosclerosis. Based on its rarity, no well defined therapeutic regimen has been elucidated. We report a case of DDAB in a woman with no history of smoking or radiographic evidence of occluded vasculature. Unique features included pronounced underlying breast nodularity and a complete and reproducible response to oral prednisone.

## Case synopsis

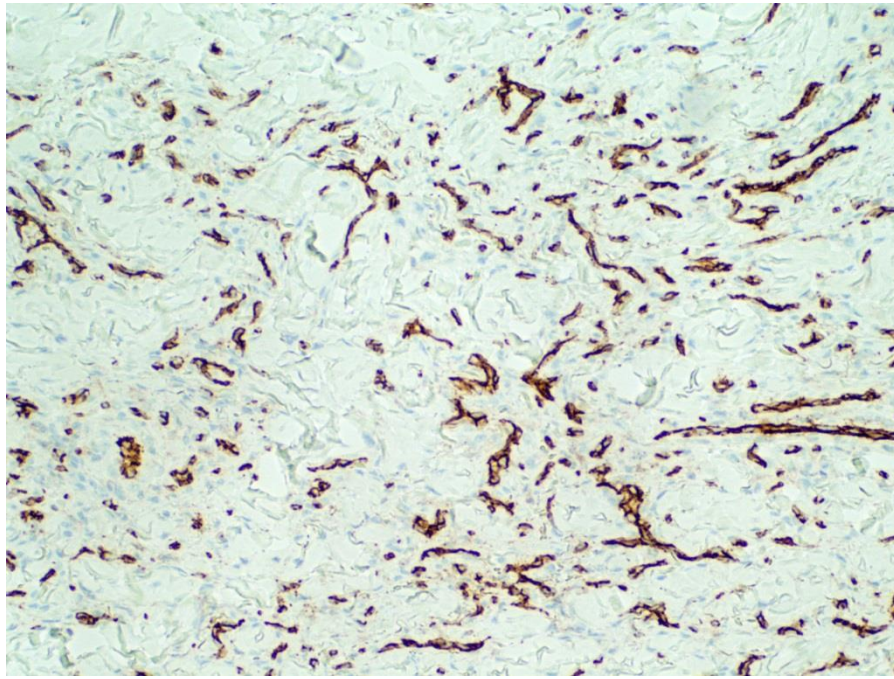


**Figure 1.** Diffuse dermal angiomatosis: large periareolar ulcer with hemorrhagic crusting. Note adjacent subtle reticulated red-brown patch (arrow).

A 50-year-old woman was referred to our clinic with a 2 month history of an erythematous plaque on her right breast that had become tender and ulcerated over a four week period. She denied trauma to the breast or a prior history of tobacco use. Her past medical history was significant for end-stage renal disease, hypertension, and obesity. Examination revealed pendulous breasts with pronounced underlying nodularity. The right breast contained an extremely tender peri-areolar ulcer with overlying hemorrhagic crust (Figure 1). The left breast demonstrated a subtle, slightly tender, erythematous and reticulate patch.



**Figure 2.** Diffuse dermal angiomatosis: right breast, H&E 100x. The specimen exhibits a percolating dermal proliferation of plump CD31 positive endothelial cells forming numerous small ectatic blood vessels arranged between collagen bundles and dense dermal fibrosis.



**Figure 3.** Bland CD31 positive endothelial cells characteristic of diffuse dermal angiomatosis, 100x.

Histopathologic examination of a wedge biopsy demonstrated a bland CD31 positive, extravascular endothelial proliferation dissecting collagen bundles, with focal vascular lumen formation (Figures 2, 3). Calcification of subcutaneous vessel walls suggestive of calciphylaxis was not identified and Von kossa staining for calcium was negative. Findings were diagnostic of DDAB.

Vascular studies revealed no upper limb arterial occlusion. Despite adequate wound care, the ulcer rapidly enlarged after biopsy. Prednisone was started at 40 mg daily, tapering by 10 mg weekly until 10 mg, followed by maintenance on 5 mg until resolution. Pain was dramatically reduced within two days of initiating prednisone, accompanied by a rapid decrease in ulcer size and nodularity. Complete resolution was seen over a period of approximately 12 weeks. After 2 months, the patient had recurrence of nodularity, pain, and ulceration. Prednisone 40 mg was again prescribed and again she experienced rapid decrease in pain and complete healing within 3 weeks.

## Discussion

Diffuse dermal angiomatosis (DDA) was initially described as a type of reactive angioendotheliomatosis [1], but has been reclassified as a distinct reactive vascular entity owing to the extravascular location of the proliferating vessels. Diffuse dermal angiomatosis of the breast (DDAB) begins with tender reticulate patches, which evolve into painful ulcers in fat-rich dependent areas [2]. Interestingly, both our case and one other, describe underlying tender breast nodularity [2]. This feature likely represents extensive vascular proliferation and when present in association with breast ulceration of unknown origin, may serve as a clinical clue to the diagnosis of DDAB. Nodularity may precede ulceration (as noted in the left breast of our patient), and our case suggests it may be an early clinical indicator disease. Recognition, therefore, may be of particular importance in patients with darker skin types where the early reticulated erythema is subtle and easily missed.

DDAB is rare and occurs in females with pendulous breasts who smoke [2, 3, 4, 5, 6]. Some patients have radiologic confirmation of partial arterial occlusion [2]. The reported associations with positive anticardiolipin antibodies and calciphylaxis, have raised the possibility that DDA represents a reactive proliferation secondary to microvascular occlusion [4, 7]. Cigarette smoking induced endothelial dysfunction and hypercoagulability seem contributory in the majority of reported cases, though not in ours'. Large pendulous breasts appear to be the universal risk factor for DDAB. Repetitive low-grade trauma to relatively poorly perfused, dependent adipose tissue, in the setting of macro- or micro-vascular occlusion, induces a hypoxic tissue state. In this hypoxic state, excessive angioproliferative factors, including VEGF, are produced resulting in excessive endothelial proliferation

[8]. The proliferation typically demonstrates positivity for CD31 and CD34, but is negative for lymphatic differentiation markers [6].

Because of the rarity of this entity, an accepted treatment protocol has not been established. Correction of macrovascular occlusion, when present, is important because this may render medical therapy ineffective [2]. Reduction mammoplasty has been reported as a novel therapy for DDAB [5], but care must be taken as surgical trauma may exacerbate DDA as demonstrated after incisional biopsy in our patient. Reported medical therapies include isotretinoin, oral prednisone, and pentoxifylline/aspirin combination therapy [3, 4, 9, 10]. Smoking cessation has been cited as the single most important therapeutic strategy, although DDAB can occur in non-smokers [6]. Interestingly, a recent review of DDAB noted spontaneous resolution in two of the five cases in their series [11], but this does not seem to be common. Prednisone provided a fast-acting, readily available therapy for our patient, with complete and reproducible resolution of the pain and ulceration, Efficacy is likely as a consequence of anti-proliferative and anti-inflammatory properties. Isotretinoin has also been reported to be useful in treating DDA possibly owing to anti-angiogenic properties [10, 12], though a recent review noted that neither of 2 patients treated with isotretinoin had complete resolution, and both had recurrences after discontinuation [13].

## Conclusions

DDAB, which presents with painful breast ulcers preceded or accompanied by reticulated erythema, is a unique variant of the reactive angiomatoses. Patients with DDAB tend to have pendulous breasts, but may or may not have a history of smoking. Underlying tender breast nodularity may serve as an additional clue to the diagnosis and was useful in our patient whose darker skin type made the characteristic reticulate erythema harder to appreciate. Prednisone provided rapid symptomatic relief and reproducible ulcer resolution in our patient and may represent a first-line therapeutic option.

## References

1. Krell JM, Sanchez RL, Solomon AR. Diffuse dermal angiomatosis: a variant of reactive cutaneous angioendotheliomatosis. *J Cutan Pathol* 1994; 21:363-370. [PMID:7798394]
2. Yang H, Ahmed I, Mathew V, Schroeter AL. Diffuse dermal angiomatosis of the breast. *Arch Dermatol* 2006; 142 : 343-347. [PMID:16549710]
3. McLaughlin ER, Morris R, Weiss SW, Arbiser JL. Diffuse dermal angiomatosis of the breast: response to isotretinoin. *J Am Acad Dermatol* 2001; 45:462-465. [PMID:11511849]
4. Pichardo RO, Lu D, Sanguenza OP, Guitart J. What is your diagnosis? Diffuse dermal angiomatosis secondary to anticardiolipin antibodies. *Am J Dermatopathol* 2002; 24:502-503. [PMID:12454604]
5. Villa MT, White LE, Petronic-Rosic V, Song DH. The treatment of diffuse dermal angiomatosis of the breast with reduction mammoplasty. *Arch Dermatol* 2008; 144:693-694. [PMID: 18490610]
6. Sanz-Motilva V, Martorell-Calatayud A, Rongioletti F et al. Diffuse dermal angiomatosis of the breast: clinical and histopathological features. *Int J Dermatol* 2014; 53:445-449. [PMID:23488550]
7. Prinz Vavricka BM, Barry C, Victor T Guitart J. Diffuse dermal angiomatosis associated with calciphylaxis. *Am J Dermatopathol* 2009; 31:653-657. [PMID: 19652584]
8. Rongioletti F, Rebora A. Cutaneous reactive angiomatoses: patterns and classification of reactive vascular proliferation. *J Am Acad Dermatol* 2003; 49:887-896. [PMID: 14576670]
9. Sommer S, Merchant WJ, Wilson CL. Diffuse dermal angiomatosis due to an iatrogenic arteriovenous fistula. *Acta Derm Venereol* 2004; 84:251-252. [PMID: 15202855]
10. A cause of unbearably painful breast, diffuse dermal angiomatosis. Adams BJ, Goldberg S, Massey HD, Takabe K. *Gland Surg* 2012; 1:132-135, [PMID: 2435398]
11. Tollefson MM, McEvoy MT, Torgerson RR, Bridges AG. Diffuse dermal angiomatosis of the breast: clinicopathologic study of 5 patients. *J Am Acad Dermatol* 2014; 71:1212-1217. [PMID: 25264238]
12. Guruvayoorappan C, Kuttan G. Cis-retinoic acid regulates cytokine production and inhibits angiogenesis by disrupting endothelial cell migration and tube formation. *J Exp Ther Oncol* 2008; 7:173-182. [PMID: 19066126]
13. Reusche R, Winocour S, Degnim A, Lemaine V. Diffuse dermal angiomatosis of the breast: a series of 22 cases from a single institution. *Gland Surg*. 2015 Dec;4(6):554-60. [PMID: 26645009]