

A case of new-onset vitiligo in a patient on tofacitinib and brief review of paradoxical presentations with other novel targeted therapies

Julie K. Nguyen¹ MD, Megan J. Schlichte² MD, Reena Jogi³ MD, Mujahed Alikhan⁴ MD, Anisha B. Patel^{5,6} MD

Affiliations: ¹Department of Dermatology, SUNY Downstate Medical Center, Brooklyn, New York, USA; ²Department of Dermatology, Baylor College of Medicine, Houston, Texas, USA; ³Village Dermatology, Houston, Texas; ⁴Medical Clinic of Houston, Rheumatology, Houston, Texas, USA; ⁵Department of Dermatology, Division of Internal Medicine, University of Texas MD Anderson Cancer Center, Houston, Texas, USA; ⁶Department of Dermatology, University of Texas Health Science Center at Houston, Houston, Texas, USA

Corresponding Author: Anisha B. Patel, M.D., Department of Dermatology, University of Texas MD Anderson Cancer Center, 1515 Holcombe Boulevard, unit 1452, Houston, TX 77030, Tel: 713-745-1113, Fax: 713-745-3597, Email: APatel11@mdanderson.org

Abstract

With recent advancements in the understanding of vitiligo pathogenesis, Janus kinase (JAK) inhibitors have emerged as a promising new treatment modality, but their effects remain incompletely elucidated. Tofacitinib, an oral JAK 1/3 inhibitor approved for the treatment of rheumatoid arthritis, has previously been shown to induce significant repigmentation in vitiligo. However, as with other novel targeted therapies, cutaneous adverse effects have been observed. We report a 36-year-old woman with a history of rheumatoid arthritis, refractory to multiple pharmacotherapies, who was initiated on tofacitinib and subsequently developed progressive depigmented patches consistent with new-onset vitiligo. Although definitive causation cannot be established in this case without additional studies, it is important to note that many targeted therapies have the potential to induce paradoxical effects, that is, the occurrence or exacerbation of pathologic conditions that have been shown to respond to these medications. Paradoxical findings with other targeted therapies include the occurrence of melanoma during treatment with BRAF inhibitors, keratoacanthomas with PD-1 inhibitors, vitiligo and psoriasis with TNF-alpha inhibitors, and hidradenitis suppurativa with various biologic agents. Although JAK inhibitors hold therapeutic promise in the treatment of inflammatory skin disorders, further research is warranted to more fully comprehend their effects.

Keywords: vitiligo, Janus kinase inhibitor, tofacitinib, paradoxical effects

Introduction

Vitiligo is an acquired skin disorder clinically characterized by the development of depigmented macules and patches, caused by the selective autoimmune destruction of melanocytes [1]. At present, there is no definitive cure for this condition and existing treatment options are often inadequate. Although the exact pathogenesis of vitiligo remains only partially understood, it is believed that IFN γ signal transduction, as mediated through the canonical JAK-STAT (Janus kinase-signal transducers and activators of transcription) pathway, drives vitiligo autoimmunity, suggesting a potential therapeutic role for JAK inhibitors in the treatment of vitiligo [2, 3]. However, as with other novel targeted therapies, paradoxical cutaneous findings may be observed when alternative uninhibited pathways are upregulated, inflammatory cascades are altered, and/or cytokine balance is disrupted. Herein, we report a case of new-onset generalized vitiligo in a previously unaffected patient who had received oral tofacitinib therapy for rheumatoid arthritis.

Case Report

A 36-year-old woman with rheumatoid arthritis presented for evaluation of progressive

depigmented patches that developed over the preceding four months. Diagnosed with rheumatoid arthritis two years prior to presentation, the patient had failed multiple disease-modifying antirheumatic drugs and tumor necrosis factor (TNF) inhibitors. Prior therapies included methotrexate, certolizumab pegol, golimumab, and infliximab. The patient also had a history of Grave hyperthyroidism with papillary thyroid microcarcinoma, for which she underwent total thyroidectomy prior to her diagnosis of rheumatoid arthritis, with euthyroid maintenance on levothyroxine. After experiencing an autoantibody-mediated anaphylactic reaction to infliximab infusion, she was switched to monotherapy with tofacitinib citrate (extended-release 11mg daily) for rheumatoid arthritis. At her rheumatology clinic follow-up visit four months following initiation of

tofacitinib she reported good efficacy of tofacitinib for her joint pain, along with the concurrent development of depigmented patches on her neck, chest, arms, and hands, for which she was referred for dermatology consultation (**Figure 1**). Routine laboratory tests, including complete blood count and comprehensive metabolic panel, were stable during her four-month treatment on tofacitinib, with an overall decrease in erythrocyte sedimentation rate from 41mm/hr to 26mm/hr. The diagnosis of generalized vitiligo was made based on clinical presentation and tofacitinib was immediately discontinued. The patient followed up in dermatology clinic six weeks (**Figure 2**), three months, and six months later without notable repigmentation or progression of vitiligo. Approximately 18 months later, she self-reported no change in the severity and extent of involvement of

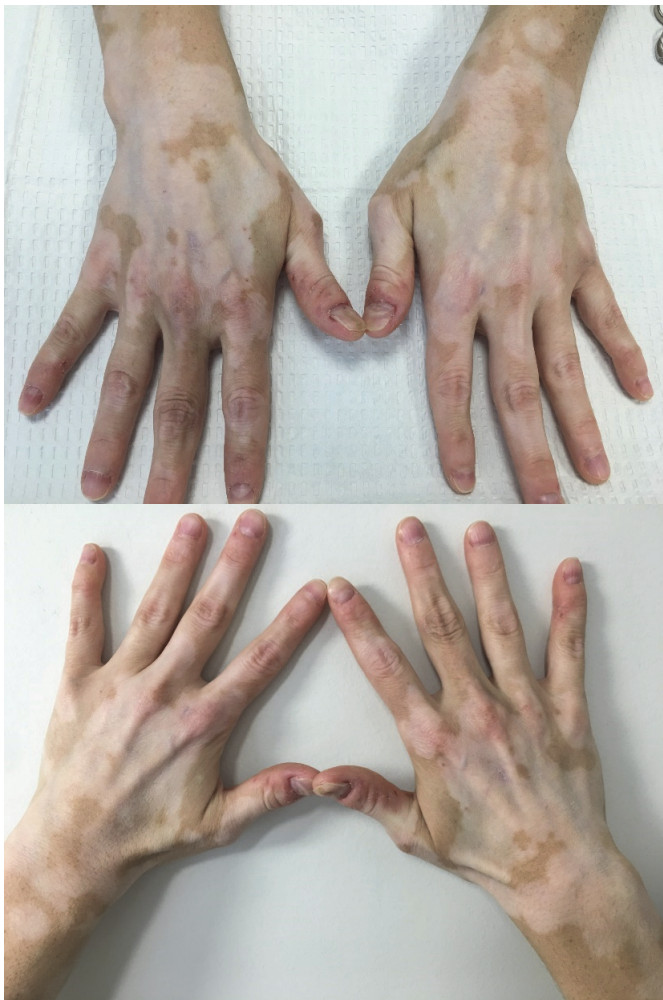

Figure 1. Development of vitiligo on the dorsal hands after four months of treatment with tofacitinib citrate extended-release 11mg daily for rheumatoid arthritis.

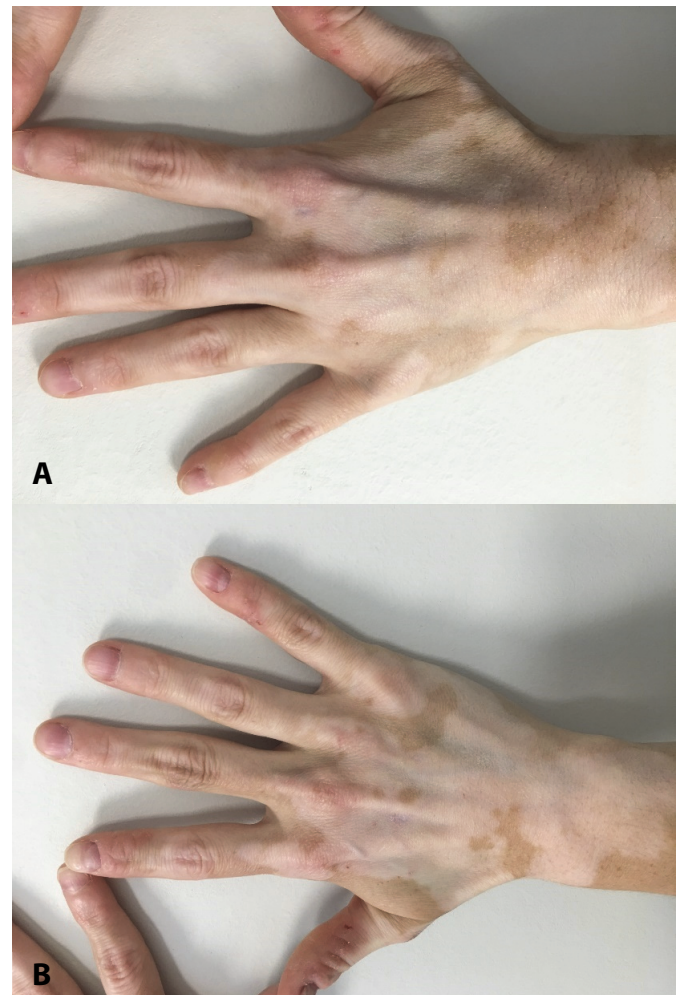


Figure 2. Persistence of vitiligo on the dorsal hands after six weeks following discontinuation of tofacitinib.

Table 1. Paradoxical adverse effects of common targeted therapies used for dermatologic diseases.

Targeted therapy class	Agents within class	Therapeutic Indications	Paradoxical adverse effect(s)	Reversibility
BRAF inhibitors	Dabrafenib Vemurafenib	Melanoma	Cutaneous melanoma	-Increased risk is reversible -New malignancy is not reversible
PD-1 inhibitors	Cemiplimab Nivolumab Pembrolizumab	Cervical cancer Colorectal cancer Cutaneous SCC Gastric cancer Head and neck SCC Hepatocellular carcinoma Hodgkin’s lymphoma Lung SCC Melanoma Merkel cell carcinoma NSCLC RCC Small cell lung cancer Urothelial carcinoma	Cutaneous squamous cell carcinoma/keratocanthoma	- Increased risk is reversible - Some tumors have regressed without treatment
TNF α inhibitors	Adalimumab Etanercept Infliximab	Ankylosing spondylitis Crohn’s disease Hidradenitis suppurativa [†] Juvenile idiopathic arthritis	Hidradenitis suppurativa	- Yes, with treatment and d/c medication
		Psoriasis Psoriatic arthritis Rheumatoid arthritis Ulcerative colitis	Psoriasis	- Yes, with treatment and d/c medication
JAK inhibitors	Ruxolitinib Tofacitinib	Myelofibrosis Polycythemia vera Psoriasis Rheumatoid arthritis Vitiligo [†]		- Unknown

the vitiligo area (i.e., no improvement or worsening). No rechallenge with tofacitinib or therapy for vitiligo was attempted. At the 18-month time period, the patient was only using non-steroidal anti-inflammatory drugs for her rheumatoid arthritis with good control.

Discussion

Tofacitinib was approved by the U.S. Food and Drug Administration in 2012 for the treatment of moderate-to-severe RA in adults who demonstrate an inadequate response to methotrexate [4]. The most commonly reported adverse effects in phase II and III clinical trials were diarrhea, nasopharyngitis, upper respiratory tract infection, and headache [5].

The incidence of dermatologic reactions is not known, but rash, erythema, and pruritus have been reported [5]. Janus kinase inhibitors, including oral and topical tofacitinib, have emerged as well-tolerated and variably effective treatment options for a wide spectrum of inflammatory skin conditions including atopic dermatitis, plaque psoriasis, alopecia areata, and vitiligo in case reports and ongoing clinical trials [2, 3, 6, 7].

Emerging research studies investigating the immunopathogenic pathway underlying vitiligo have facilitated the development of new, targeted pharmacologic therapies. It has been shown that the IFN γ /CXCL10 chemokine axis is required for the progression and maintenance of vitiligo. IFN γ signal transduction occurs through the JAK-STAT pathway

and leads to CXCL10 expression in keratinocytes, ultimately resulting in the recruitment of autoreactive CD8+ cytotoxic T lymphocytes to the skin [8]. Activated cytotoxic T lymphocytes are believed to migrate to sites of inflammation, promote further T cell recruitment, and produce IFN γ , which inhibits melanogenesis and also directly induces melanocyte apoptosis, thereby driving vitiligo autoimmunity [9].

The findings of this translational research led Craiglow and King to pursue a therapeutic trial of oral tofacitinib citrate in a patient with generalized vitiligo who had failed conventional treatments. Five months of treatment resulted in near-complete repigmentation of her face and hands, with partial repigmentation of the remaining lesions [2]. The authors proposed that because IFN γ -induced CXCL10 mediates depigmentation, the use of tofacitinib as a JAK 1/3 inhibitor to block IFN γ signaling effectively attenuated CXCL10 secretion by keratinocytes and clinically resulted in repigmentation [2, 4]. Supporting this hypothesis are reports of significant clinical improvement in facial vitiligo in patients treated with topical or oral ruxolitinib, a JAK 1/2 inhibitor approved for use in myelodysplastic disorders [10, 11].

Cutaneous adverse effects that have been reported in association with JAK inhibitors include herpes zoster, disseminated molluscum, eruptive squamous cell carcinomas, drug reaction with eosinophilia and systemic symptoms, and morbilliform drug eruptions [12]. To our knowledge, new-onset vitiligo occurring during treatment with tofacitinib has not been previously reported in the literature. Arguments for causation cannot be validated in this isolated case, but the rapid development of *de novo* vitiligo shortly after initiation with tofacitinib is noteworthy, as topical and oral JAK inhibitors are currently being studied as a promising therapeutic modality for vitiligo. Although the medication may have served as a triggering factor, the association of vitiligo with other underlying autoimmune diseases, such as rheumatoid arthritis and thyroid disease, as in this patient, cannot be discounted.

As there are complex interconnections between the JAK-STAT pathway and other cell signaling networks, there are multiple potential molecular mechanisms by which the onset of vitiligo could have been triggered in this case. Tofacitinib is a pan-JAK inhibitor with potent functional selectivity for JAK3- and JAK1-dependent STAT activation over JAK2-mediated pathways [13]. We postulate that *de novo* development of generalized vitiligo in our patient may have been triggered by JAK 1/3 blockade causing a paradoxical upregulation of IFN γ signaling via JAK2. Additionally, JAK inhibition affects not only the IFN γ pathway, but also modulates the signal transmission and production of multiple pro-inflammatory cytokines including IL1, IL4, IL7, IL9, IL15, and IL21 [14, 15]. It is unclear to what extent signaling by these other inflammatory cascades are abrogated by tofacitinib-induced JAK blockade.

The use of several targeted therapies for the treatment of dermatologic conditions has resulted in the observation of immune-related and paradoxical adverse effects, the latter defined as the occurrence or exacerbation of pathologic conditions during treatment with an agent that should be effective for that disease. Following is a brief, non-exhaustive review of immune-related and paradoxical adverse effects that have been observed with the administration of these novel targeted therapies.

Table 1 provides a non-comprehensive list of commonly used medications in dermatology and their paradoxical cutaneous toxicities.

Melanoma with BRAF inhibitors

The MAPK signaling pathway plays a key role in melanoma tumorigenesis with dysregulation occurring due to BRAF mutations. With mutations found in approximately 40-60% of cutaneous melanomas, BRAF inhibitors are first-line therapeutics for patients with BRAF V600-mutant metastatic melanoma [16]. Cutaneous adverse effects, including malignant neoplasms, are among the most frequently observed toxicities with the selective BRAF inhibitors vemurafenib and dabrafenib [16, 17]. The development of new primary melanomas with a wild-type BRAF genotype have been reported in patients receiving treatment with BRAF inhibitors, arising as new pigmented

lesions or rapidly evolving, pre-existing melanocytic lesions [18–23]. In one study, up to 21% of patients on vemurafenib exhibited changes in their pre-existing pigmented nevi that were consistent with melanoma [22]. Though it is known that patients previously diagnosed with melanoma are at increased risk of developing subsequent new primary melanomas, their lifetime risk is generally estimated to be 2-10% [22]. It is believed that these new primary melanomas were dormant and clinically undetectable before the initiation of BRAF inhibitor therapy; they then became clinically relevant by the paradoxical BRAF activation of wild-type cells. Preclinical studies suggest that exposure to selective V600E BRAF blockers promotes the proliferation of BRAF wild-type melanocytes through paradoxical activation of the MAPK pathway, causing upregulation of cyclin D1 (required for cell cycle progression) and resulting in proliferative skin toxicities including oncogenesis [24, 25].

Keratoacanthomas with PD-1 inhibitors

Used to treat unresectable or metastatic melanoma, pembrolizumab is an immune checkpoint inhibitor targeting the programmed cell death 1 (PD-1) receptor of lymphocytes. The eruption of keratoacanthomas (KAs) has been reported in patients receiving pembrolizumab [26, 27]. More recently, pembrolizumab has demonstrated efficacy in the treatment of locally advanced squamous cell carcinomas [28]. One proposed mechanism for the occurrence of new-onset keratoacanthomas in patients receiving anti-PD-1 therapy is that the resultant enhanced immune response could induce epithelial proliferation and chronic inflammation, which has been shown to be a driver of squamous cell carcinoma development [26, 27]. Furthermore, it has recently been shown that a homo- or heterozygous deletion of PD-1 permits uncontrolled T cell proliferation with oncogenically-activated T cell receptor pathways *in vivo*, suggesting a mechanism for oncogenesis with anti-PD-1 therapy [29].

Vitiligo with PD-1 inhibitors

Other immune-driven cutaneous phenomena have also been observed with anti-PD-1 therapy, such as with pembrolizumab and nivolumab [30]. Although

this is not a paradoxical reaction, it was included for completeness as it is an example of drug-induced vitiligo with a potentially distinct mechanism from the autoimmune variety. Vitiligo is a classic side effect of PD-1 inhibitors, as it has been suggested that melanocytic antigens are released by tumor cells when destroyed by PD-1 antibodies, which induces an immune response against native melanocytes as well [31]. However, these treatment-associated lesions display a clinical and biological pattern different from spontaneous vitiligo, with the anti-PD-1 induced vitiligo-like lesions characterized by multiple flecked, depigmented macules evolving toward larger plaques, without evidence of Koebnerization [32]. The immunophenotype of these vitiligo-like lesions is also different from spontaneous vitiligo. Larsabal et al. found a unique CXCR3⁺ CD8⁺ T cell-predominant infiltrate in perilesional biopsies of patients with vitiligo-like lesions receiving anti-PD-1 therapy for metastatic melanoma or lung cancer [32]. They also detected increased serum levels of CXCL10 and the expression of IFN γ and TNF α by skin-infiltrating CD8 T cells, not found in patients with spontaneous vitiligo or healthy controls [32]. These findings suggest a pathophysiological mechanism of depigmentation distinct from vitiligo through an immune-mediated side effect of anti-PD1 therapy.

Vitiligo with TNF inhibitors

Anti-TNF agents have been utilized as an off-label treatment option for vitiligo, but their administration has also been associated with the emergence or worsening of vitiligo [33, 34]. Abnormal expression of the pro-inflammatory cytokine TNF has been detected in active vitiligo lesions, making TNF a potential therapeutic target. Stabilization of disease and repigmentation have been achieved with TNF inhibition in patients with progressive vitiligo. However, paradoxically, treatment can be associated with *de novo* vitiligo development when anti-TNF agents are used for other chronic inflammatory conditions [35–37]. In one population-based cohort study, a significantly increased risk of vitiligo was observed in individuals who were treated with TNF inhibitors for ankylosing spondylitis, Crohn disease, or ulcerative colitis compared to those who were

unexposed [37]. Thus, TNF has dual properties in the skin, giving rise to cytokine imbalance and heterogeneous clinical effects with its blockade.

Psoriasis with TNF inhibitors

Shown to be both induced by, and treated with TNF inhibitors, psoriasis is a classic example of a paradoxical adverse effects of a common biologic agent. Anti-TNF agents have been associated with the induction of psoriasis and psoriasiform eruptions in patients being treated for rheumatologic or inflammatory bowel diseases, as well as with exacerbation of existing psoriatic disease, the latter characterized by possible new areas of localization and distinct morphology [38–42]. A subset of affected patients exhibits new psoriatic lesions upon switching to an alternative TNF inhibitor as well [39, 43]. This phenomenon may be partly explained by a cytokine imbalance from TNF blockade, including overexpression of IFN γ and IFN α by plasmacytoid dendritic cells, which in turn drive the development of psoriatic lesions in genetically predisposed patients [38, 44].

Hidradenitis suppurativa with multiple biologic agents

New onset hidradenitis suppurativa has been reported during administration of TNF inhibitors, rituximab, and tocilizumab for chronic inflammatory diseases and complete resolution has been observed after treatment discontinuation or transition to another biologic agent [43, 45, 46]. Drug rechallenge may cause hidradenitis relapse in some patients [45]. Possible hypotheses for the occurrence of hidradenitis as a paradoxical adverse effects of TNF inhibitor or other biologic therapy include local modification of cytokine balance, activation of alternate pathways such as type I IFN or IL1 β , and/or an increased risk of infection triggering hidradenitis suppurativa [43].

References

1. Alikhan A, Felsten LM, Daly M, Petronic-Rosic V. Vitiligo: A comprehensive overview: Part I. Introduction, epidemiology, quality of life, diagnosis, differential diagnosis, associations,

Conclusion

New immunotherapies are revolutionizing the clinical management of various dermatologic diseases. Patients receiving these novel agents may experience paradoxical development of the same pathologic conditions that these drugs have been shown to treat. The JAK 1/3 inhibitor tofacitinib has emerged as a potential therapeutic strategy for vitiligo, but our case documents de novo vitiligo arising in a patient with rheumatoid arthritis treated with oral tofacitinib. Although a paradoxical effect of tofacitinib cannot be definitively confirmed in this case without additional evidence from case series and randomized controlled trials, we propose that this de novo vitiligo may have resulted from paradoxical upregulation of IFN γ signaling through JAK 2. Vitiligo is typically asymptomatic but has significant aesthetic and psychosocial associations. However, the clinical benefits of tofacitinib for the treatment of rheumatoid arthritis and other conditions may very well still outweigh the potential risks of a paradoxical reaction.

As advances in our understanding of the molecular mechanisms of disease result in new, targeted therapies, clinician awareness and recognition of immune-mediated and paradoxical adverse effects are critical for informed clinical decision-making and patient counseling. Although very promising for the treatment of vitiligo and other immune-mediated dermatoses, JAK inhibitors require further investigation to assess the side effect profile. Prospective, long-term safety evaluations of novel JAK inhibitors such as tofacitinib are warranted as the potential therapeutic applications continue to expand.

Potential conflicts of interest

The authors declare no conflicts of interests.

histopathology, etiology, and work-up. *J Am Acad Dermatol.* 2011;65:473-491. [PMID: 21839315].
2. Craiglow BG, King BA. Tofacitinib Citrate for the Treatment of

- Vitiligo. *JAMA Dermatology*. 2015;151:1110-1112. [PMID: 26107994].
3. Damsky W, King BA. JAK inhibitors in dermatology: The promise of a new drug class. *J Am Acad Dermatol*. 2017;76:736-744. [PMID: 28139263].
 4. Kostovic K, Gulin SJ, Mokos ZB, Ceovic R. Tofacitinib, an Oral Janus Kinase Inhibitor: Perspectives in Dermatology. *Curr Med Chem*. 2017;24:1158-1167. [PMID: 28088907].
 5. *Xeljanz/Xeljanz XR (Tofacitinib), [Prescribing Information]*. New York, NY; 2016.
 6. Hosking AM, Juhasz M, Mesinkovska NA. Topical Janus kinase inhibitors: A review of applications in dermatology. *J Am Acad Dermatol*. 2018;79:535-544. [PMID: 29673776].
 7. Vu M, Heyes C, Robertson SJ, Varigos GA, Ross G. Oral tofacitinib: a promising treatment in atopic dermatitis, alopecia areata and vitiligo. *Clin Exp Dermatol*. 2017;42:942-944. [PMID: 29034491].
 8. Rashighi M, Harris JE. Interfering with the IFN- γ /CXCL10 pathway to develop new targeted treatments for vitiligo. *Ann Transl Med*. 2015;3:343. [PMID: 26734651].
 9. Yang L, Wei Y, Sun Y, et al. Interferon-gamma inhibits melanogenesis and induces apoptosis in melanocytes: A pivotal role of CD8⁺ cytotoxic T lymphocytes in vitiligo. *Acta Derm Venereol*. 2015;95:664-670. [PMID: 25721262].
 10. Harris JE, Rashighi M, Nguyen N, et al. Rapid skin repigmentation on oral ruxolitinib in a patient with coexistent vitiligo and alopecia areata (AA). *J Am Acad Dermatol*. 2016;74:370-371. [PMID: 26685721].
 11. Rothstein B, Joshipura D, Saraiya A, et al. Treatment of vitiligo with the topical Janus kinase inhibitor ruxolitinib. *J Am Acad Dermatol*. 2017;76:1054-1060.e1. [PMID: 28390737].
 12. Shreberk-Hassidim R, Ramot Y, Zlotogorski A. Janus kinase inhibitors in dermatology: A systematic review. *J Am Acad Dermatol*. 2017;76:745-753.e19. [PMID: 28169015].
 13. Ghoreschi K, Jesson MI, Li X, et al. Modulation of Innate and Adaptive Immune Responses by Tofacitinib (CP-690,550). *J Immunol*. 2011;186:4234-4243. [PMID: 21383241].
 14. Hodge JA, Kawabata TT, Krishnaswami S, et al. The mechanism of action of tofacitinib - an oral Janus kinase inhibitor for the treatment of rheumatoid arthritis. *Clin Exp Rheumatol*. 2016;34:318-328. [PMID: 26966791].
 15. Di Lernia V, Bardazzi F. Profile of tofacitinib citrate and its potential in the treatment of moderate-to-severe chronic plaque psoriasis. *Drug Des Devel Ther*. 2016;10:533-539. [PMID: 26889081].
 16. Macdonald JB, Macdonald B, Golitz LE, LoRusso P, Sekulic A. Cutaneous adverse effects of targeted therapies: Part II: Inhibitors of intracellular molecular signaling pathways. *J Am Acad Dermatol*. 2015;72:221-236. [PMID: 25592339].
 17. Anforth R, Menzies A, Byth K, et al. Factors influencing the development of cutaneous squamous cell carcinoma in patients on BRAF inhibitor therapy. *J Am Acad Dermatol*. 2015;72:809-815. [PMID: 25748298].
 18. Dalle S, Poulalhon N, Debarbieux S, et al. Tracking of second primary melanomas in vemurafenib-treated patients. *JAMA Dermatology*. 2013;149:488-490. [PMID: 23715012].
 19. Dalle S, Poulalhon N, Debarbieux S, Thomas L. Second primary melanomas on treatment with vemurafenib. *Br J Dermatol*. 2013;168:887-888. [PMID: 23066856].
 20. Zimmer L, Hillen U, Livingstone E, et al. Atypical melanocytic proliferations and new primary melanomas in patients with advanced melanoma undergoing selective BRAF inhibition. *J Clin Oncol*. 2012;30:2375-2383. [PMID: 22614973].
 21. Debarbieux S, Dalle S, Depaepae L, Poulalhon N, Balme B, Thomas L. Second primary melanomas treated with BRAF blockers: Study by reflectance confocal microscopy. *Br J Dermatol*. 2013;168:1230-1235. [PMID: 23302038].
 22. Perier-Muzet M, Thomas L, Poulalhon N, et al. Melanoma patients under vemurafenib: prospective follow-up of melanocytic lesions by digital dermoscopy. *J Invest Dermatol*. 2014;134:1351-1358. [PMID: 24304815].
 23. Carrera C, Puig-Butillè JA, Tell-Marti G, et al. Multiple BRAF Wild-Type Melanomas During Dabrafenib Treatment for Metastatic BRAF-Mutant Melanoma. *JAMA Dermatology*. 2015;151:544-548. [PMID: 25651238].
 24. Hatzivassiliou G, Song K, Yen I, et al. RAF inhibitors prime wild-type RAF to activate the MAPK pathway and enhance growth. *Nature*. 2010;464:431-435. [PMID: 20130576].
 25. Sloot S, Fedorenko I V, Smalley KS, Gibney GT. Long-term effects of BRAF inhibitors in melanoma treatment: friend or foe? *Expert Opin Pharmacother*. 2014;15:589-592. [PMID: 24456413].
 26. Chaudhari S, Leon A, Levin E, Neuhaus I, Liao W. Case Report of Multiple Keratoacanthomas and Squamous Cell Carcinomas in a Patient Receiving Pembrolizumab. *J Drugs Dermatology*. 2017;16:513-515. [PMID: 28628690].
 27. Freitas-Martinez A, Kwong BY, Rieger KE, Coit DG, Colevas AD, Lacouture ME. Eruptive Keratoacanthomas Associated With Pembrolizumab Therapy. *JAMA Dermatology*. 2017;153:694-697. [PMID: 28467522].
 28. Degache E, Crochet J, Simon N, et al. Major response to pembrolizumab in two patients with locally advanced cutaneous squamous cell carcinoma. *J Eur Acad Dermatol Venereol*. 2018;32:e257-e258. [PMID: 28557105].
 29. Wartewig T, Kurgys Z, Keppler S, et al. PD-1 is a haploinsufficient suppressor of T cell lymphomagenesis. *Nature*. 2017;552:121-125. [PMID: 29143824].
 30. Hwang SJE, Carlos G, Wakade D, et al. Cutaneous adverse events (AEs) of anti-programmed cell death (PD)-1 therapy in patients with metastatic melanoma: A single-institution cohort. *J Am Acad Dermatol*. 2016;74:455-461. [PMID: 26793994].
 31. Hua C, Boussemart L, Mateus C, et al. Association of Vitiligo With Tumor Response in Patients With Metastatic Melanoma Treated With Pembrolizumab. *JAMA Dermatology*. 2016;152:45-51. [PMID: 26501224].
 32. Larsabal M, Marti A, Jacquemin C, et al. Vitiligo-like lesions occurring in patients receiving anti-programmed cell death-1 therapies are clinically and biologically distinct from vitiligo. *J Am Acad Dermatol*. 2017;76:863-870. [PMID: 28094061].
 33. Méry-Bossard L, Bagny K, Chaby G, et al. New-onset vitiligo and progression of pre-existing vitiligo during treatment with biological agents in chronic inflammatory diseases. *J Eur Acad Dermatol Venereol*. 2017;31:181-186. [PMID: 27291924].
 34. Alghamdi KM, Khurram H, Taieb A, Ezzedine K. Treatment of generalized vitiligo with anti-TNF- α Agents. *J Drugs Dermatology*. 2012;11:534-539. [PMID: 22453596].
 35. Webb KC, Tung R, Winterfield LS, et al. Tumour necrosis factor- α inhibition can stabilize disease in progressive vitiligo. *Br J Dermatol*. 2015;173:641-650. [PMID: 26149498].
 36. Jung JM, Lee YJ, Won CH, et al. Development of vitiligo during treatment with adalimumab: A plausible or paradoxical response? *Ann Dermatol*. 2015;27:620-621. [PMID: 26512182].
 37. Bae JM, Kim M, Lee HH, et al. Increased Risk of Vitiligo Following Anti-Tumor Necrosis Factor Therapy: A 10-Year Population-Based Cohort Study. *J Invest Dermatol*. 2018;138:768-774. [PMID: 29175284].
 38. Havmose M, Thomsen SF. Development of paradoxical inflammatory disorders during treatment of psoriasis with TNF inhibitors: a review of published cases. *Int J Dermatol*.

- 2017;56:1087-1102. [PMID: 28737221].
39. Joyau C, Veyrac G, Dixneuf V, Jolliet P. Anti-tumour necrosis factor alpha therapy and increased risk of de novo psoriasis: is it really a paradoxical side effect? *Clin Exp Rheumatol*. 2012;30:700-706. [PMID: 22935567].
40. Loh TY, Cohen PR. Infliximab-Associated Psoriasiform Dermatitis: Case Report and Review of a Seemingly Paradoxical Inflammatory Response. *Cureus*. 2016;8(9). [PMID: 27738572].
41. Udkoff J, Cohen PR. Tumor necrosis factor-induced alopecia: Alternative pathology and therapy. *Dermatol Online J*. 2017;23:4-6. [PMID: 28633753].
42. Udkoff J, Cohen PR. Severe Infliximab-Induced Alopecia and Scalp Psoriasis in a Woman with Crohn's Disease: Dramatic Improvement after Drug Discontinuation and Treatment with Adjuvant Systemic and Topical Therapies. *Dermatol Ther (Heidelb)*. 2016;6:689-695. [PMID: 27844446].
43. Toussirot E, Aubin F. Paradoxical reactions under TNF-alpha blocking agents and other biological agents given for chronic immune-mediated diseases: an analytical and comprehensive overview. *RMD Open*. 2016;2:e000239. [PMID: 27493788].
44. Bruzzese V, De Francesco V, Hassan C, et al. New onset or worsening of psoriasis following biologic therapy: A case series. *Int J Immunopathol Pharmacol*. 2017;30:70-72. [PMID: 28134599].
45. Faivre C, Villani AP, Aubin F, et al. Hidradenitis suppurativa (HS): An unrecognized paradoxical effect of biologic agents (BA) used in chronic inflammatory diseases. *J Am Acad Dermatol*. 2016;74:1153-1159. [PMID: 26965410].
46. Delobbeau M, Abdou A, Puzenat E, et al. Observational case series on adalimumab-induced paradoxical hidradenitis suppurativa. *J Dermatolog Treat*. 2016;27:251-253. [PMID: 26368546].