

Lichen planus of the eyelids: a case report and review of the literature

Yuan Yu Michael Huang MD¹, Connie M. Wang MD¹, Silvia Potenziani MD², Sylvia Hsu MD¹

Affiliations: ¹Department of Dermatology, Baylor College of Medicine, Houston, Texas, ²Department of Pathology and Immunology, Baylor College of Medicine, Houston, Texas

Corresponding Author: Yuan Yu Michael Huang, Baylor College of Medicine, 1977 Butler Boulevard, Ste. E6.200, Houston, TX, 77030. Tel. 512-913-1798 Fax. 713-798-3252, E-mail: ymhuang@bcm.edu

Abstract

Lichen planus (LP) of the eyelid is an under-reported manifestation of a common inflammatory condition. To the best of our knowledge fewer than 20 cases of eyelid LP have been described in the English literature. We report a case of a 29-year-old woman who presented with 3-month history of bilateral eyelid pruritic violaceous papules and similar lesions on her chest and lower extremity. Histology examination revealed characteristic findings and a diagnosis of LP was established. This report further reviews the previously reported 18 cases and discusses management strategies.

Keywords: lichen planus, eyelid

Introduction

Lichen planus (LP) is a common inflammatory condition of the skin and mucous membrane [1]. Although the underlying etiology remains poorly understood, LP is believed to result from autoimmune T-cell infiltration of the basement membrane and basal layer of the epidermis or epithelium [2]. Classically, LP presents as shiny, violaceous, flat-topped, pruritic polygonal papules or plaques with a superficial network of fine white lines (Wickham striae [1]). Lichen planus may appear anywhere on the body but favors the flexural aspect of wrists and ankles and the lumbar regions. Mucous membrane involvement is common in LP and features reticular white macules predominantly on the buccal mucosa, lips, and genitalia and follows a more chronic course [1].

Lichen planus rarely involves ocular structures and may present as eyelid lesions or cicatricial

conjunctivitis [1-3]. Patients with conjunctival involvement may also develop blepharitis, keratitis, symblepharon, corneal ulceration, and residual visual impairment [1,3-6]. Eyelid LP may appear as isolated lesions. Thus, clinical diagnosis may be difficult as papular erythematous eyelid dermatosis has a wide differential that includes contact dermatitis, psoriasis vulgaris, and lupus erythematosus [2,7-10]. More commonly, LP lesions also appear at characteristic locations allowing for an easier diagnostic process [2,7,11-16]. Herein we present a case of LP with non-isolated eyelid involvement and a review of previously described cases.

Case Synopsis

An otherwise healthy 29-year-old woman presented with a 3-month history of pruritic lesions on her bilateral eyelids (**Figure 1**). She also noticed similar pruritic bumps on her chest and left shin during the same time period. On examination, there were multiple 2-3 mm violaceous papules with surrounding erythema on bilateral eyelids. Additionally, hyperpigmented papules were noted on her chest and left shin. There was no mucosal involvement. Two months after her initial visit, she developed similar lesions on her right post-auricular skin.

A biopsy using a shave technique of the left upper eyelid showed acanthosis, hypergranulosis, overlying hyperkeratosis, a dense lichenoid inflammatory infiltrate with mild to moderate vacuolar interface dermatitis, and prominent melanophagocytosis in the superficial dermis, confirming the diagnosis of LP (**Figure 2**). Serology for hepatitis C virus was negative. She was prescribed tacrolimus 0.1% ointment twice daily for the eyelid lesions and triamcinolone ointment 0.1% twice daily for the remaining lesions. After three months, the lesions persisted on her eyelids, but she

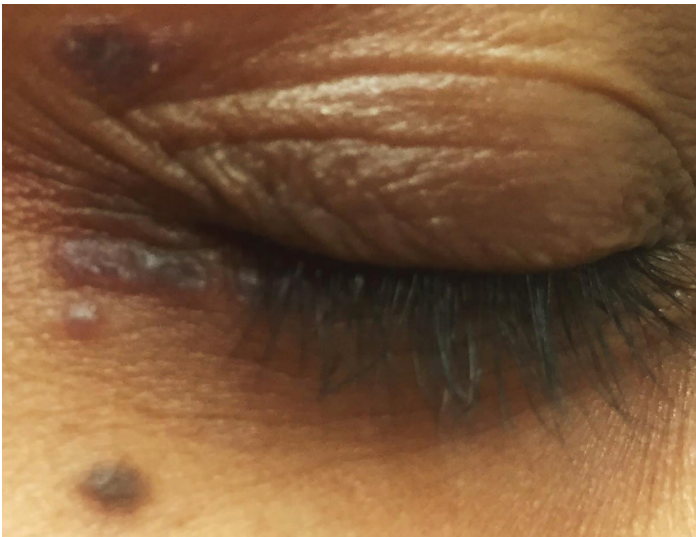

Figure 1. Polygonal violaceous papules of right upper and lower eyelids

experienced moderate symptomatic improvement. The lesions on her chest, post-auricular region, and shin resolved with therapy. After eight months, although she remained symptomatically stable, the violaceous papules on her eyelids persisted.

Case Discussion

The differential diagnosis of eyelid dermatosis is broad with allergic contact dermatitis being the most common cause [9]. Other common causes include atopic dermatitis, seborrheic dermatitis, and xerosis. Less commonly, discoid lupus, dermatomyositis, and psoriasis can affect the eyelid [9].

Lichen planus of the eyelids is an under-reported entity. Cases previously cited in the review by Itin et al. combined with a PubMed search using the terms "lichen planus," "LP," "and eyelid" yielded 18 cases (**Table 1**) [14]. This search does not include cases from other online non-indexed or non-English sources. Fifteen (78.9%) occurred in female patients and six (31.6%) cases presented with isolated eyelid lesions. In cases of isolated eyelid involvement, diagnosis may be difficult, and clinical suspicion should be confirmed by histology. Historically, eyelid LP has been classified into three types by Michelson et al.: (1) non-isolated, classically lilac-colored, slightly-delled papules with filigree scaling (2) non-isolated, annular papules or small medallion plaques, and (3) isolated eyelid lesions with general appearance of erythema ab igne [7]. Our case falls under the first classification.

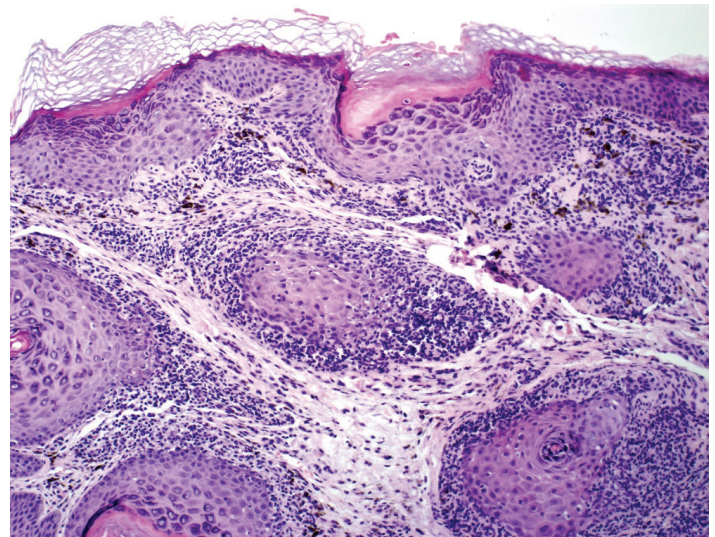


Figure 2. Left upper eyelid shave biopsy shows skin with mild acanthosis, hypergranulosis, ragged rete ridges and overlying hyperkeratosis. There is a dense lichenoid inflammatory infiltrate and prominent dermal melanophagocytosis. (hematoxylin and eosin, original magnification x100).

Management of LP consists of topical steroids to relieve active inflammation [16]. Other alternatives include topical tacrolimus, acitretin, cyclosporine, sulfasalazine, and phototherapy [15]. Of the 18 previously described cases of eyelid LP, 9 did not report treatment method. Six reported successful treatment with 6-8 weeks of topical steroids including triamcinolone 0.1% (4 cases), mometasone 0.1% (1 case), and hydrocortisone 0.2% (1 case) [2,11]. One case reported treatment failure with topical steroids, but the lesions subsequently resolved without additional management [4]. One case was lost to follow up [9]. Lastly, one was treated successfully with 6 months of oral etretinate [10]. The eyelid lesions of the presenting case were treated with topical tacrolimus given the risk of ocular complication from topical corticosteroid. Although her symptoms improved, the lesions persisted after months of therapy. In comparison, the lesions on the body treated with topical steroids responded more favorably. In such cases, the risks and benefits of using topical steroids around the eye should be weighed.

Other forms of ocular LP include cicatrizing conjunctivitis, blepharitis, keratitis, and symblepharon. These may lead to corneal ulceration or permanent visual impairment [4-6]. Thus, an increased awareness of this diagnosis is important for both dermatologists and ophthalmologists.

Table 1. Well-documented cases of eyelid lichen planus.

Authors (year)	Age	Sex	Isolated	Location
Luhr (1924) [12]	75	M	N	Eyelid, conjunctiva
Touraine (1937) [13]	32	F	N	Eyelids, left hand, later disseminated lesion
Michelson (1938) [7]	29	F	Y	Eyelid
	32	F	Y	Eyelid
	20	F	N	Eyelid, neck, shoulder
	18	F	N	Eyelid bilaterally, right thigh
	65	F	N	Eyelid, wrist, trunk, buccal mucosa
Winer (1946) [15]	40	F	N	Initially mouth, then lower eyelid
Finnerud (1947) [10]	45	F	Y	Eyelid bilaterally
Vogel (1992) [11]	24	M	N	Eyelid then penis
Itin (1995) [14]	47	M	N	Eyelid, trunk, arms, and oral mucosa
Sharma (2001) [2]	48	F	N	Eyelid, wrist, ankle, leg, forearms
	17	F	Y	Eyelid bilaterally
	20	M	N	Eyelid, lower legs
	28	F	N	Eyelid, ankles, wrist, lower legs, trunk
	42	F	N	Eyelid, wrist, ankle, forearm
	32	F	Y	Bilateral eyelid with erosion
Verma (2006) [9]	68	F	Y	Left lower eyelid
Current case (2016)	29	F	N	Eyelid, shin, chest, postauricular

Conclusion

Lichen planus of the eyelid is an under-reported entity that must be included in the differential diagnosis of eyelid dermatosis. We described a case of this rare presentation and summarized 18 previous cases in the literature. The majority of the described cases occurred in females and did not have isolated lesions. Topical steroids appears to be effective in treating LP of the eyelids, but more work needs to be done to elucidate the most appropriate therapy.

References

- Rozas Muñoz E, Martínez-Escala ME, Juanpere N, Armentia J, Pujol RM, Herrero-González JE. Isolated conjunctival lichen planus: a diagnostic challenge. *Arch Dermatol*. 2011 Apr;147(4):465-7. [PMID: 21482896]
- Sharma R, Singhal N. Lichen planus of the eyelids. A report of 5 cases. *Dermatol Online J*. 2001 Feb;7(1):5. [PMID: 11328626]
- Brewer JD, Ekdawi NS, Torgerson RR, Camilleri MJ, Bruce AJ, Rogers RS 3rd, Maguire LJ. Lichen planus and cicatricial conjunctivitis: disease course and response to therapy of 11 patients. *J Eur Acad Dermatol Venereol*. 2011 Jan;25(1):100-4. Review. [PMID:20477930]
- Rhee MK, Mootha VV. Bilateral keratoconjunctivitis associated with lichen planus. *Cornea*. 2004 Jan;23(1):100-5. Review. [PMID: 14701968]
- Pakravan M, Klesert TR, Akpek EK. Isolated lichen planus of the conjunctiva. *Br J Ophthalmol*. 2006 Oct;90(10):1325-6. [PMID: PMC1857434]
- Igras E, Kennedy S, MacDermott EJ, Murphy CC. Isolated ocular lichen planus in a child. *J AAPOS*. 2015 Aug;19(4):381-3. [PMID: 26212185]
- Michelson HE, Laymon C. Lichen planus of the eyelids. *Arch Dermatol*. 1938;37: 27-29.
- Ma'luf RN, El-Shareef MM, Hamade IH, Shabb NS, Kibbi AG. Bilateral lower eyelid margin erosion associated with lichen planus. *Ophthal Plast Reconstr Surg*. 2006 Jul-Aug;22(4):310-1. [PMID: 16855512]
- Verma SB. Lichen planus affecting eyelid alone: a rare entity. *Indian J Dermatol Venereol Leprol*. 2006 Sep-Oct;72(5):398. [PMID: 17050949]
- Finnerud CW. Lichen planus annularis (limited to eyelids). *Arch Derm Syphilol*. 1947 Jan;55(1):128. [PMID: 20283692]
- Vogel PS, James WD. Lichen planus of the eyelid: an unusual clinical presentation. *J Am Acad Dermatol*. 1992 Oct;27(4):638-9. [PMID: 1401326]
- Luhr AF: lichen plan of the conjunctiva. *Am J ophthalmol* 1924;7:456-457

13. Touraine A, Renault P: lichen planus circine des paupieres. Bull soc Dermol Syphiligr 1937; 44: 303-305.
14. Itin PH, Buechner SA, Ruffli T. Lichen planus of the eyelids. Dermatology. 1995;191(4):350-1. Review. [PMID: 8573943]
15. Winer, LH. Lichen planus of the mucous membrane and the eyelid. Arch Derm Syphilol. 1946 Nov;54:577. [PMID: 21001265]
16. Atzmony L, Reiter O, Hodak E, Gdalevich M, Mimouni D. Treatments for Cutaneous Lichen Planus: A Systematic Review and Meta-Analysis. Am J Clin Dermatol. 2016 Feb;17(1):11-22. [PMID: 26507510]